



In The Name of GOD

Reading the Brain CT

Dr. Aidin Shakeri

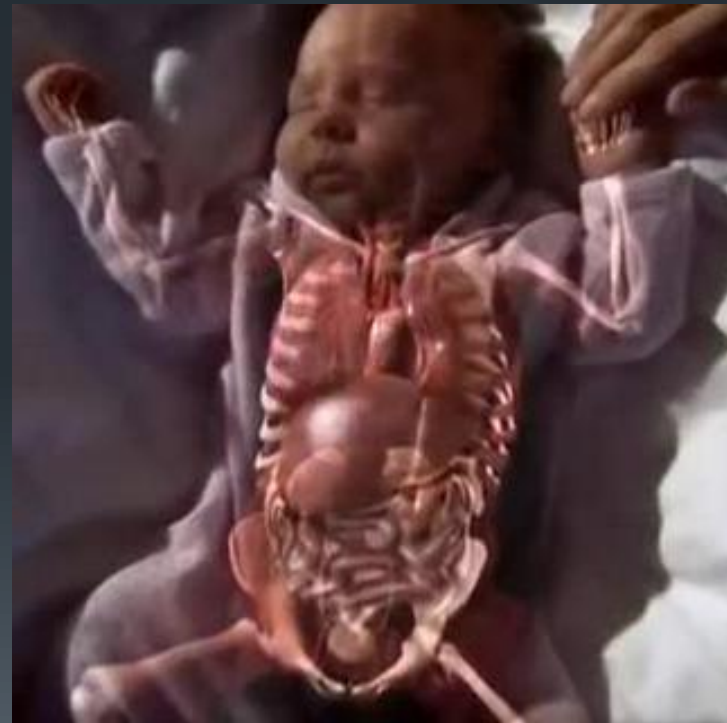Assistant proff.

Neurosurgery Department

AUMS



Intruduction

Inside of the body

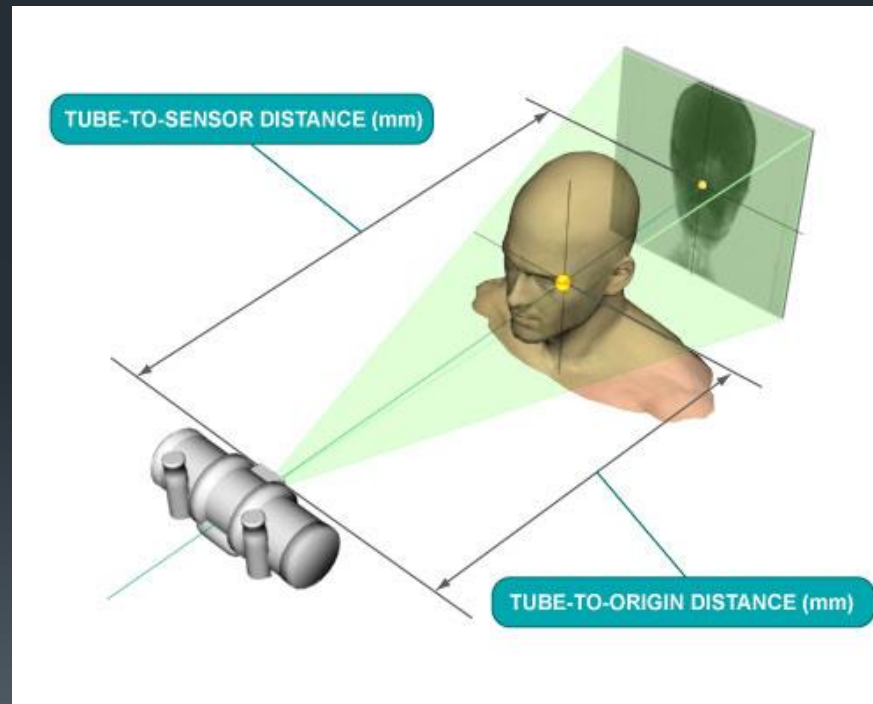


Intruduction

- X_Ray And Radiograhly



Radiography




Intruduction CT Scan, History



1972, Sir Geoffrey Hounsfield and Coworkers

Gradually Advancements in Availability, Speed,
Physiologic Assesments, Reconstruction, Safety



Intruduction

CT Scan in neurologic Field

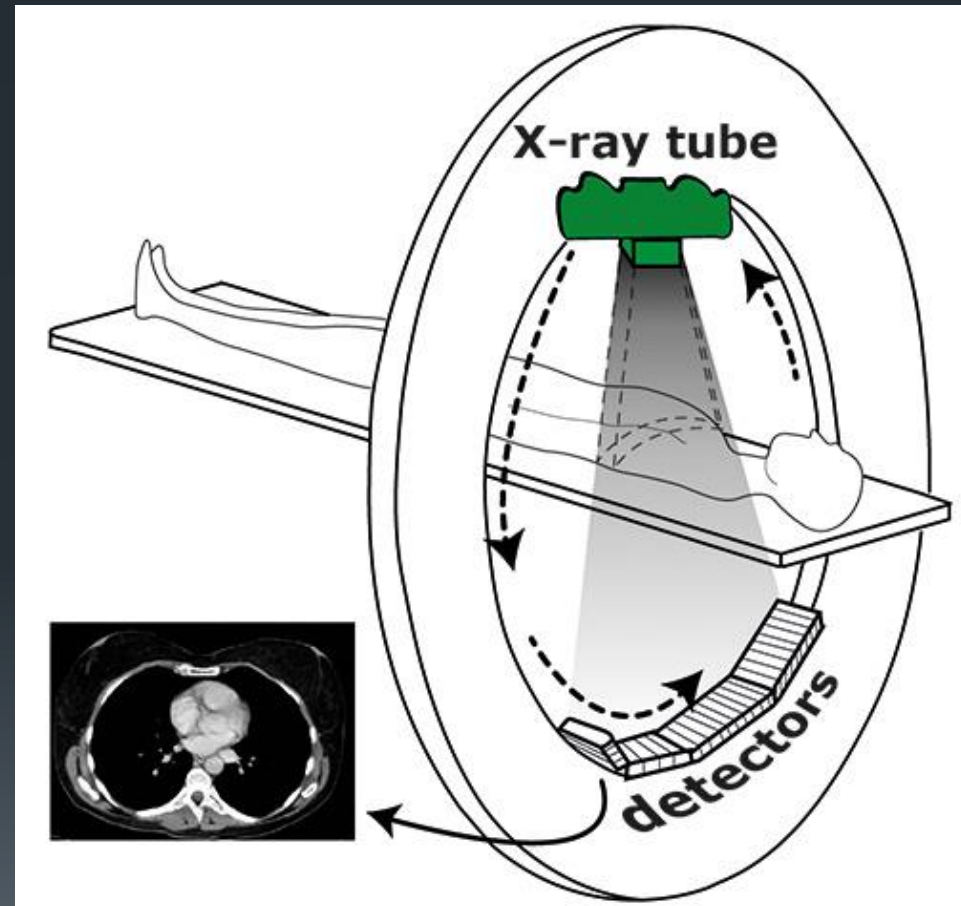


First Screening tool for Diagnosis of Intracranial pathologies
After :

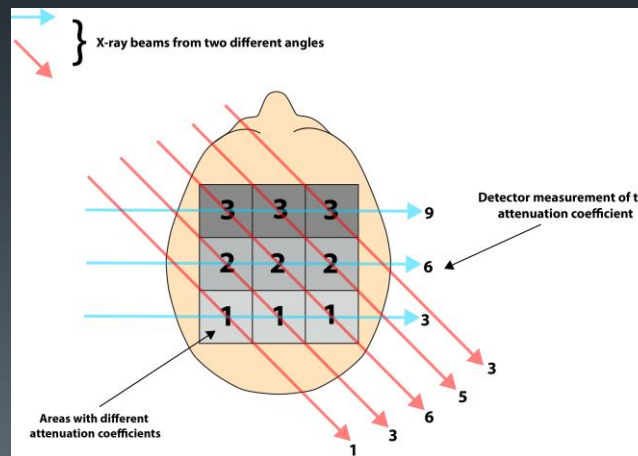
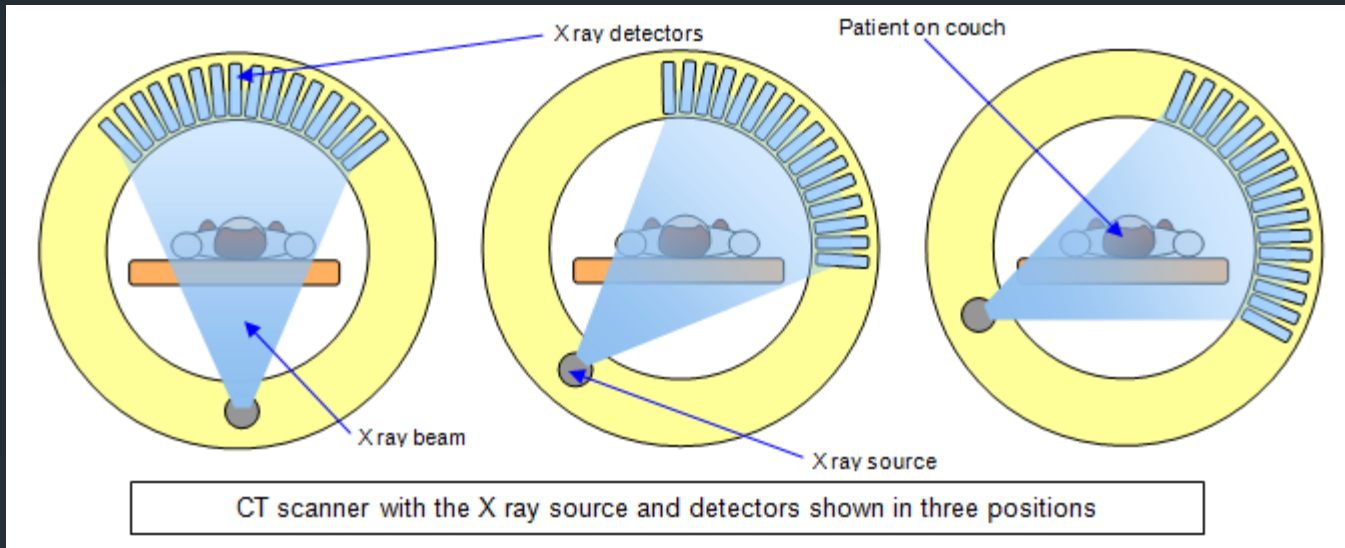
- Acute loss of consiusosness (seizure ,...)
- any acute neurologic deficite Specially in emergency **situations(weakness, ...)**
- Severe and new onset headach
- Craniofacial Trauma
- Follow up Assesments
- Post operation Assesments
- Contraindacation of MRI

Intruduction Technique

- Source
- Detector
- Computer(to voxel)
- Tomography



Intruduction Technique



Intruduction Technique, Hounsfield Unit



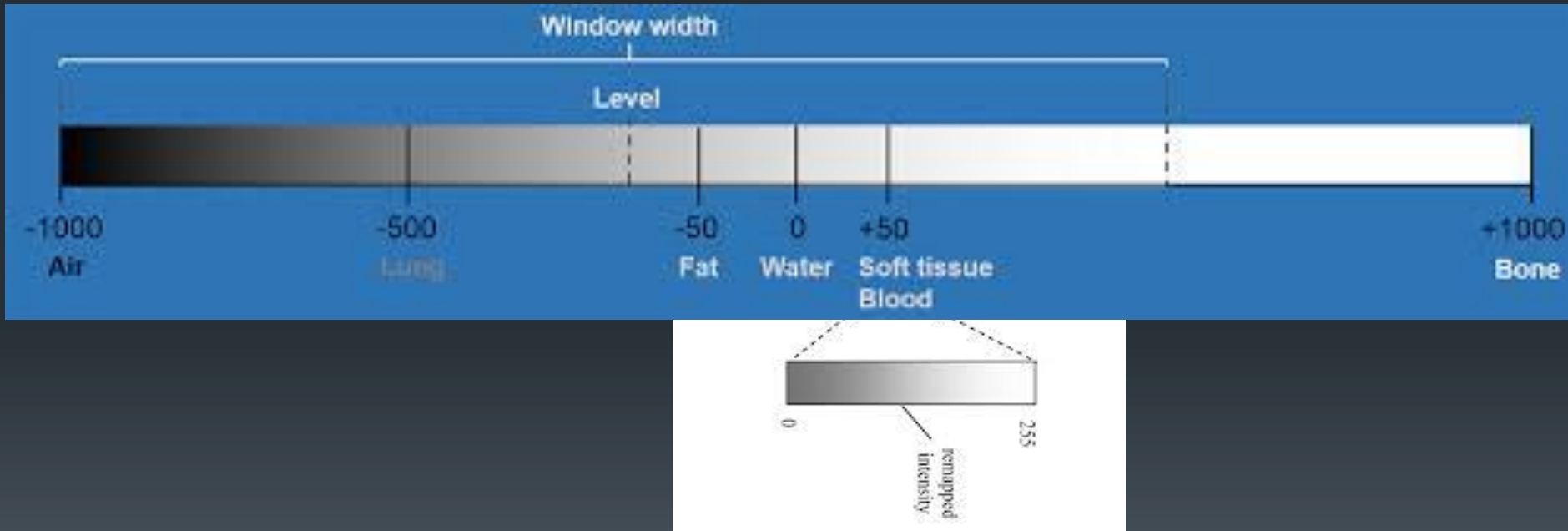
Attenuation coefficiant

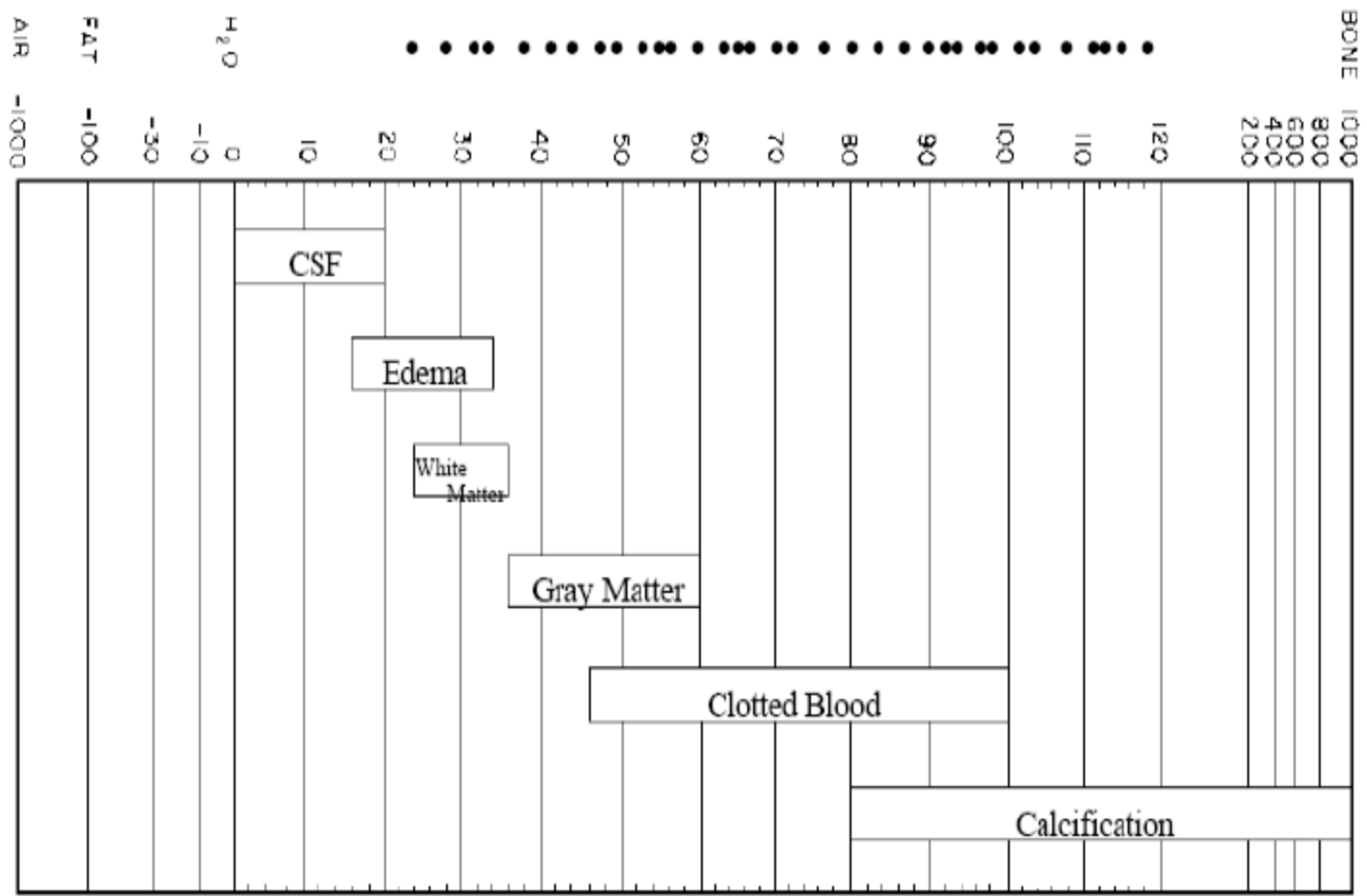
air	--- 1000
fat	---70
Pure water	0
Csf	+8
White matter	+30
Gray matter	+45
blood	+70
Bone/calcification	+1000

Intruduction Technique, Hounsfield



CT Windowing





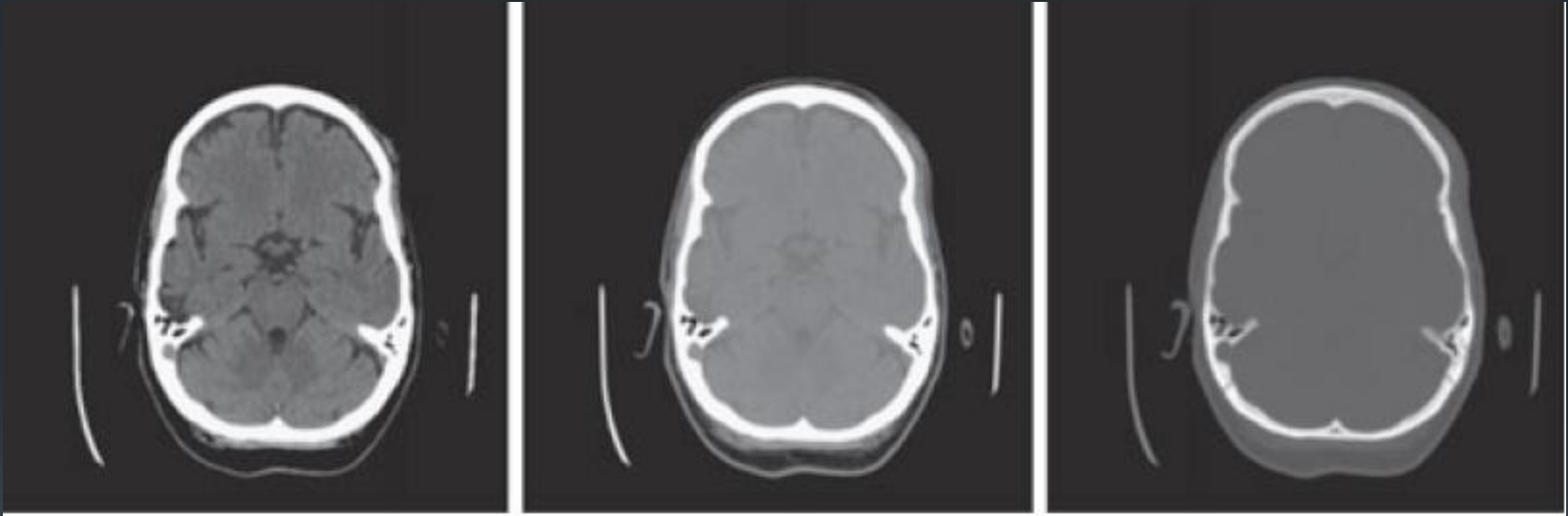
← Brain Window - level 35, width 70



← Subdural Window - level 35, width 200

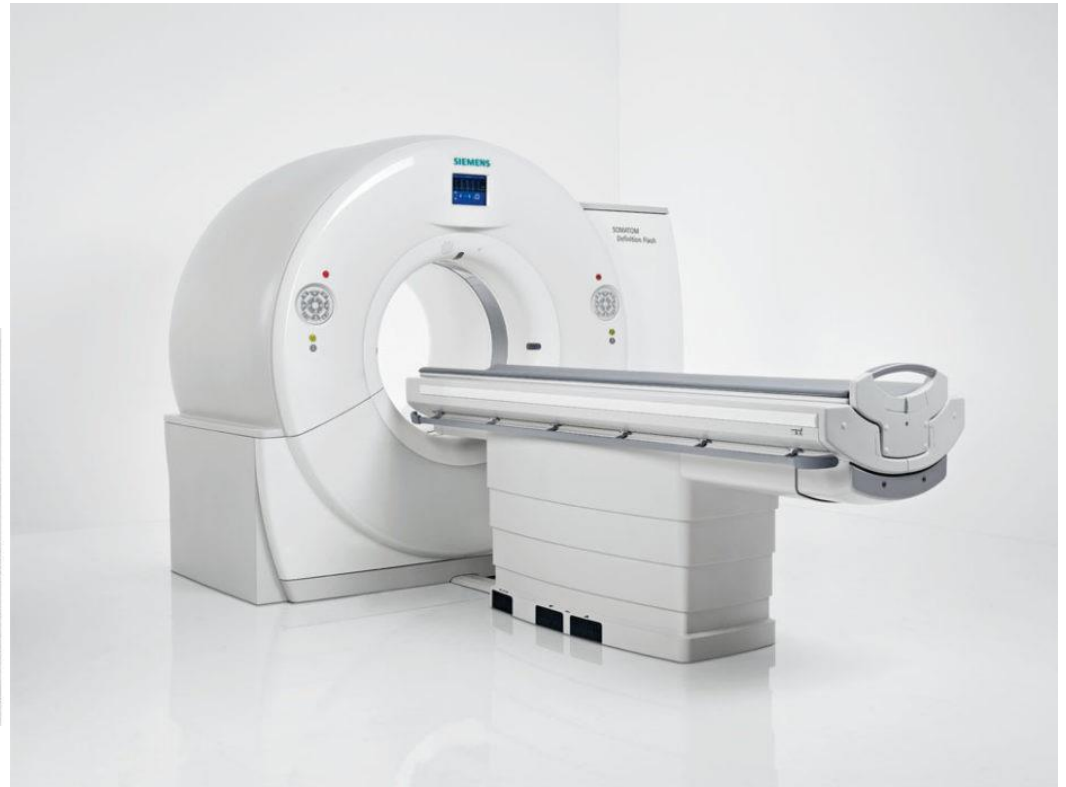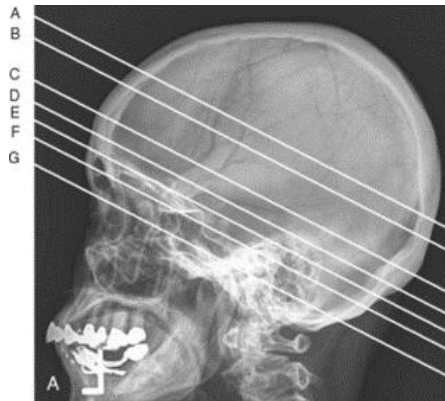
Bone Window - level 1000, width 1000 →





Intruduction Technique

- Patient Position
- Head position
- Interval
- Slice Thickness
- Orbitomeatal



Intruduction

CT Scan , Advantages



1. CT scanning is **painless, noninvasive** and **accurate**.

2. Unlike conventional x-rays, CT scanning provides very **detailed images** of many types of tissue as well as the lungs, bones, and blood vessels **at the same time**.

3. CT examinations are **fast** and **simple**; in emergency cases, they can reveal internal injuries and bleeding quickly enough to help save lives. unlike MRI. useful for children and the elderly

4. CT has been shown to be a cost-effective imaging tool for a **wide range of clinical problems**.

Intruduction

CT Scan , Advantages



5. CT may be **less expensive** than MRI. In addition, it is **less sensitive to patient movement**.

6. CT can be performed if you have an **implanted medical device** of any kind, unlike MRI.

7-CT imaging provides **real-time** imaging.

8-Neuronavigation

9-Ct Guided Biopsy

Intruduction

CT Scan , Disadvantages

1. There is always a slight **chance of cancer** from radiation. However, the benefit of an accurate diagnosis far outweighs the risk.
2. The **effective radiation dose** from this procedure is about 0.6-10 mSv, which is about the same as the average person receives from background radiation in eight months until 3 years.
3. Women should always inform their physician or x-ray technologist if there is any possibility that they are **pregnant**.
4. CT scanning is, in general, not recommended for **pregnant women** because of potential risk to the baby.

Intruduction

CT Scan , Disadvantages

5. **Nursing mothers** should wait for 24 hours after contrast material injection before resuming breast-feeding.
6. The risk of serious **allergic reaction** to contrast materials that contain iodine is rare, and radiology departments are well-equipped to deal with them.
7. Children should have a **CT study** only if it is essential for making a diagnosis and should not have repeated CT studies unless absolutely necessary.
8. Weakly Identify Posterior fossa pathologies

Intruduction

CT Scan Types

- Axial Brain CT Scan Without Contrast



Intruduction

CT Scan Types

- Axial Brain CT Scan With Contrast

- 100 cc-200 cc iodinated Contrast material
- Catheter 18-20 G
- Iv contrast is given to better evaluate:

 - Vascular structures

 - Tumors

 - Sites of infection

- Relative contraindications:

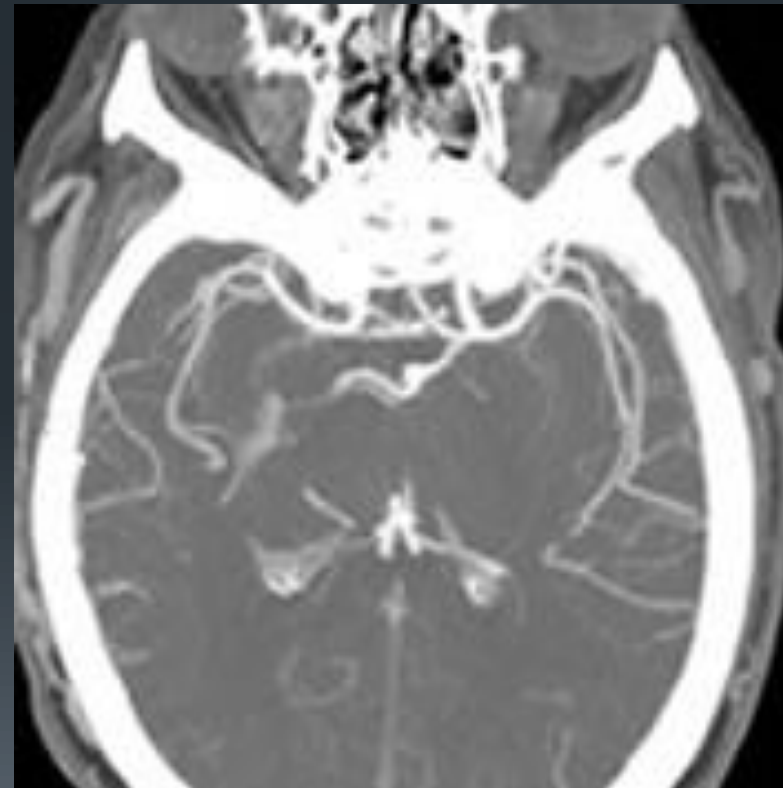
 - Allergy, renal failure

Intruduction

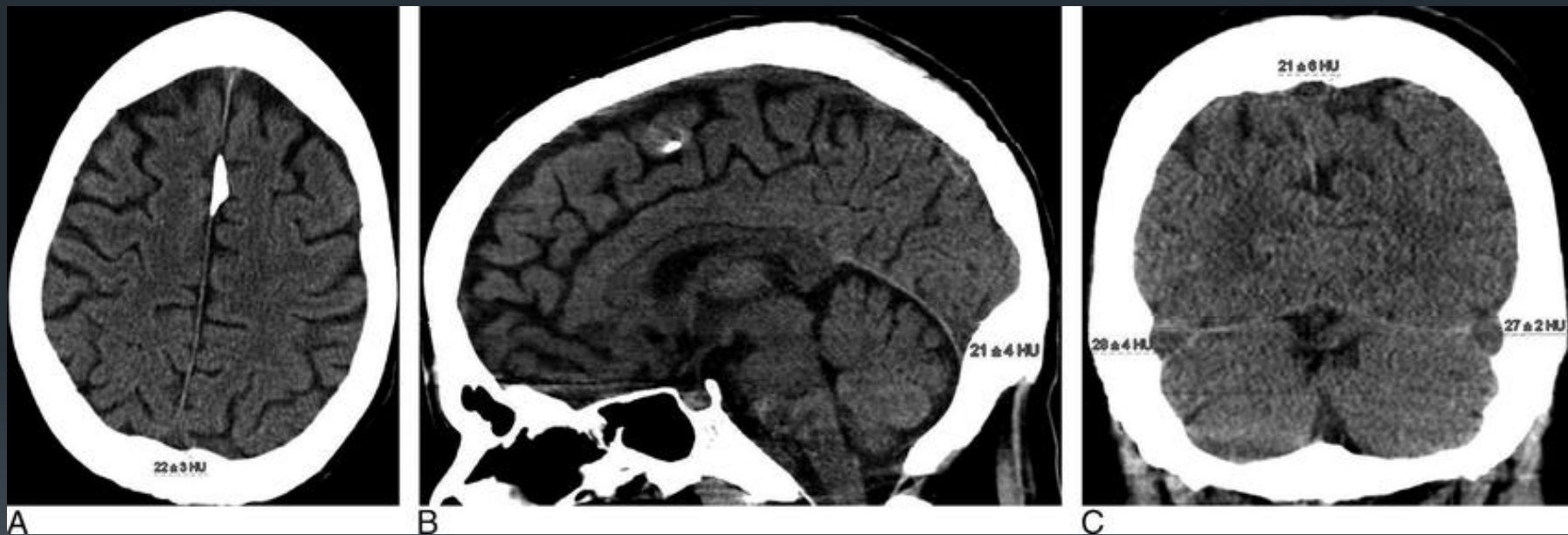CT Scan Types



- Brain CT Angiography
- Submillimeter slice, reconstructionable
- Relatively noninvasive Imaging of Great Head and Neck vasculature
- Intravenous inj.
- Alternative for Conventional Angiography (complication)
- Diagnose of vascular malformation
- Preoperation Planing(Hypervascular tumor or vascular encasement)



Reconstruction



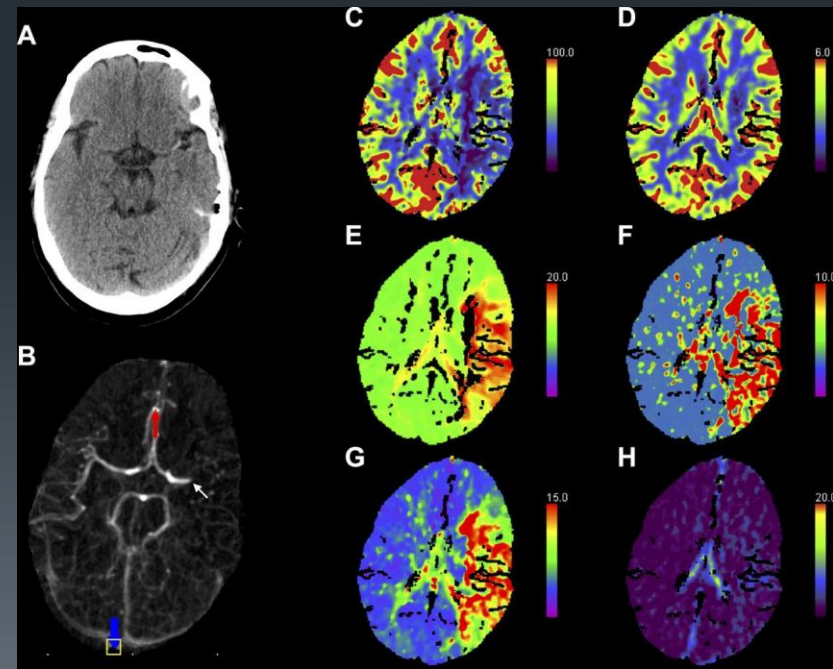


Contrast

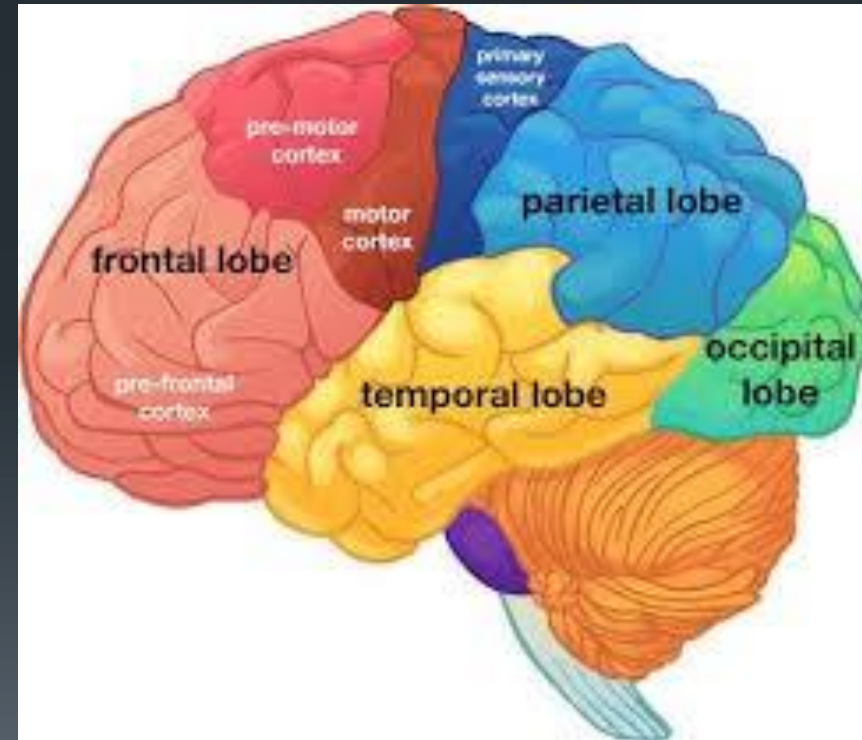
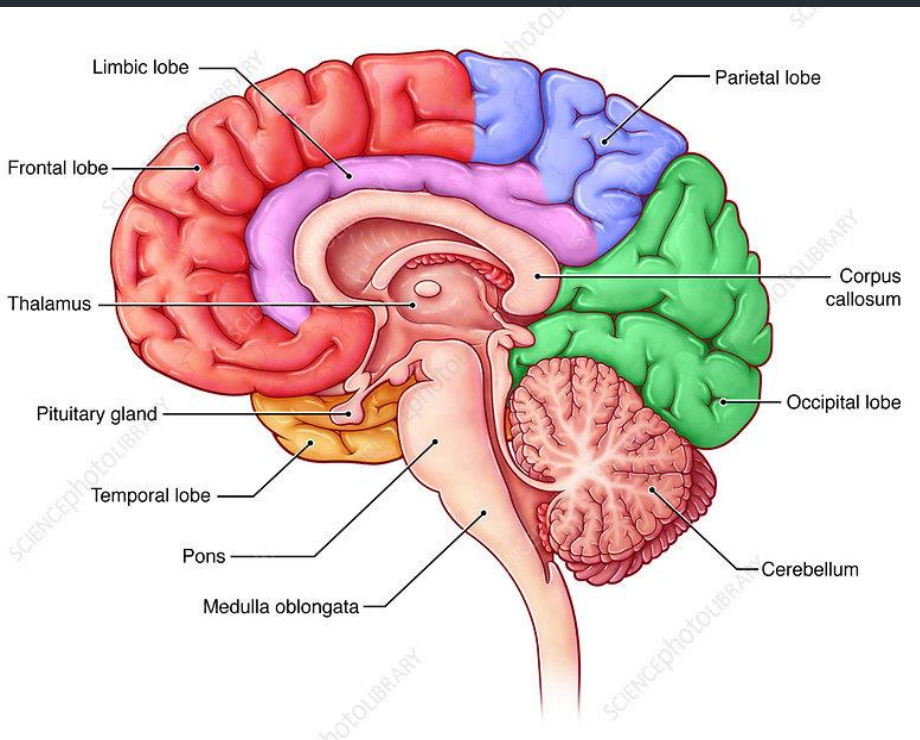
- Specification,
- Metrizamide
- Iohexal(omnipaque)
- Iodixanol(visipaque)
- Iopromide(Ultravist)

Brain Perfusion CT Scan

- Physiologic Data
- Contrast inj
- Imaging during a minute
- **“Time- Density” Curve for each Voxel**
- CBF(ml/min/100gr)
- MTT(min)
- CBV(cc/100gr)
- Use in Acute Cerebral Stroke

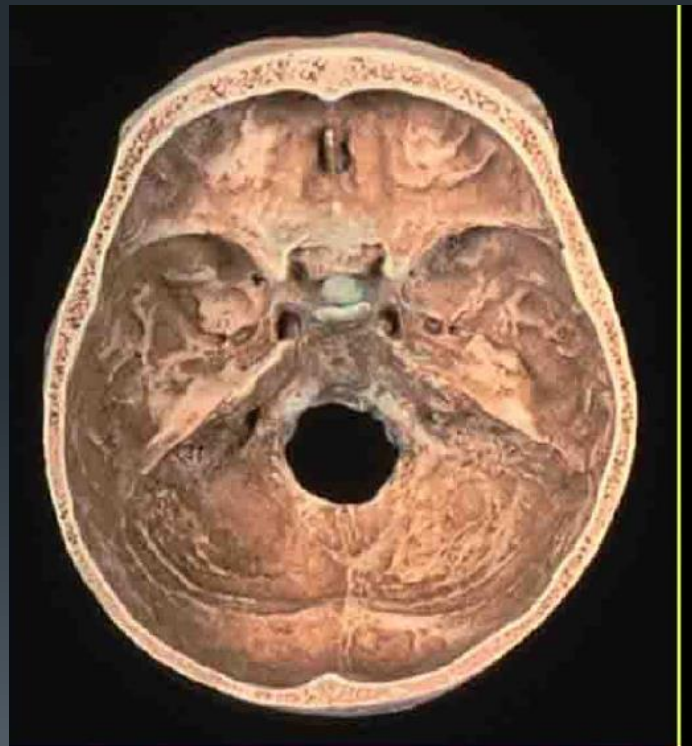

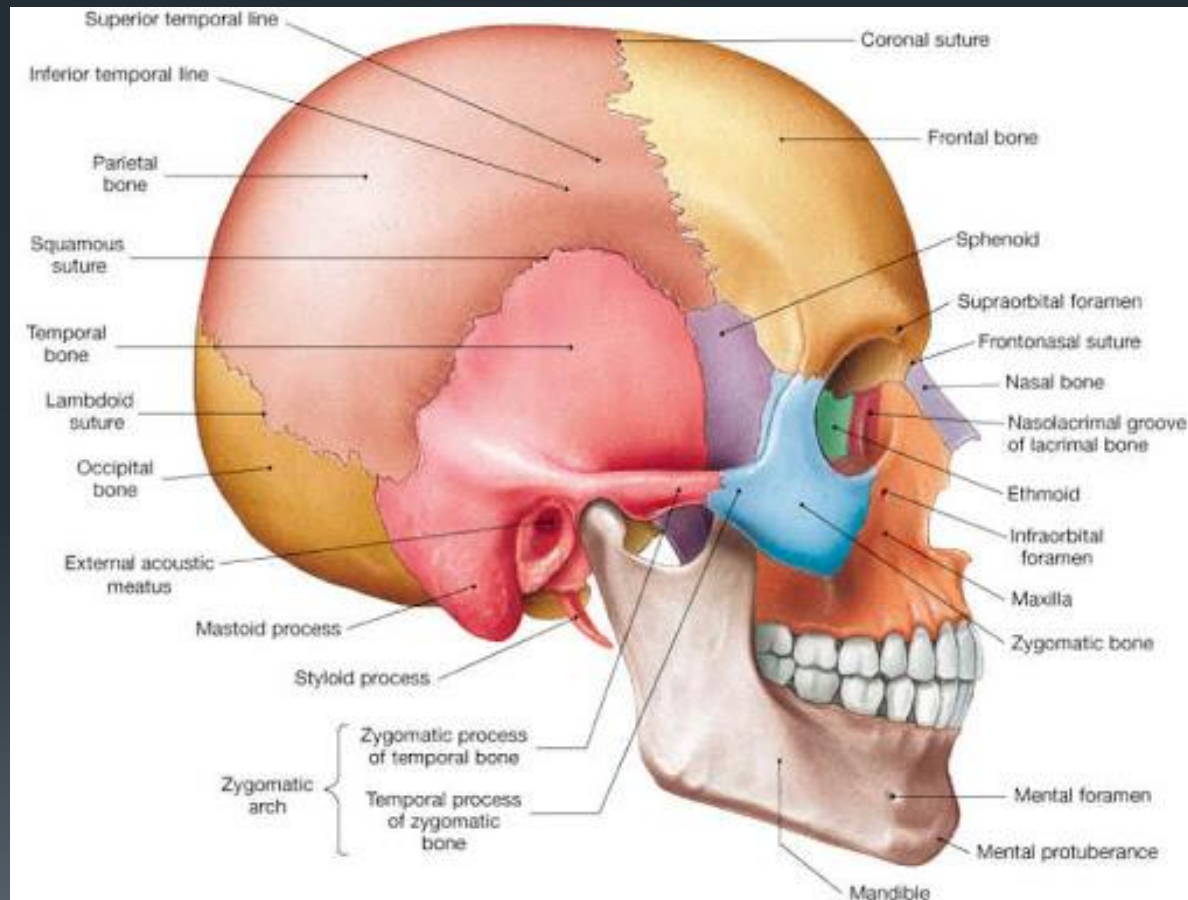
Anatomy Brain Lobes



Anatomy

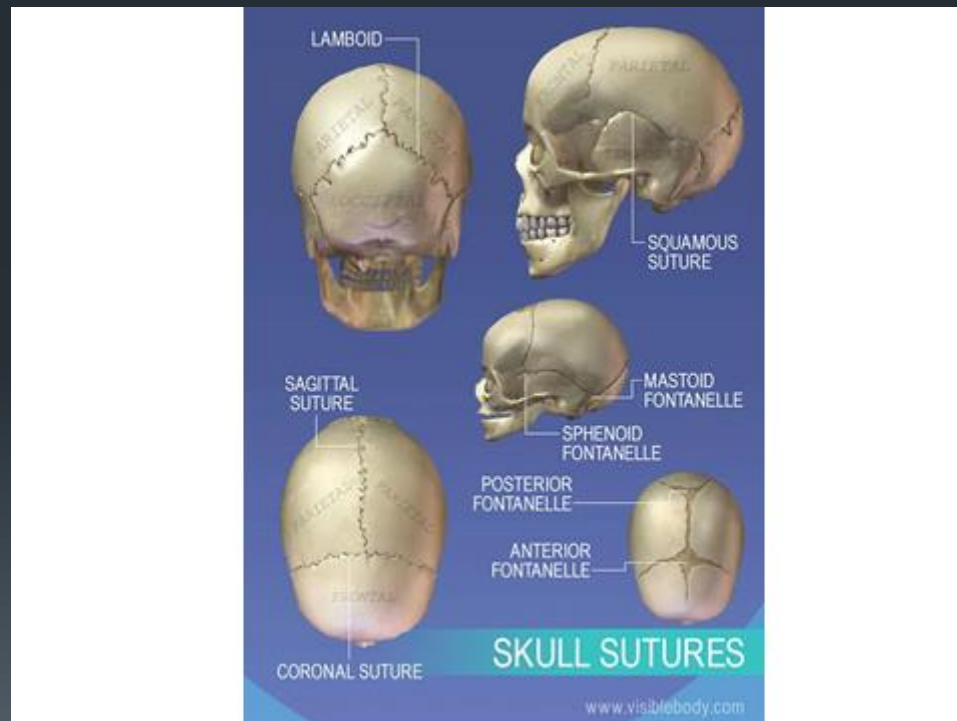
Skull Base , Cranial Fossa



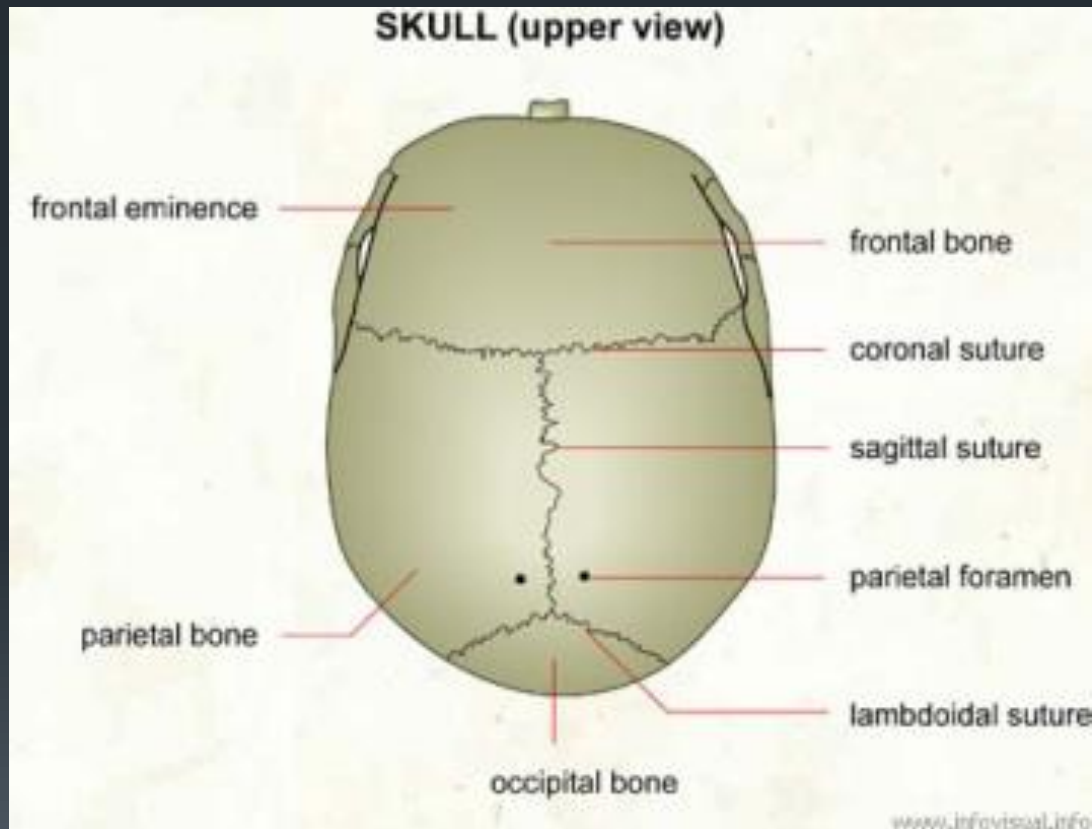


Anatomy

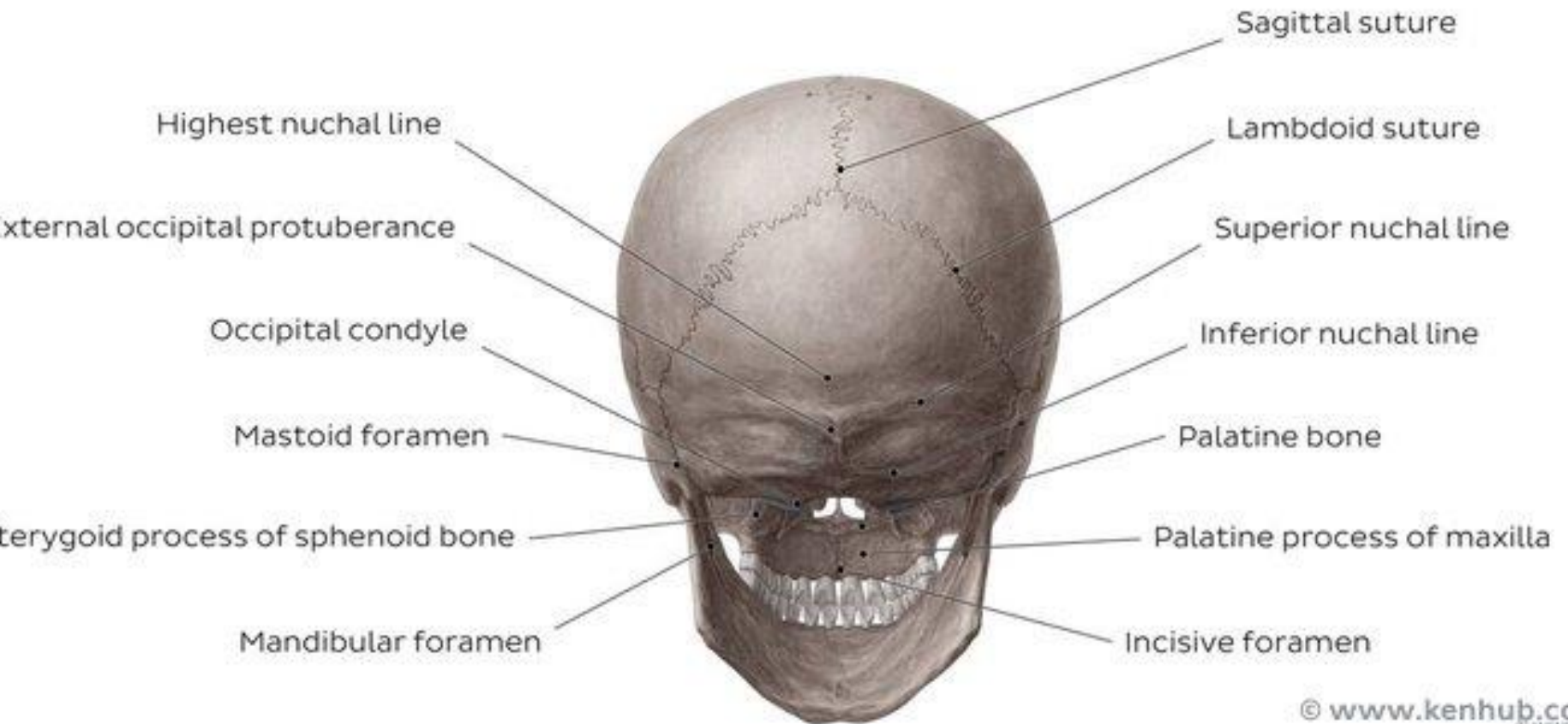
Skull , Sutures



Anatomy Skull , Sutures



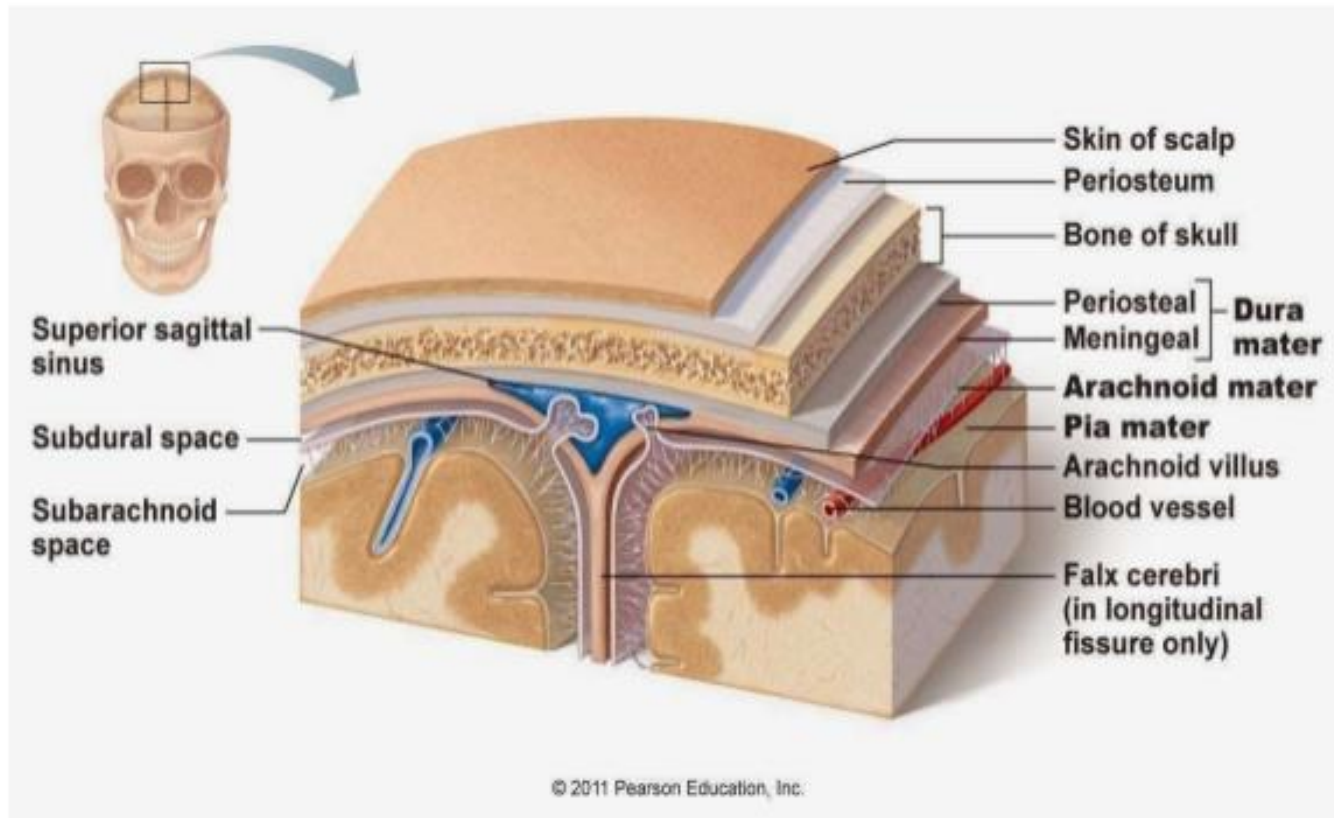
Anatomy Skull , Sutures



Anatomy

Cranium Coronal Section

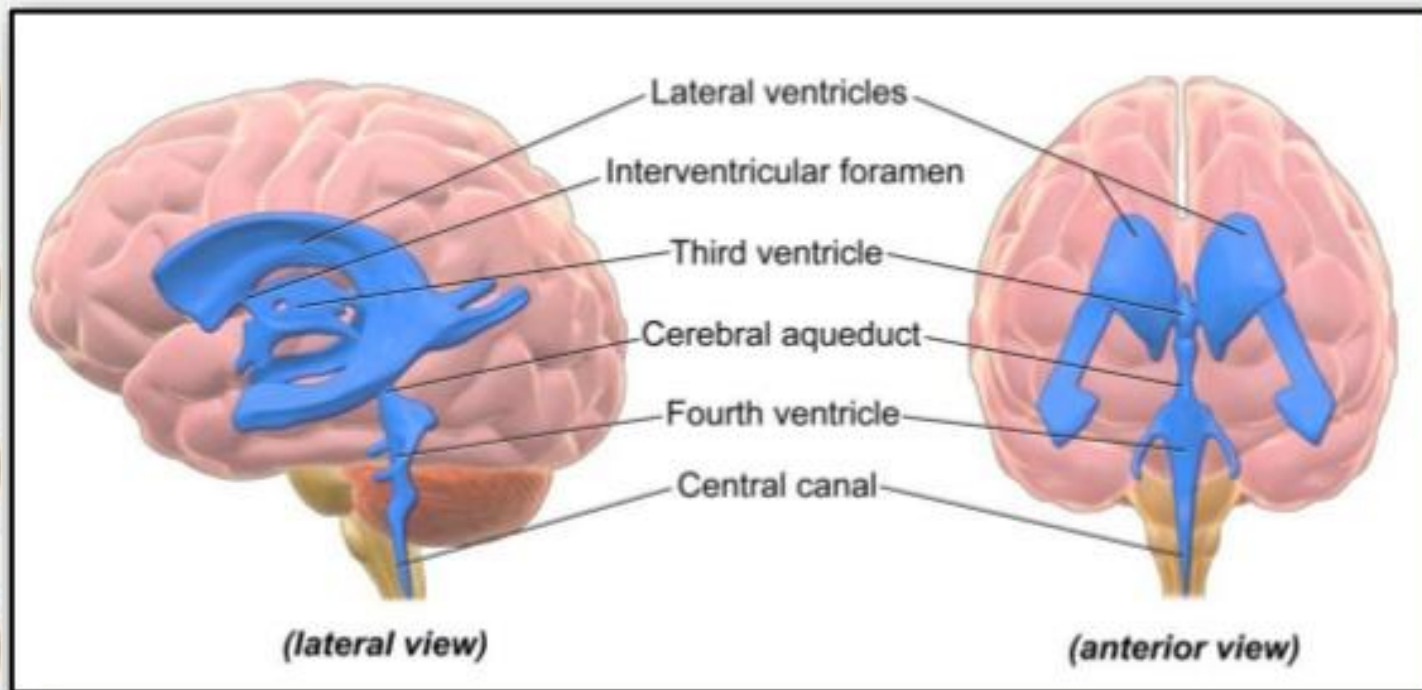
CROSS-SECTION



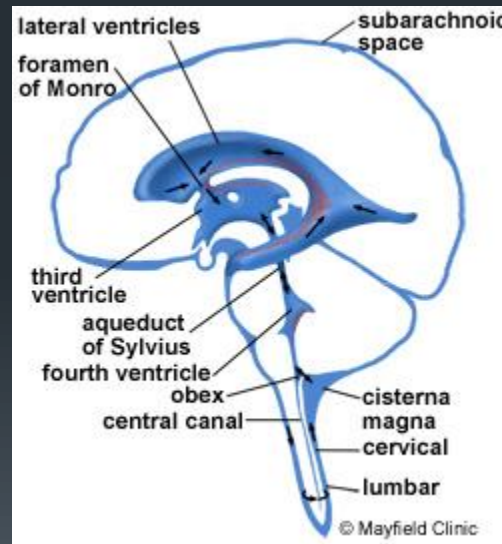
Anatomy Ventricles

© Dr. Sonali Parodhi, Mhatre

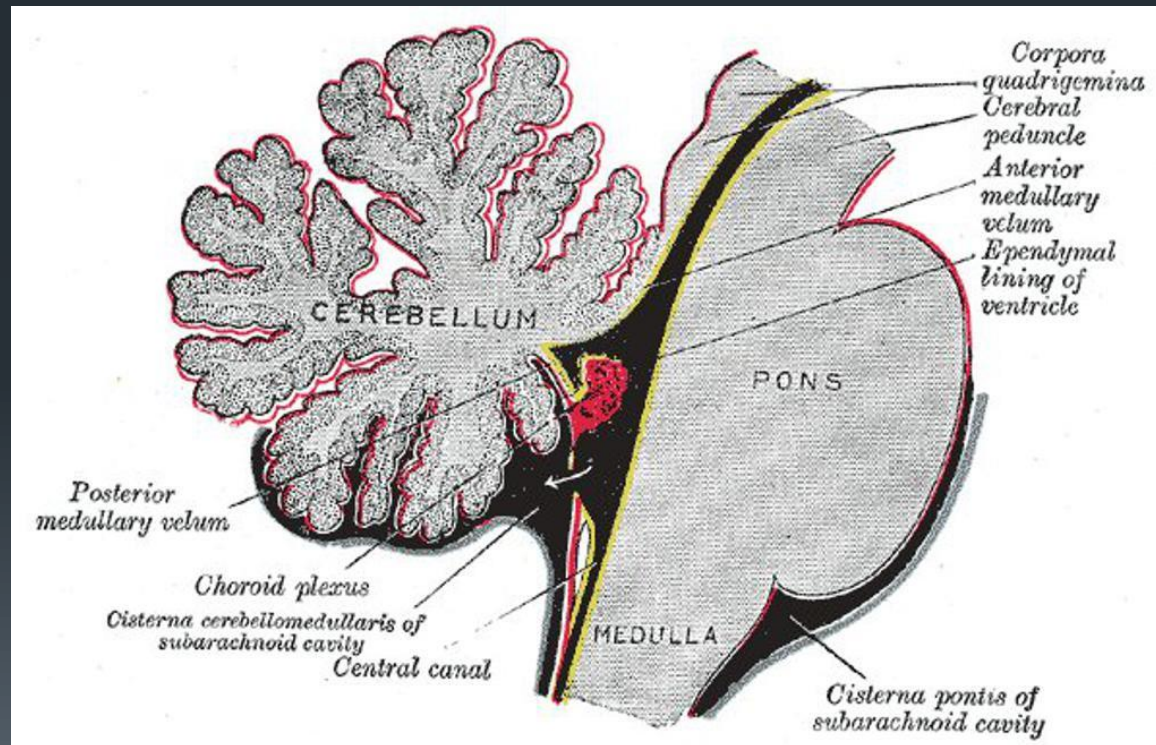
BASIC ANATOMY OF VENTRICULAR SYSTEM



Anatomy Ventricles

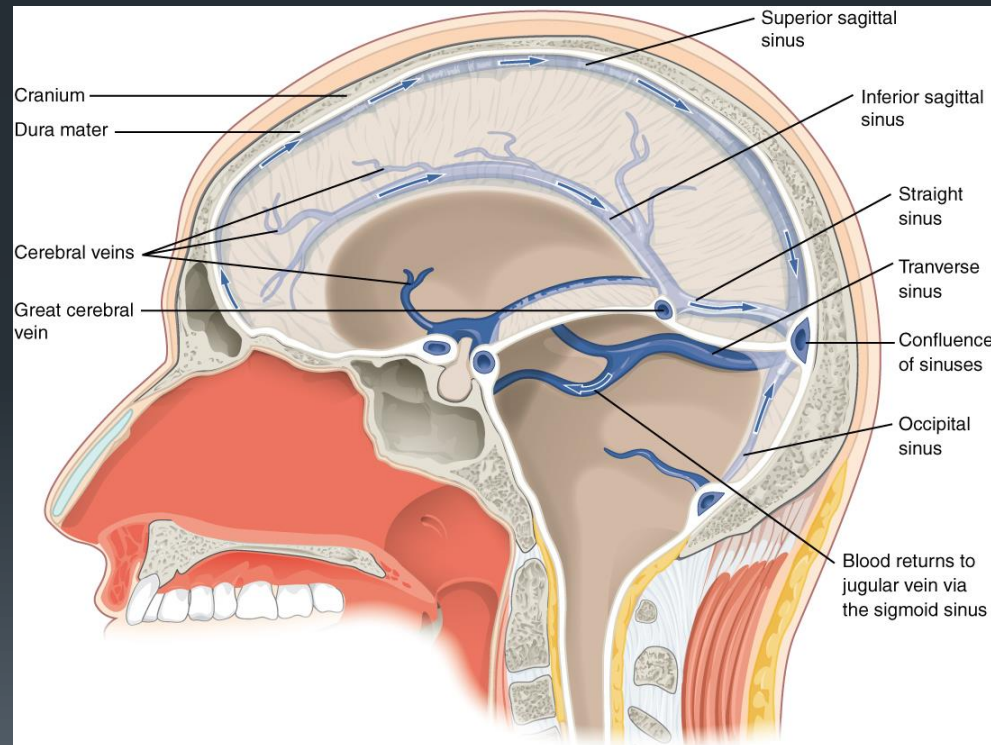


Anatomy Ventricles



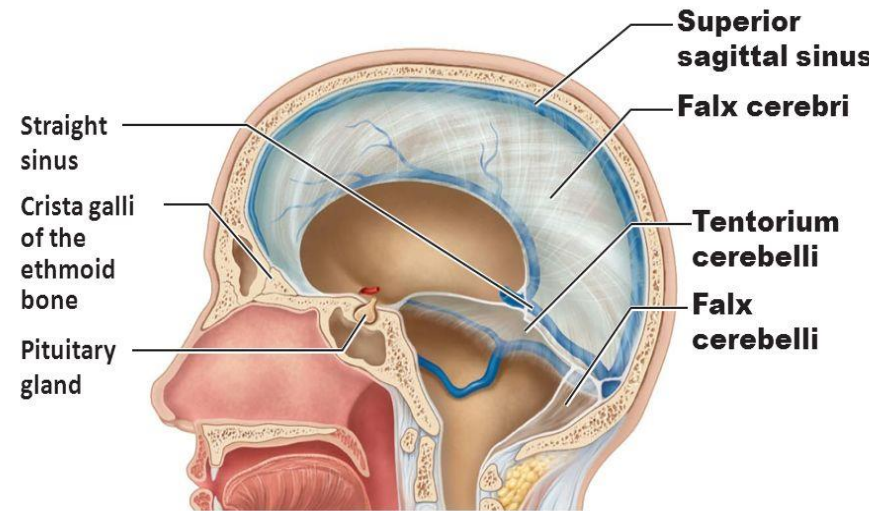
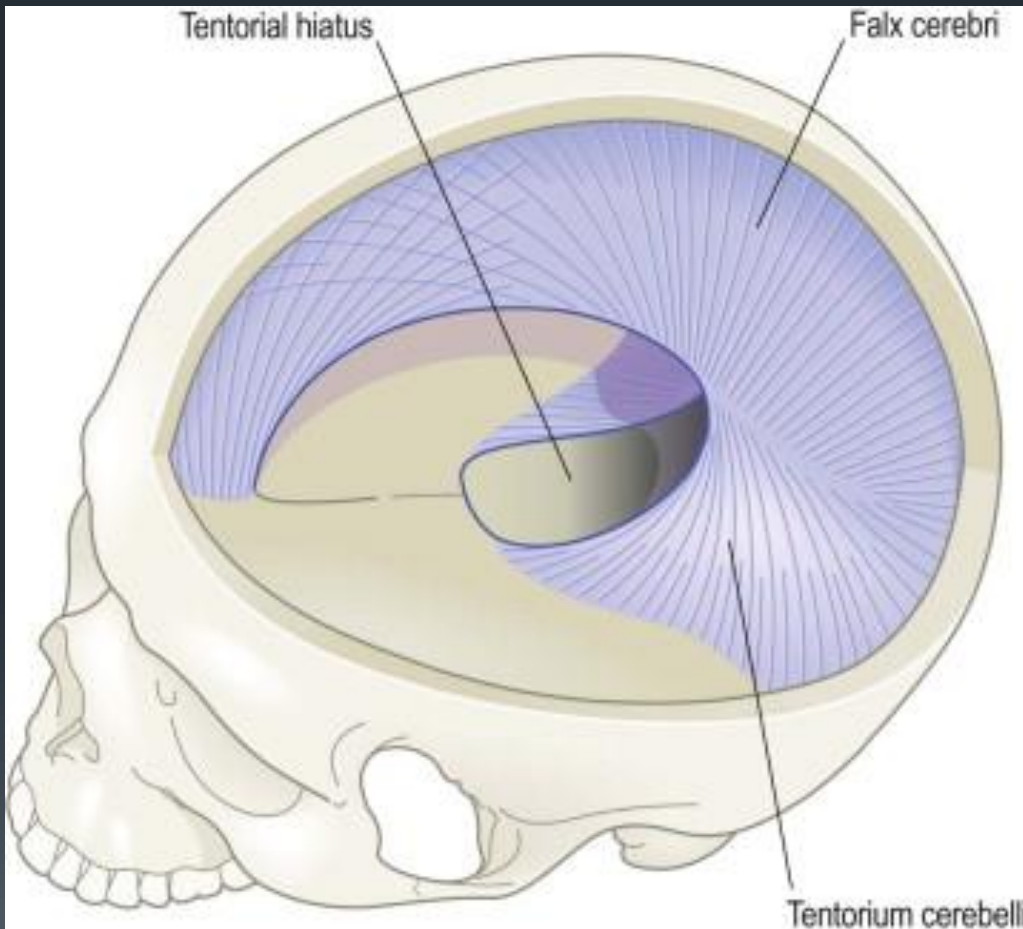
Anatomy

Veins And Venous Sinuses



Anatomy

Falx and Tentorium



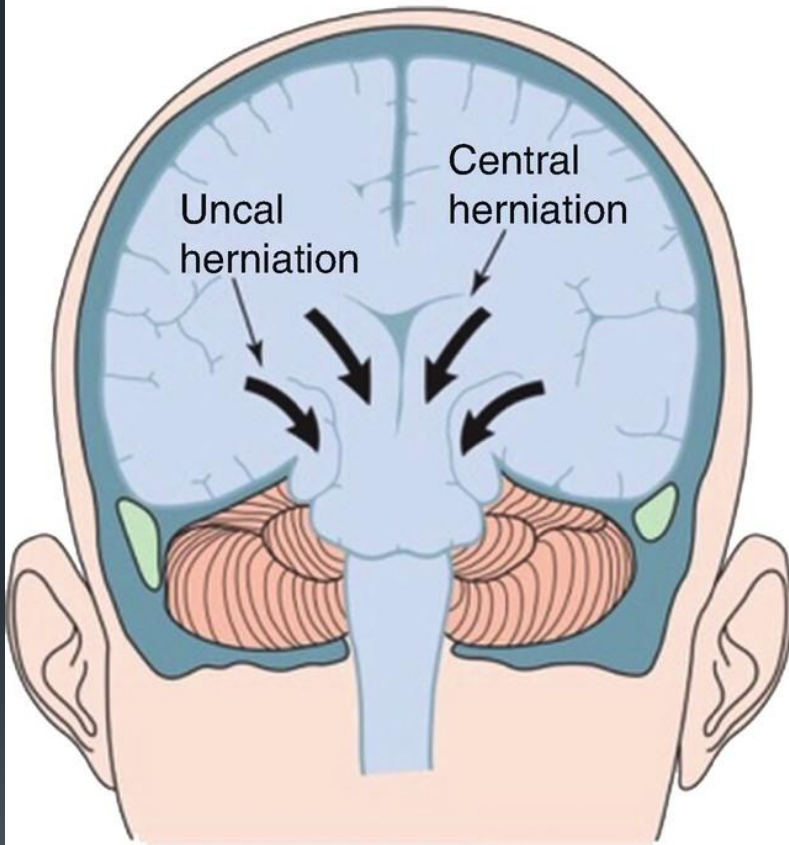
Anatomy

Cisterns

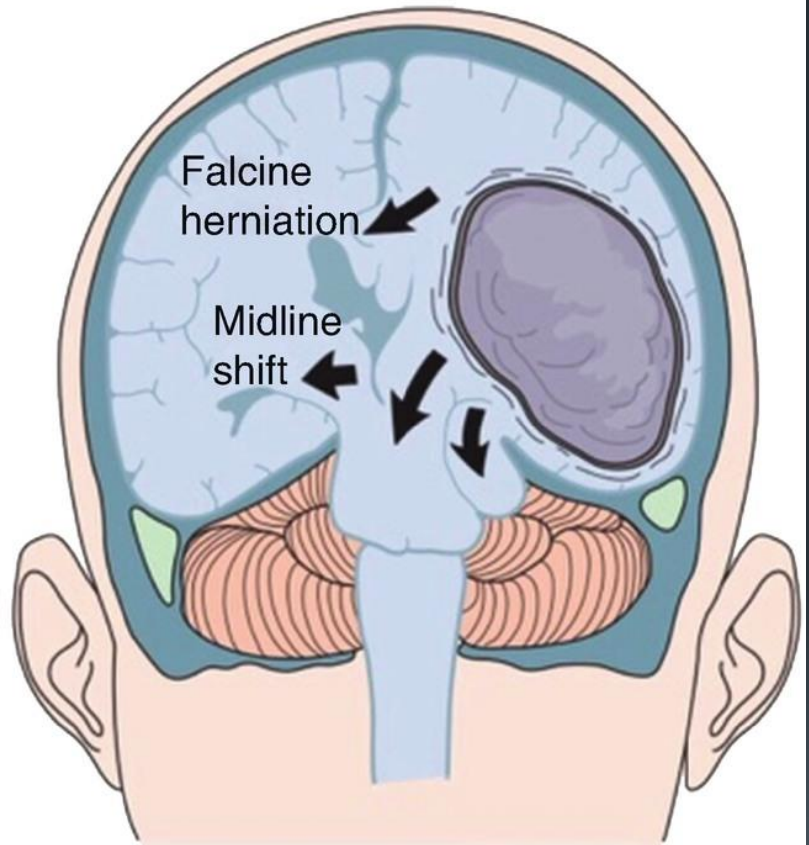
- CircumMesencephalic Cistern
around midbrain, effaced first with ICP raising
and herniation Syndromes
- Suprasellar Cistern
Star-shape above sella, contains circle of willis
- Quadrigeminal Cistern
W- shape at top of midbrain, effaced with Central
herniation
- Sylvian Cistern
Between Frontal and Temporal Lobes




a



b

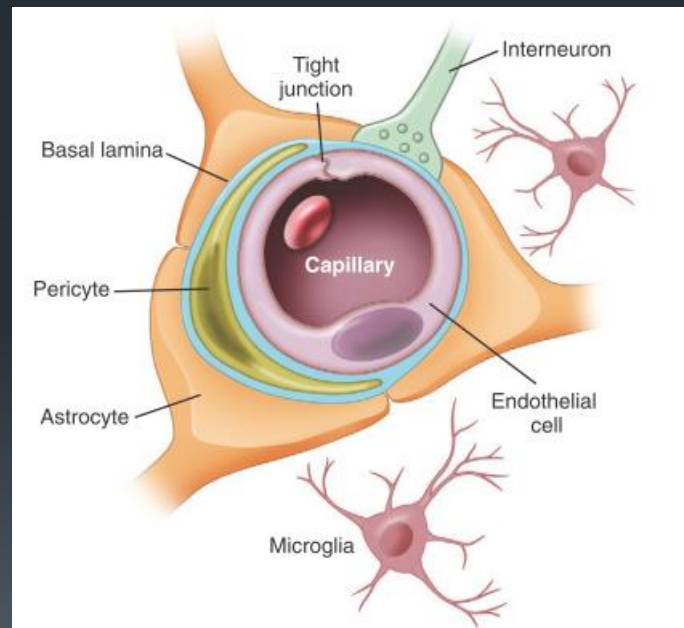


Anatomy Blood Brain Barrier



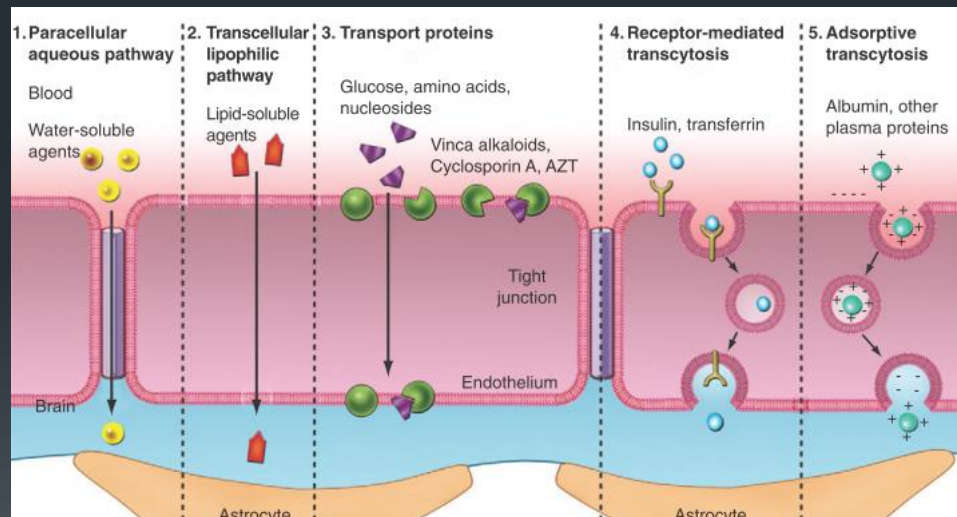
Anatomy

Blood Brain Barrier



Anatomy

Blood Brain Barrier



Anatomy

Blood Brain Barrier



Anatomy

Blood Brain Barrier

- Types Of Edema
 - Vasogenic
 - Cytotoxic



- Now.....



Brain CT Scan Reading



Brain CT Scan Reading

- Normal CT
- Center to Out
- Problem Oriented
- **Pneumonic “Blood Can Be Very Bad”**

“Blood, Cistern , Brain , Ventricle , Bone”



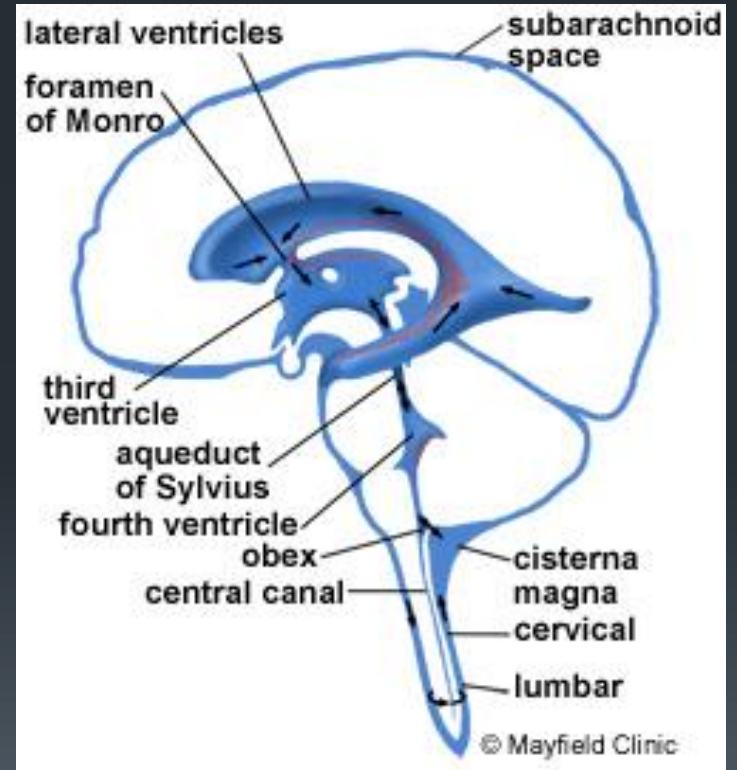
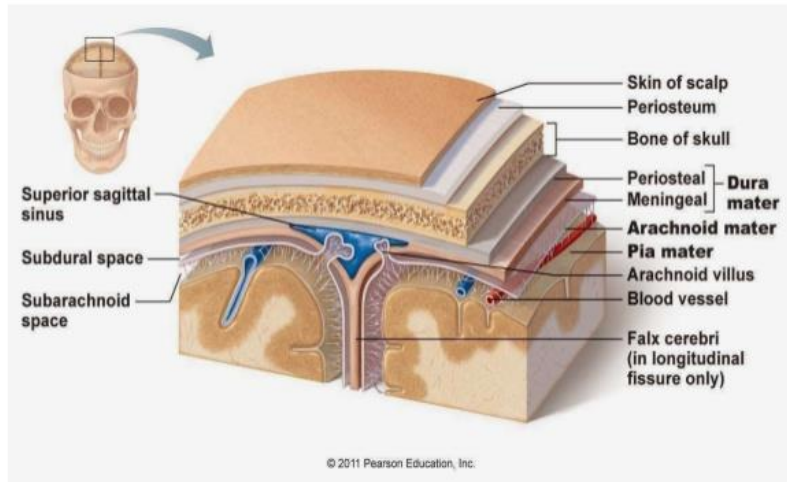
- 25cc
- 5mm MLS
- Cushing triad
- Head elevation



Blood

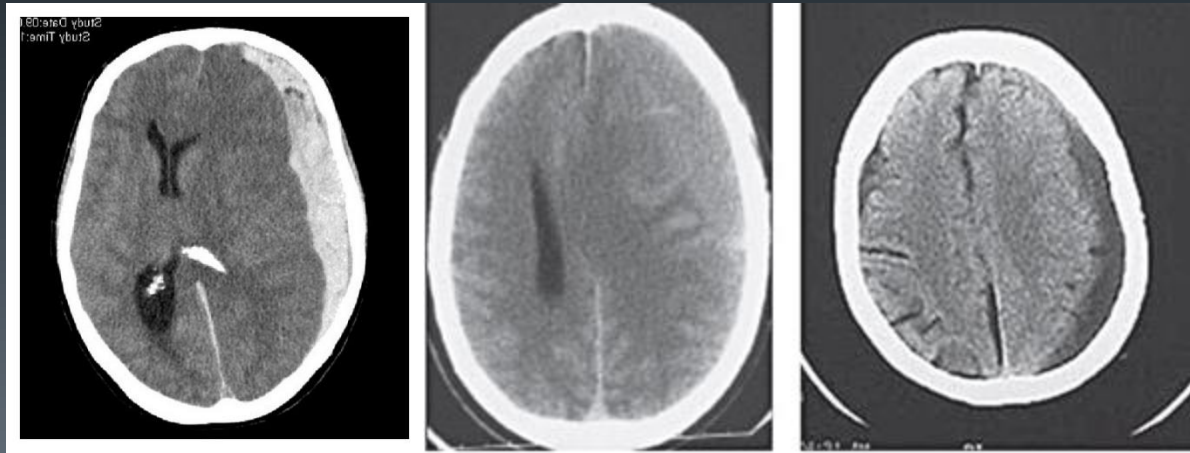
Brain CT Scan Reading Blood

CROSS-SECTION



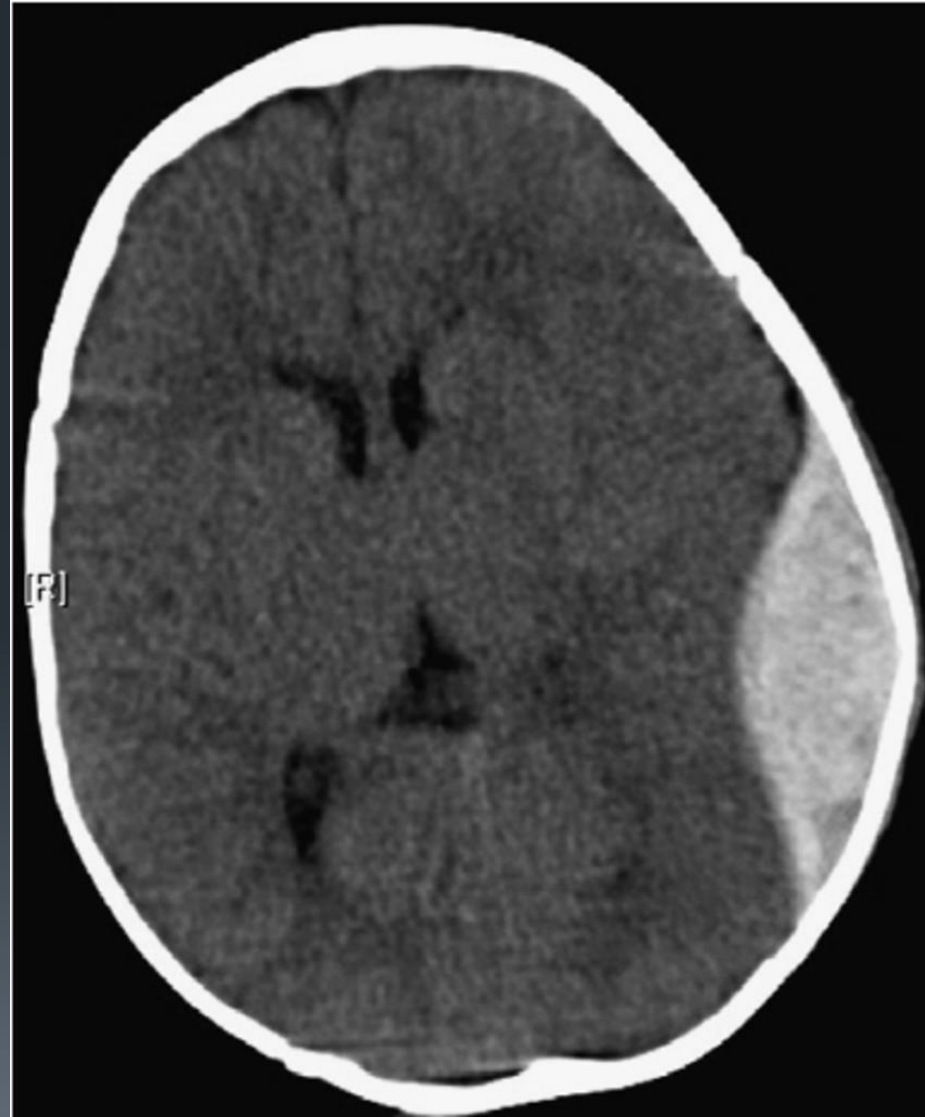Brain CT Scan Reading Blood

- Attenuation Coefficient
- Acute : 70 HU (Globin and Hem).....1w
- Sub Acute : 30-45 HU1-2 wk
- Chronic : <30 HU.....2-3 wk



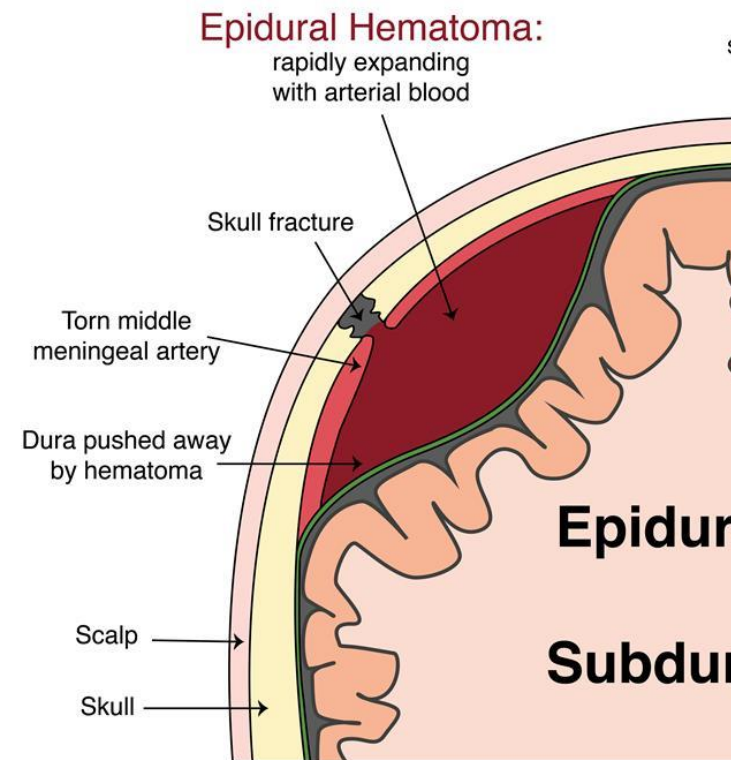
Brain CT Scan Reading Blood

- Epidural Hematoma
- 15mm, 30cc



Brain CT Scan Reading Blood

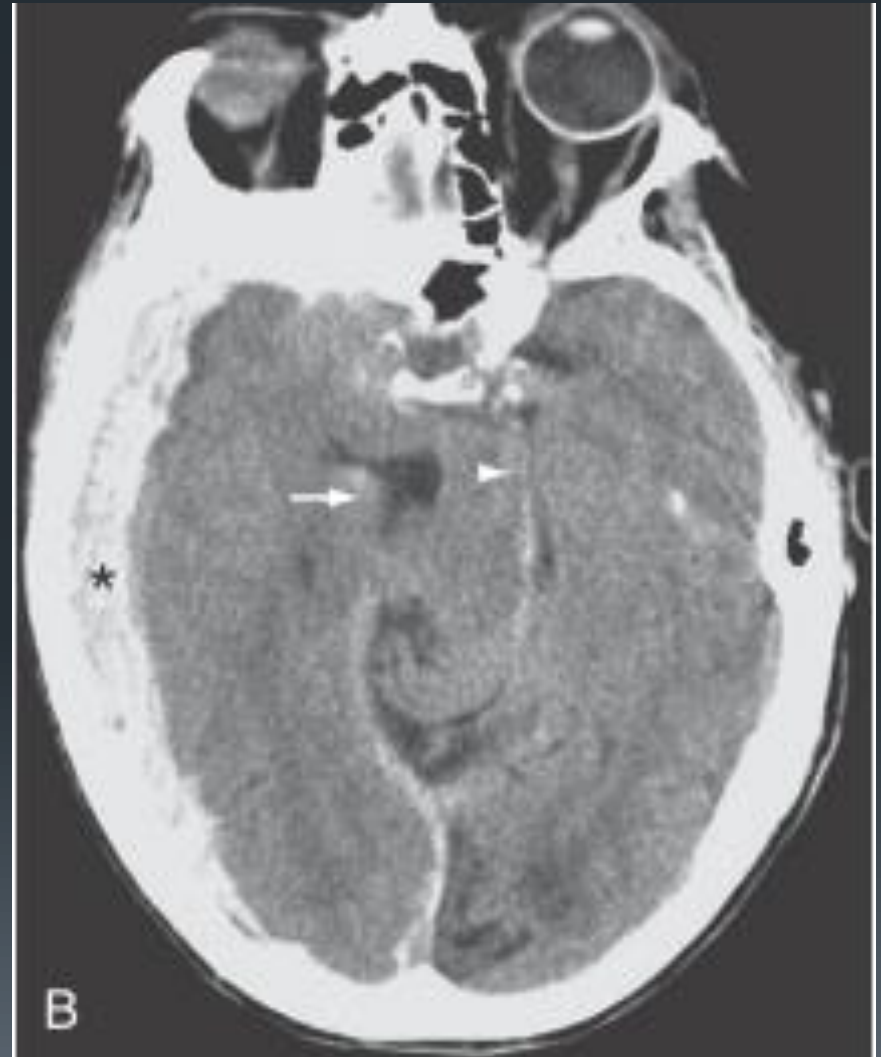
- Epidural Hematoma

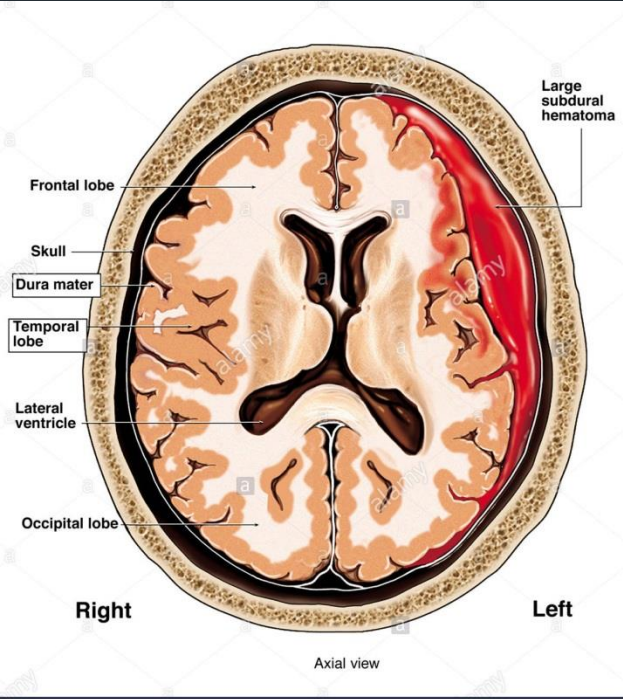


Brain CT Scan Reading...

Blood

- Subdural Hematoma
- 10mm, 5mm MLS

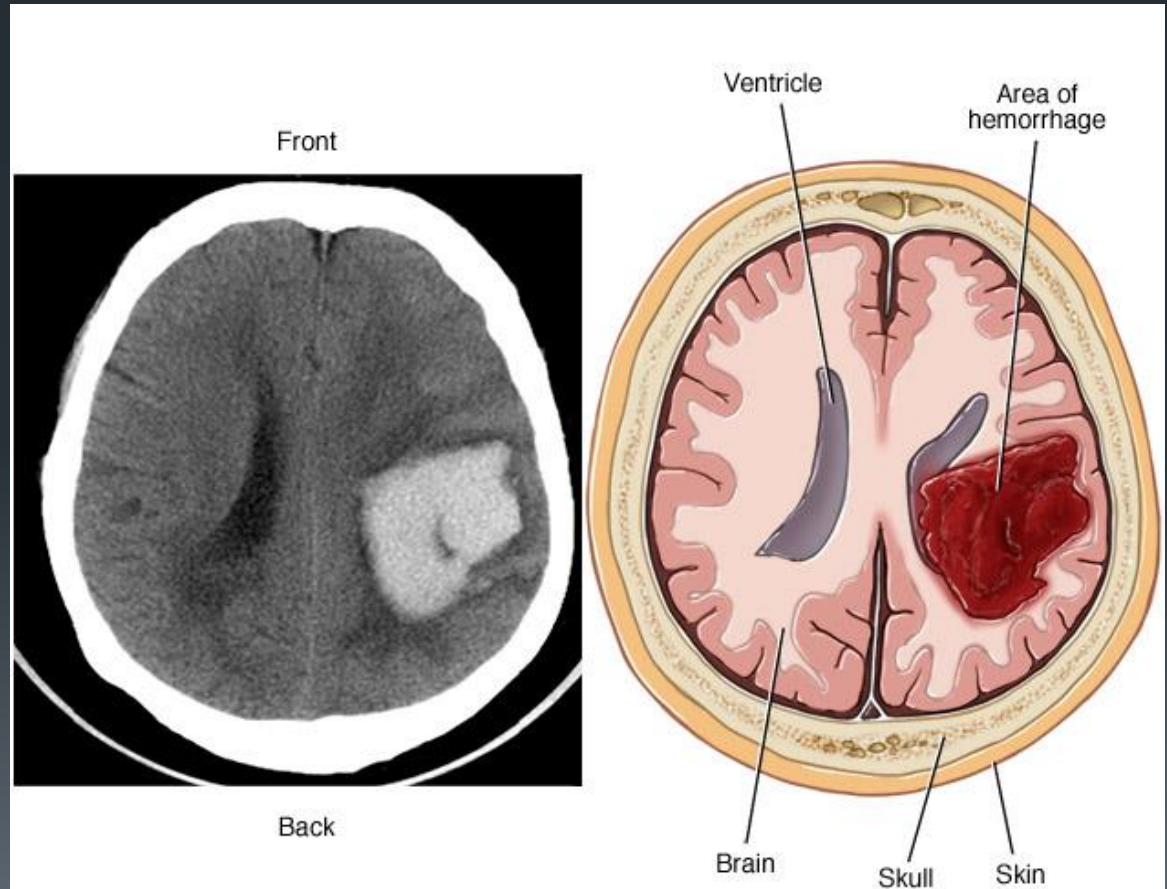




Brain CT Scan Reading...

Blood

- Intracerebral hematoma(or Intraparenchymal hematoma)
- Trauma
- Amyloid Angiopathy
- Avm
- Aneurysm
- Tumor
- 25cc-50cc

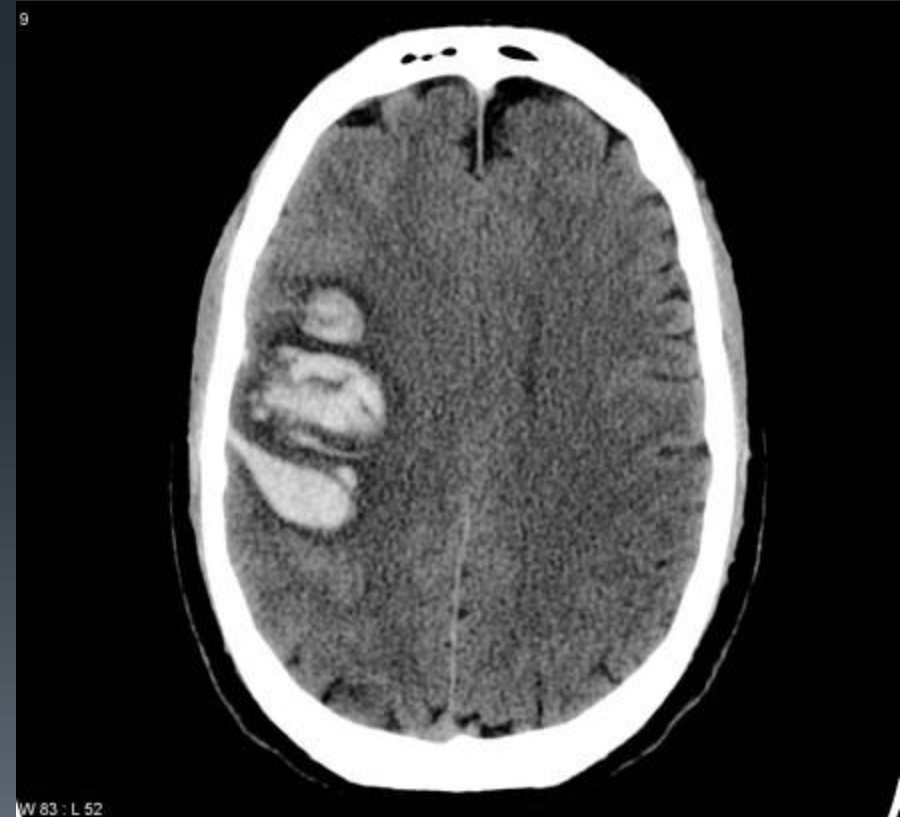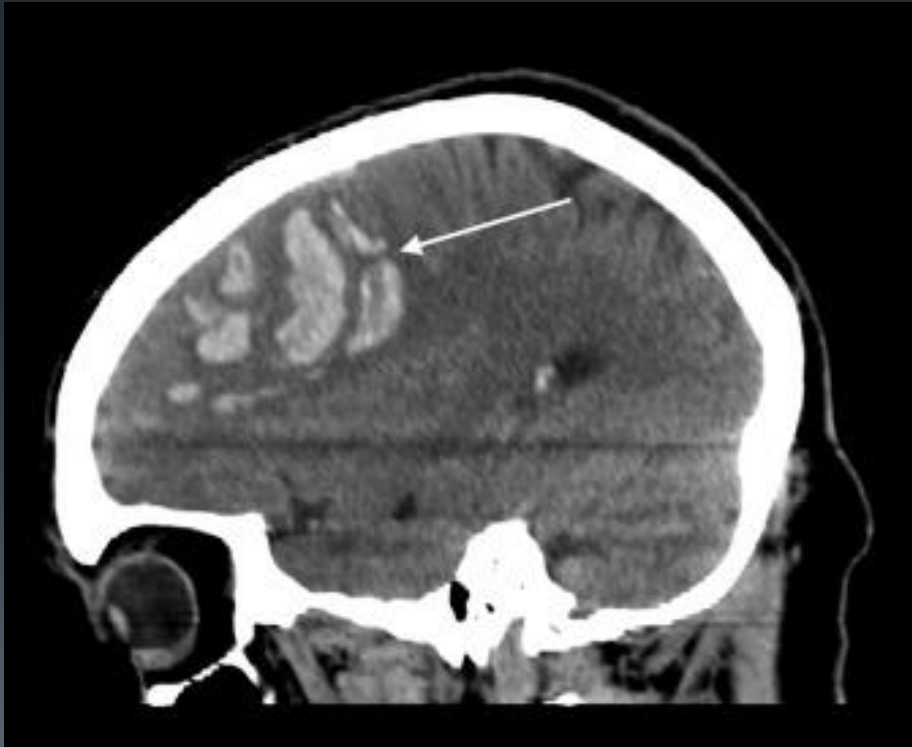


Brain CT Scan Reading...

Blood



- Intracerebral hematoma (or Intraparenchymal hematoma), Due to Cerebral Venous Thrombosis



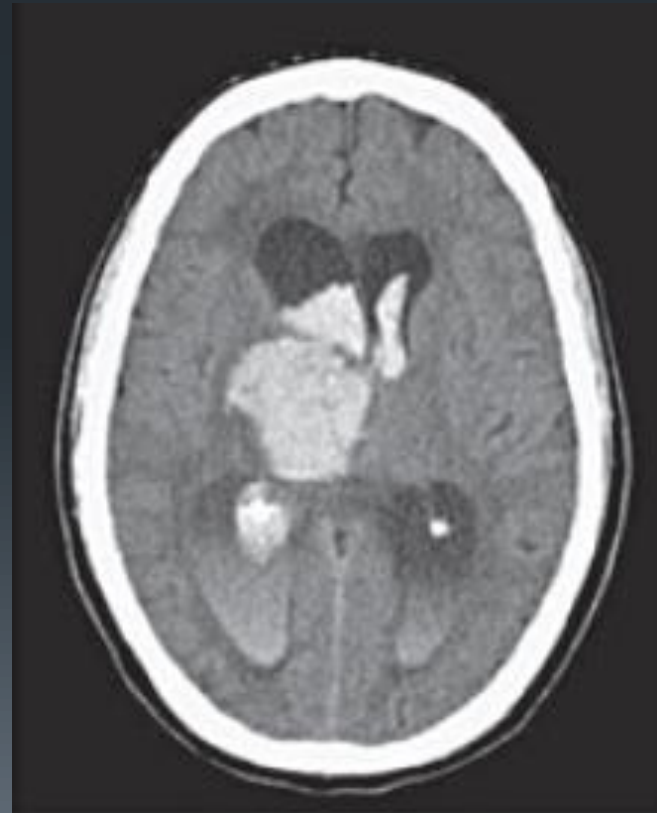Brain CT Scan Reading...

Blood



Intracerebral hematoma(or Intraparenchymal hematoma) Due to Hypertention

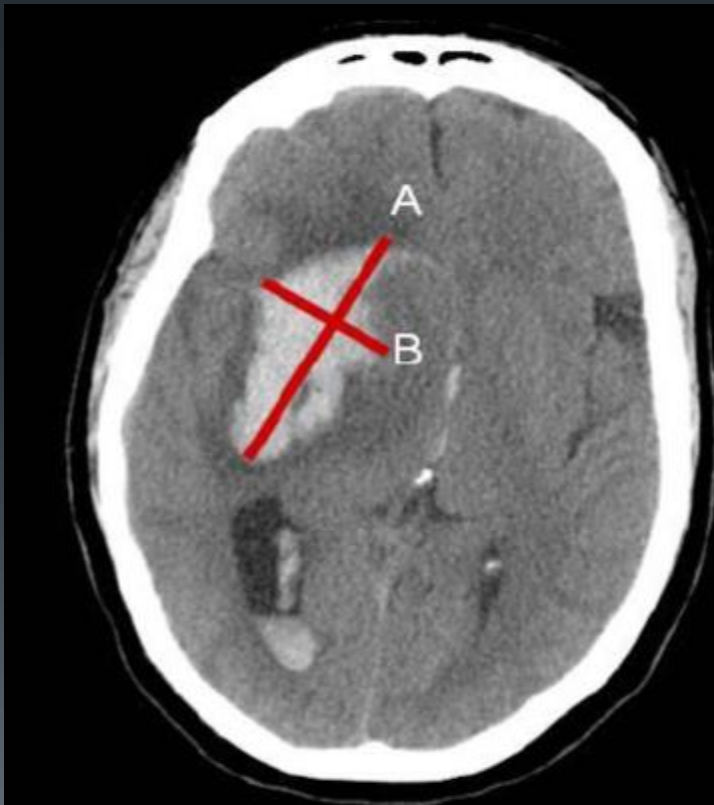
- Basal ganglion
- thalamus
- Cerebellum
- Brain stem



Brain CT Scan Reading...

Blood

- Intracerebral hematoma (or Intraparenchymal hematoma), (globe ~25mm)



$$\frac{A \times B \times C}{2}$$

Select CT slice with largest ICH

A = longest axis (cm)

B = longest axis perpendicular to A (cm)

C = # of slices x slice thickness (cm)

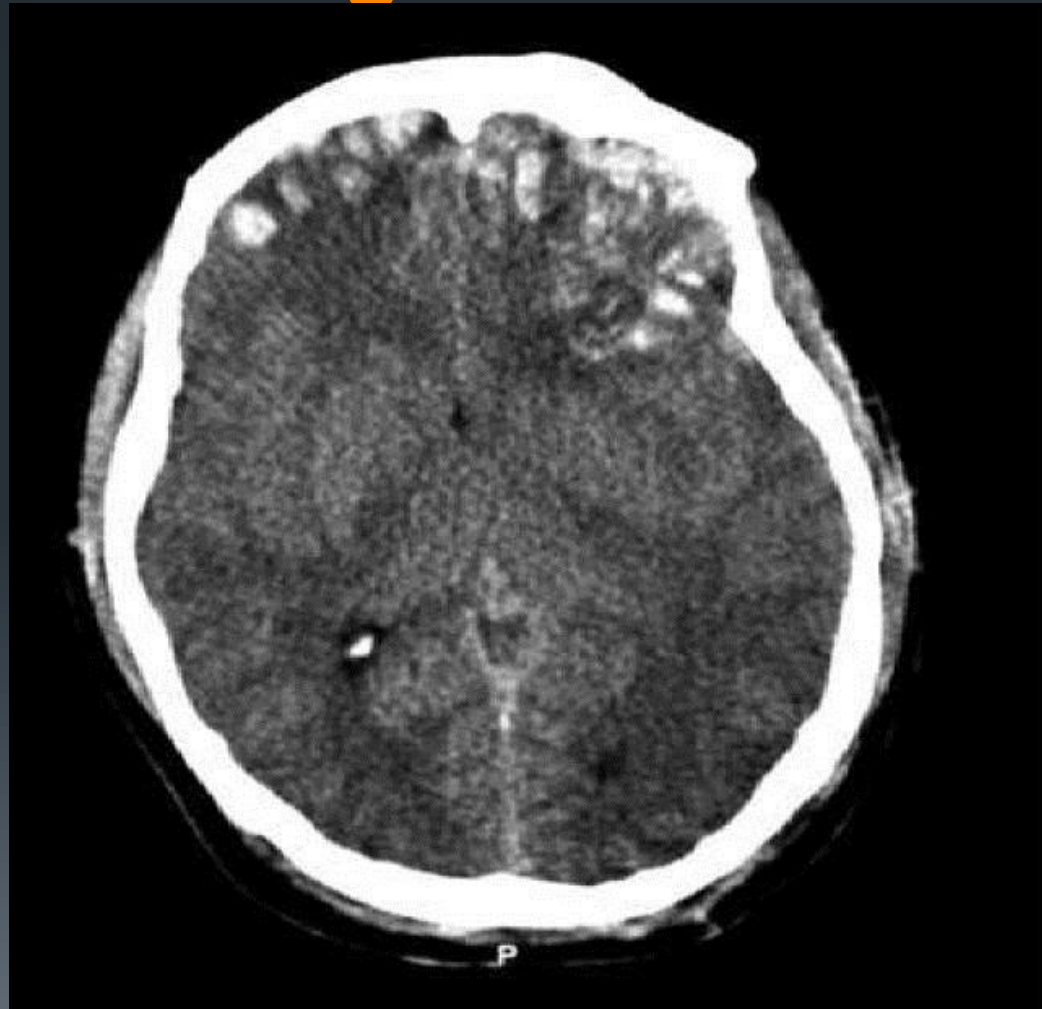Estimated volume of spheroid

Correlates well w/ planimetric CT analysis

Brain CT Scan Reading...

Blood

- Contusion

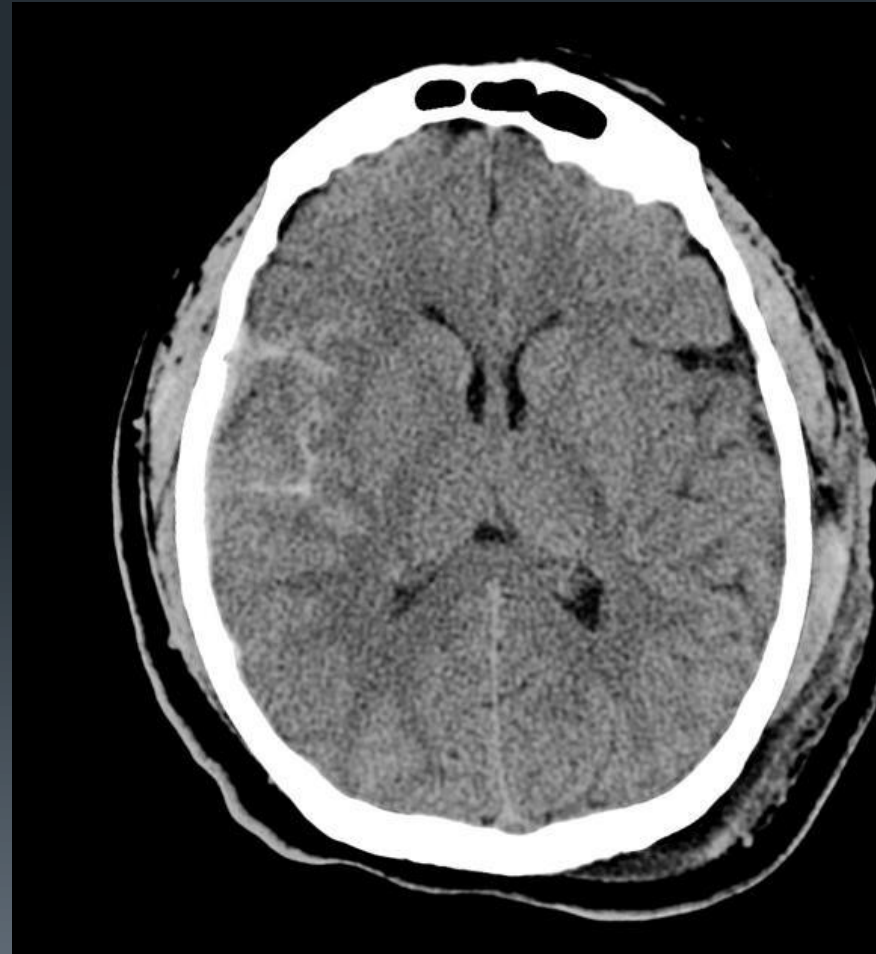


Brain CT Scan Reading...

Blood



- Sub Arachnoid Hematoma

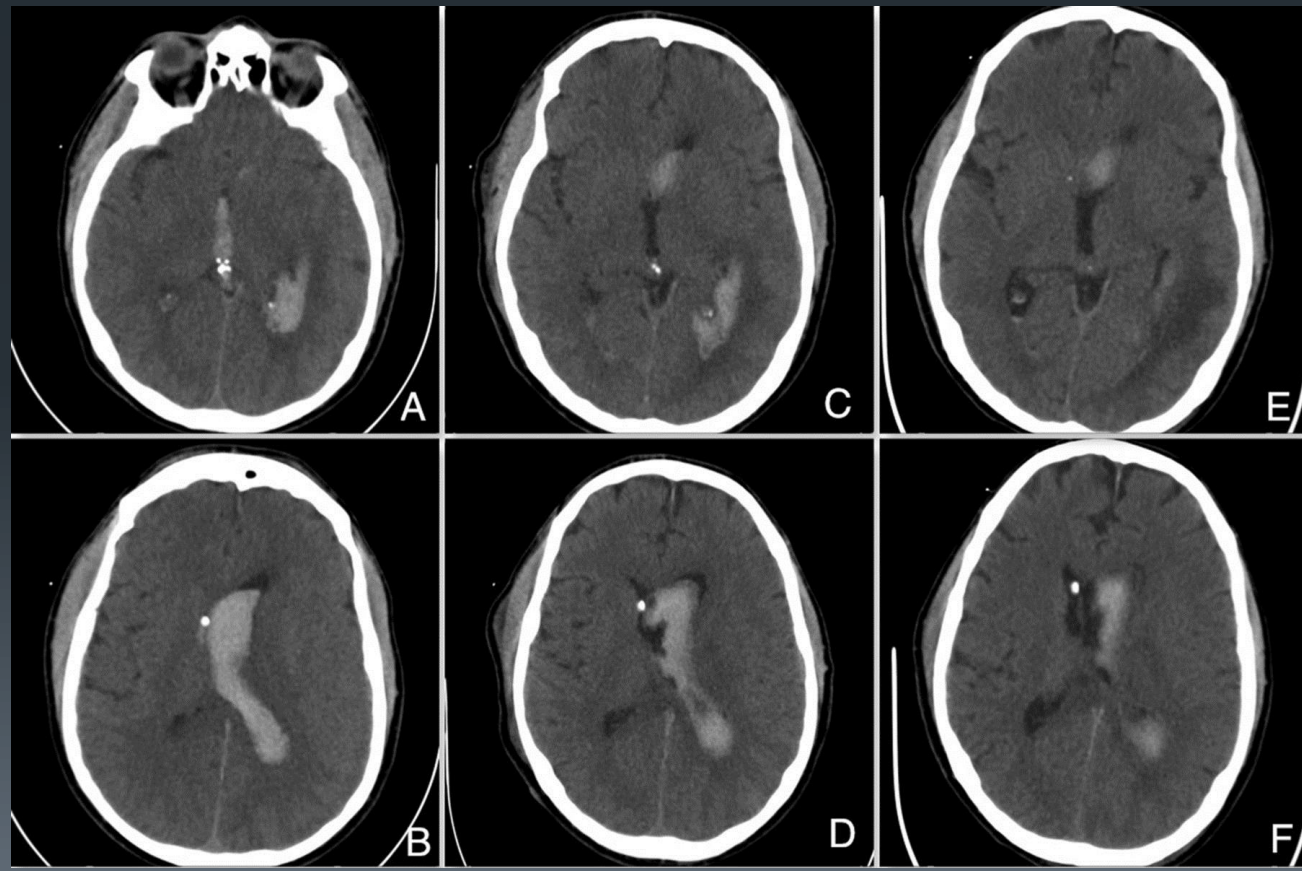


Brain CT Scan Reading...

Blood



- Intraventricular Hematoma





Cistern



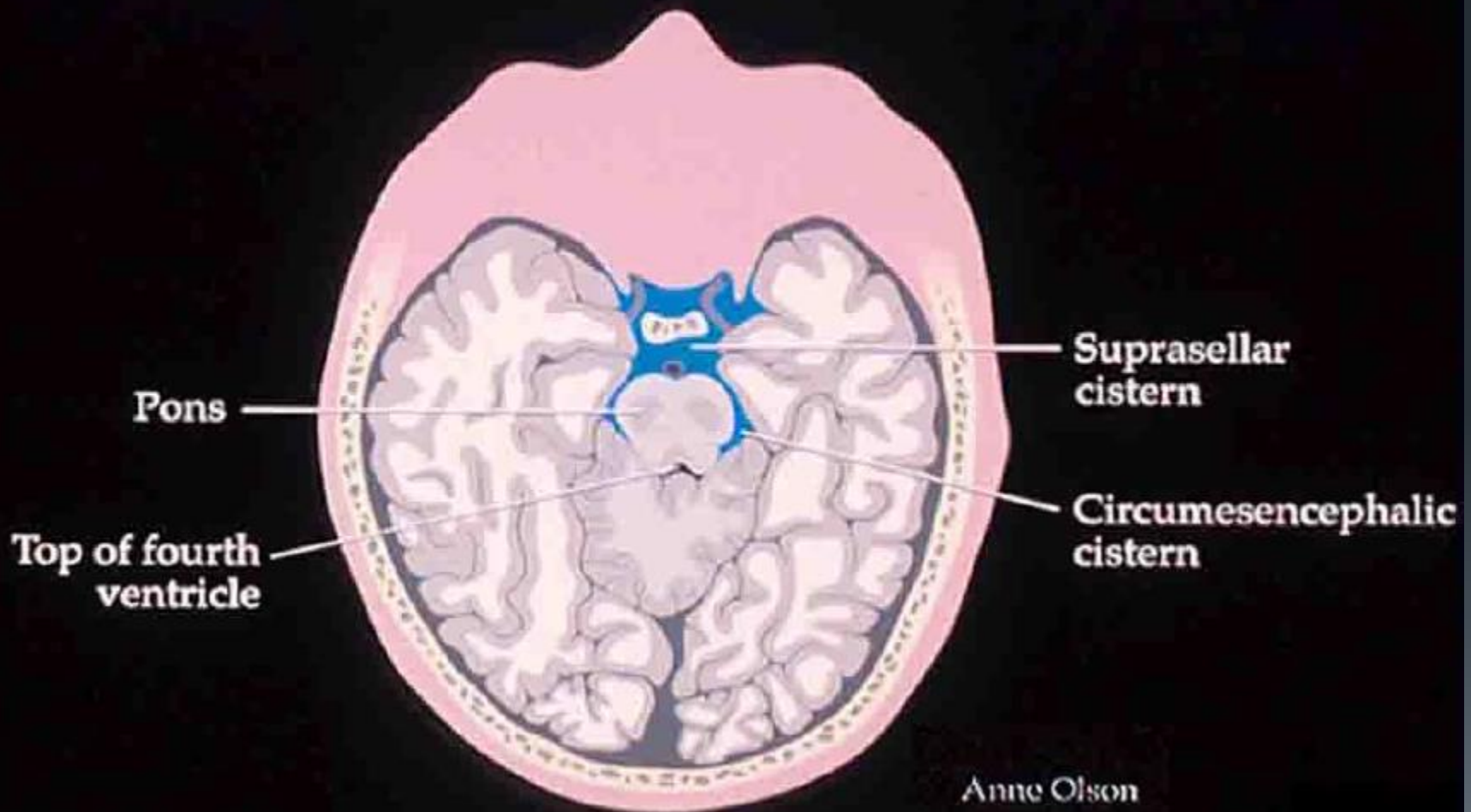
Brain CT Scan Reading...

Cistern

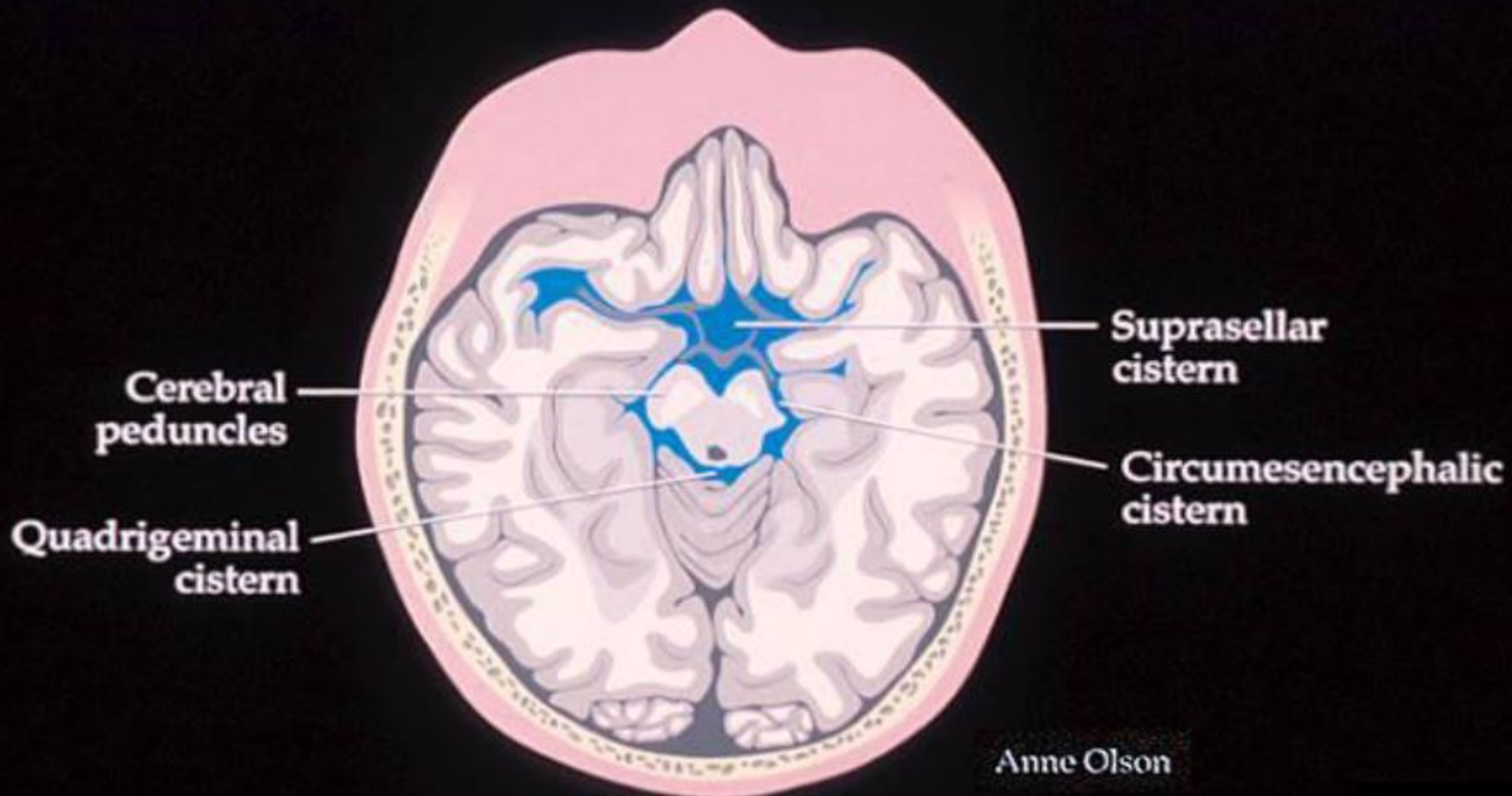
- Importance(Effacement, Hematoma)



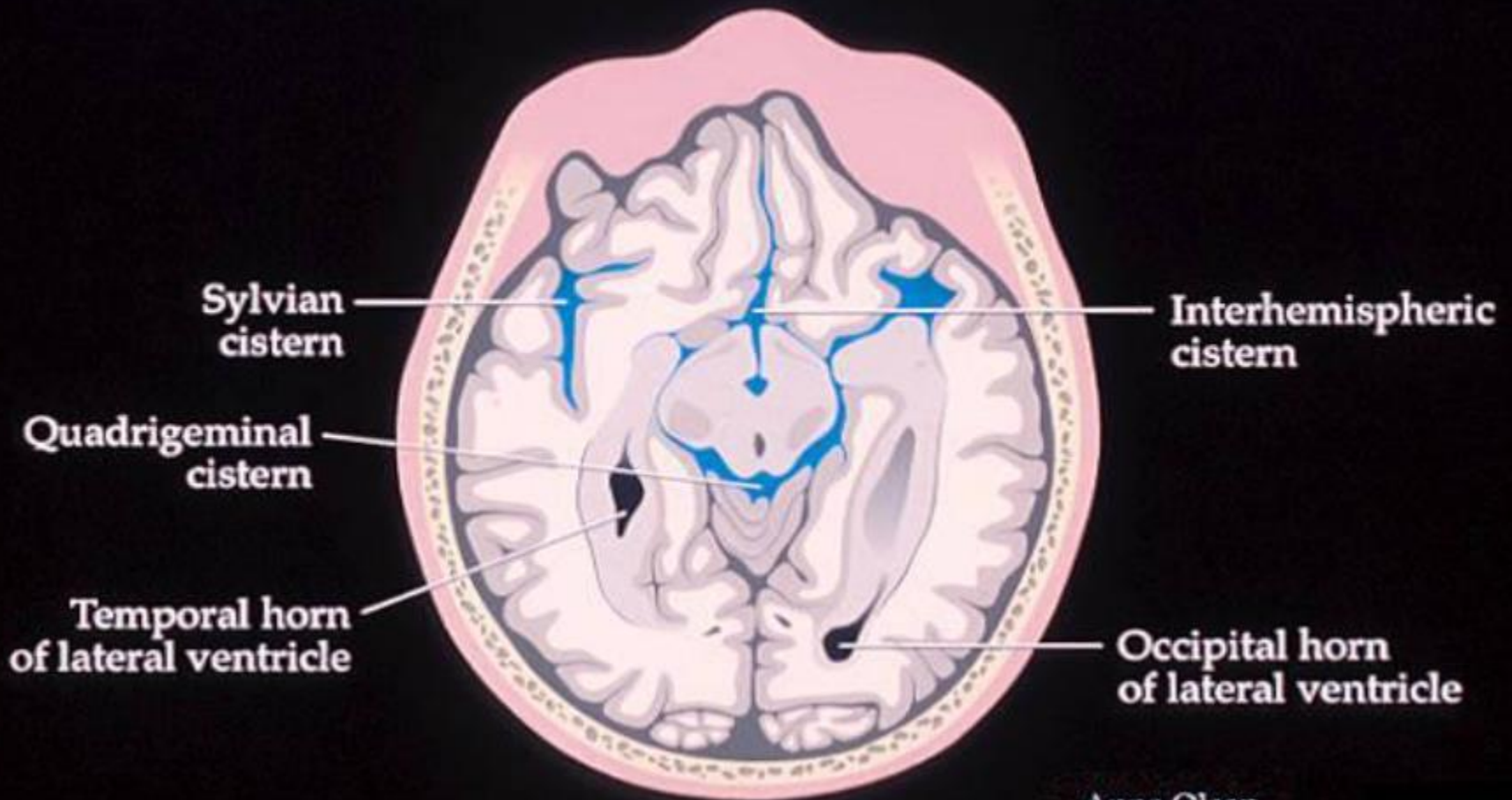
1. Cisterns Viewed at High Pontine Level



2. Cisterns Viewed at Level of Cerebral Peduncles



3. Cisterns Viewed at High Mid-Brain Level

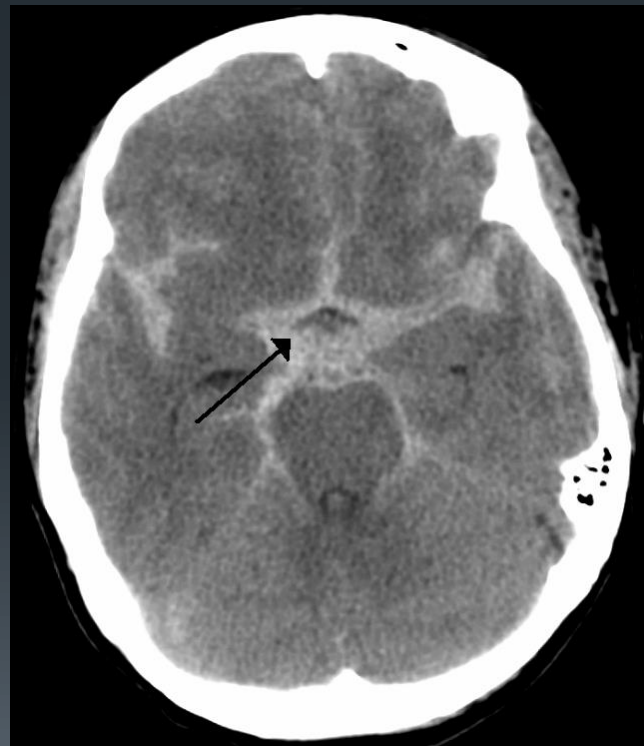

Anne Olson

Brain CT Scan Reading...

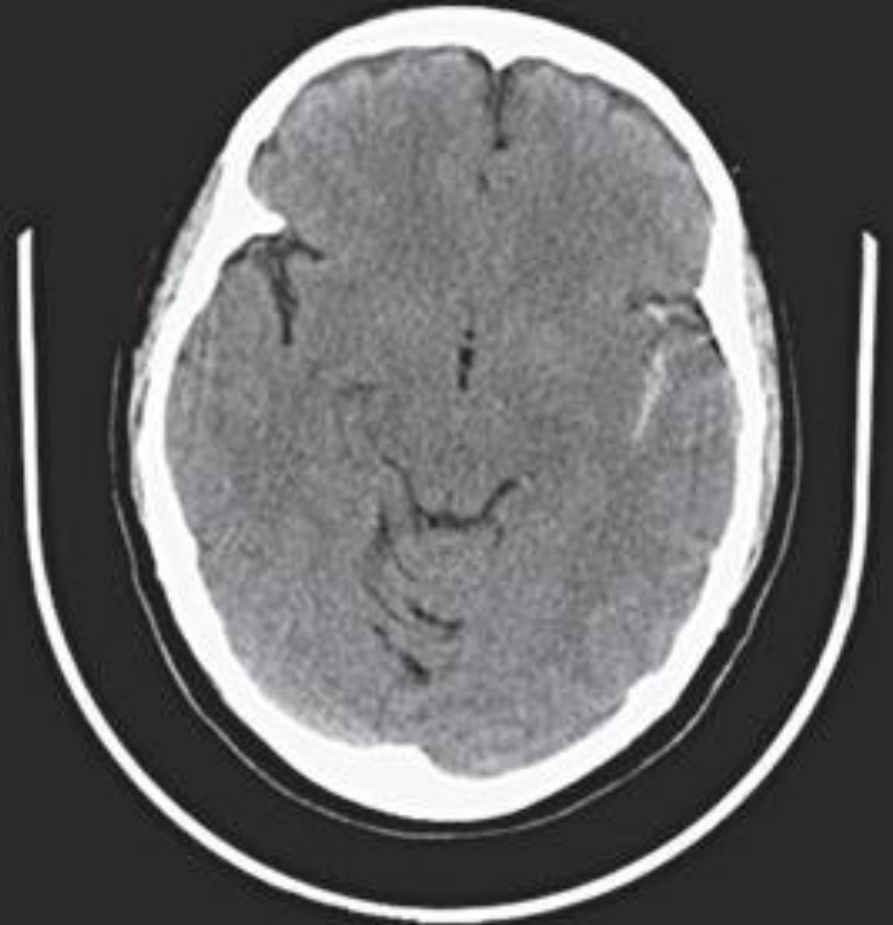
Cistern

SAH



GCS

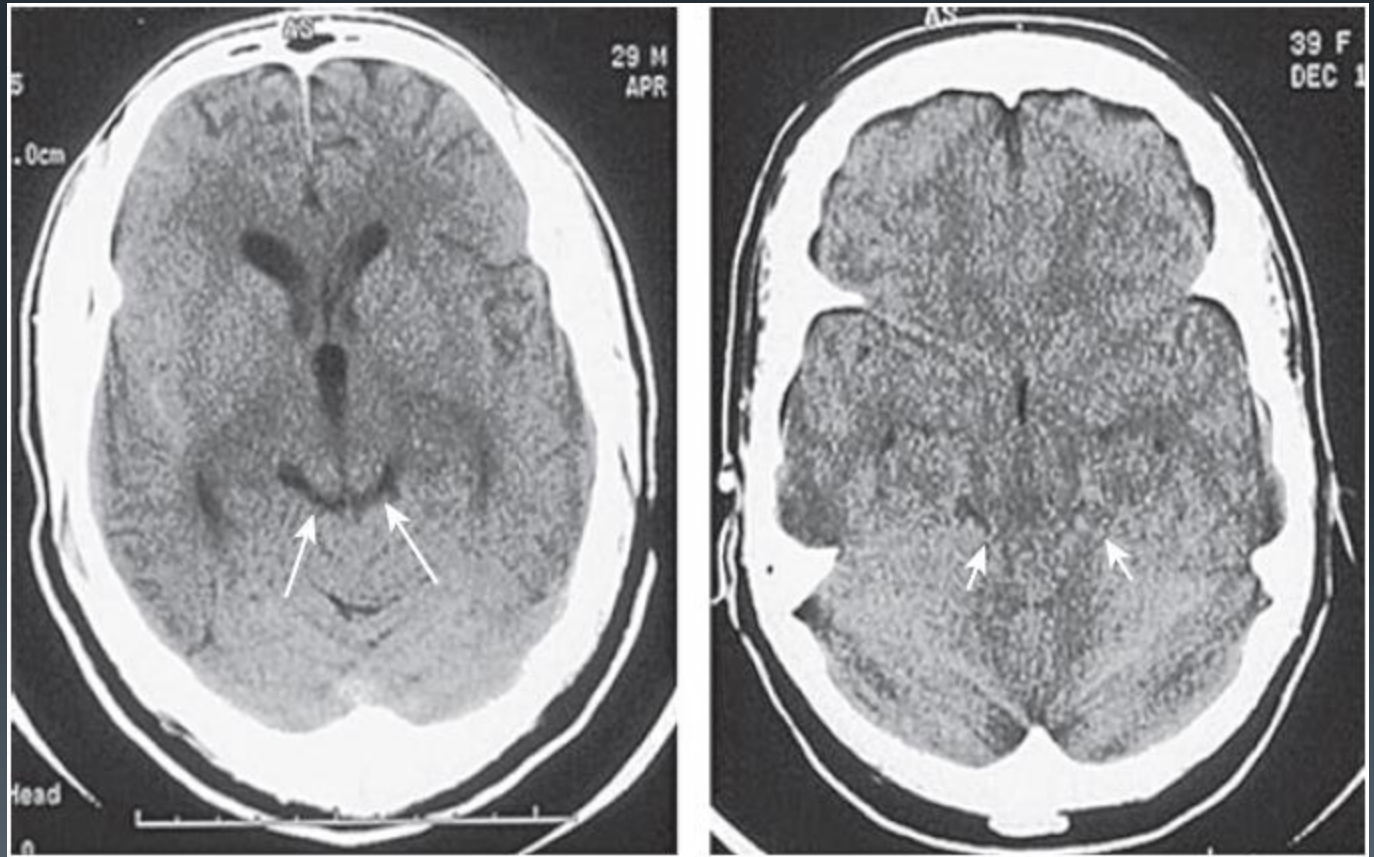
SAH



Brain CT Scan Reading...

Cistern

- Normal ~ Elevated Intracranial Pressure





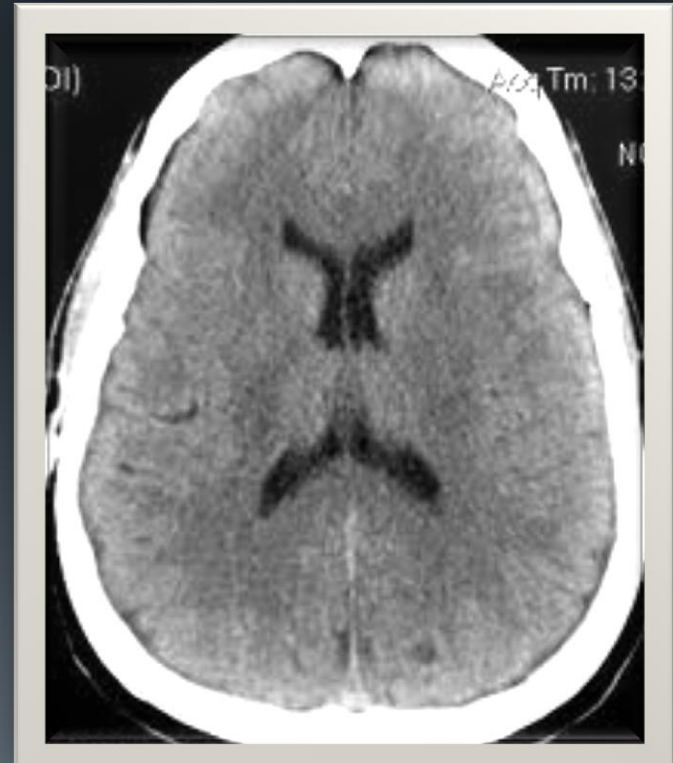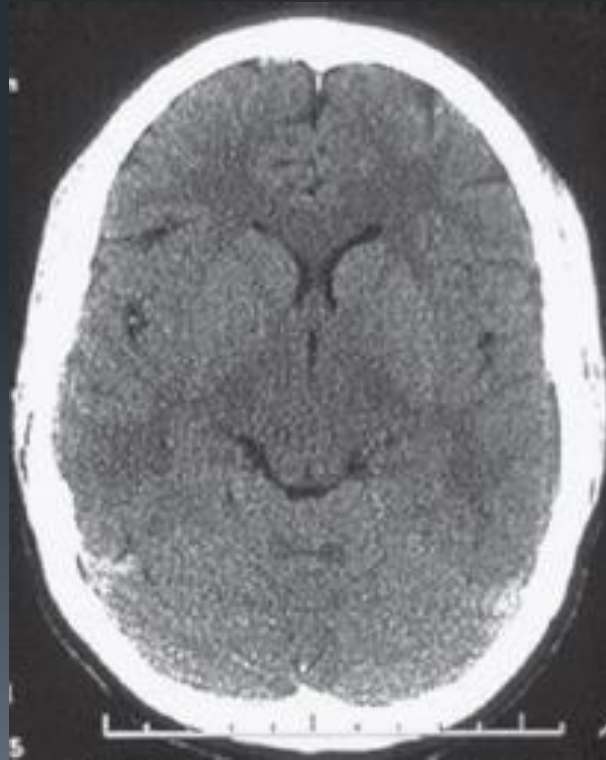
BRAIN

Brain CT Scan Reading...

Brain (Normal)

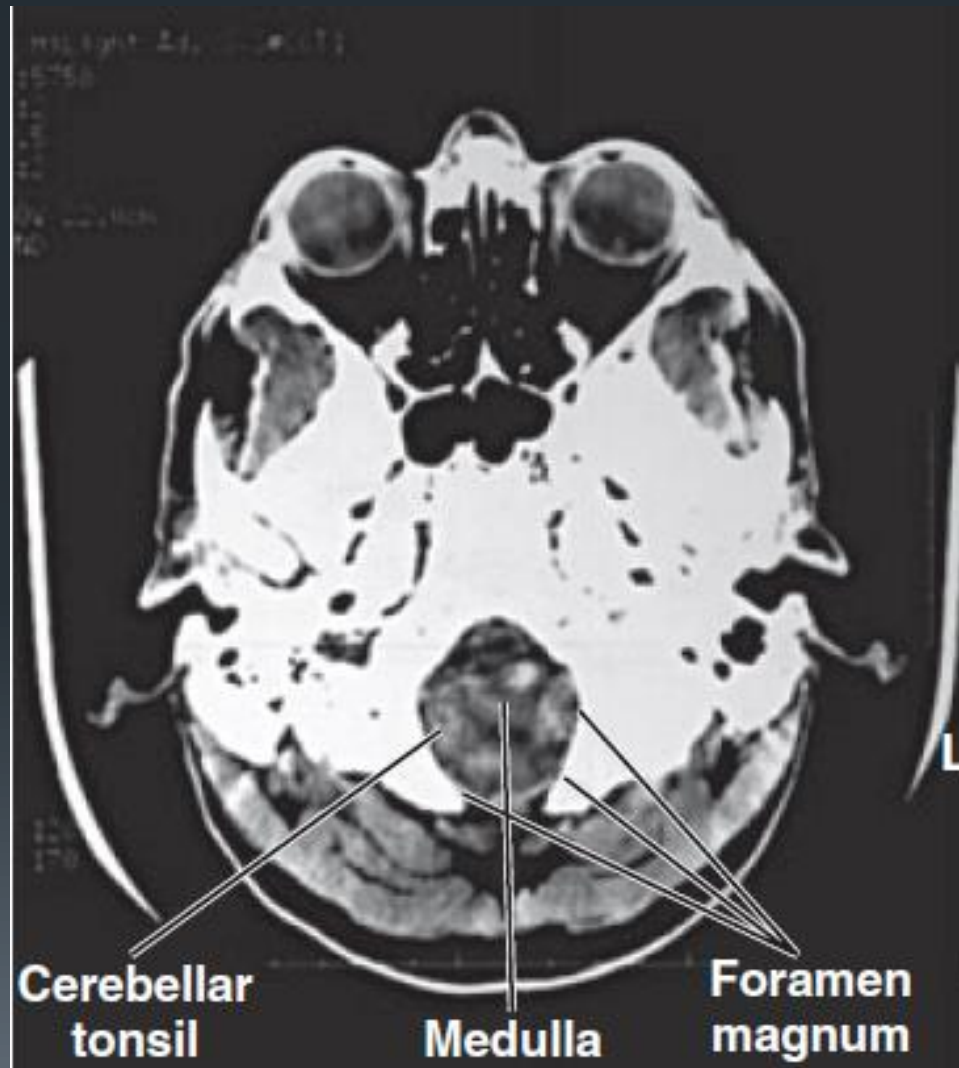


Gray matter_ white matter Differentiation
Symmetry
Sulcuses
Midline Shifting(5mm)



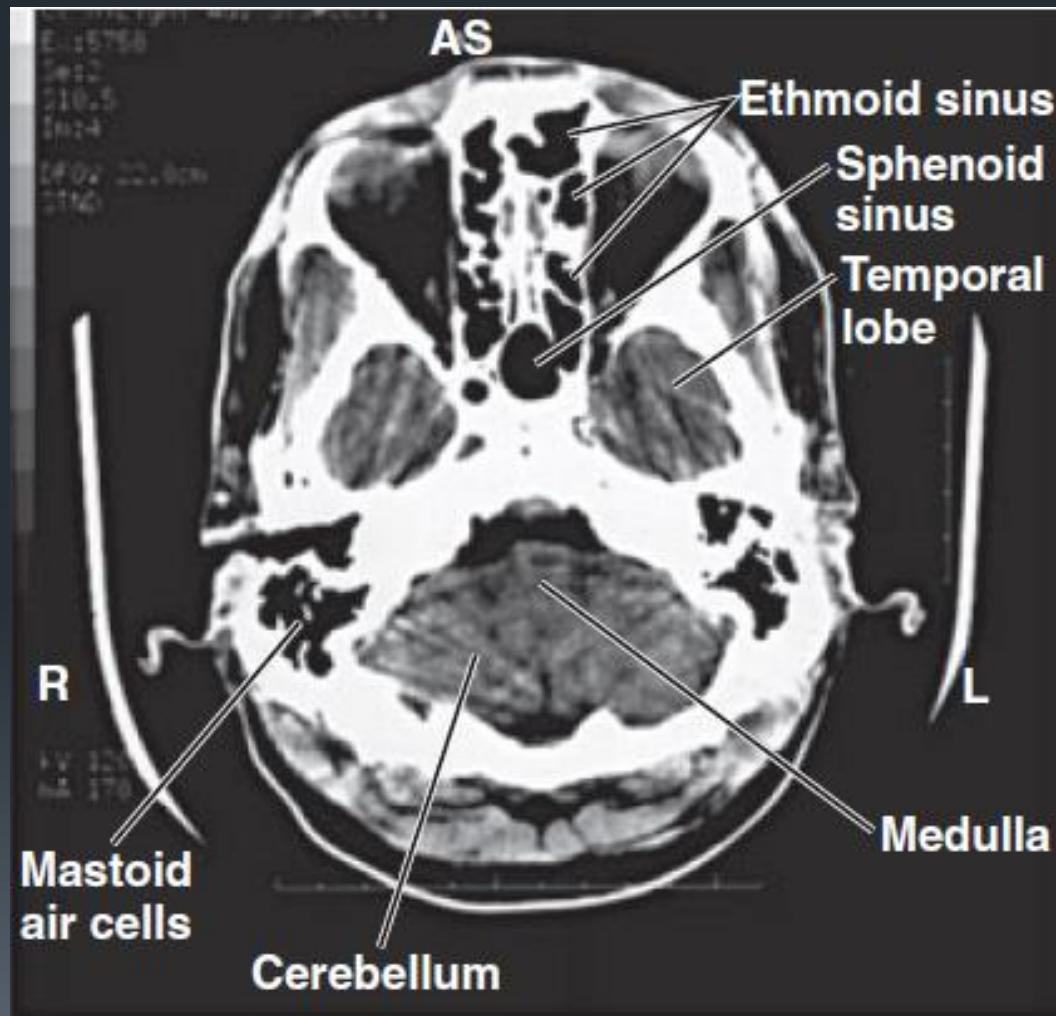
Brain CT Scan Reading...

Brain (Normal)



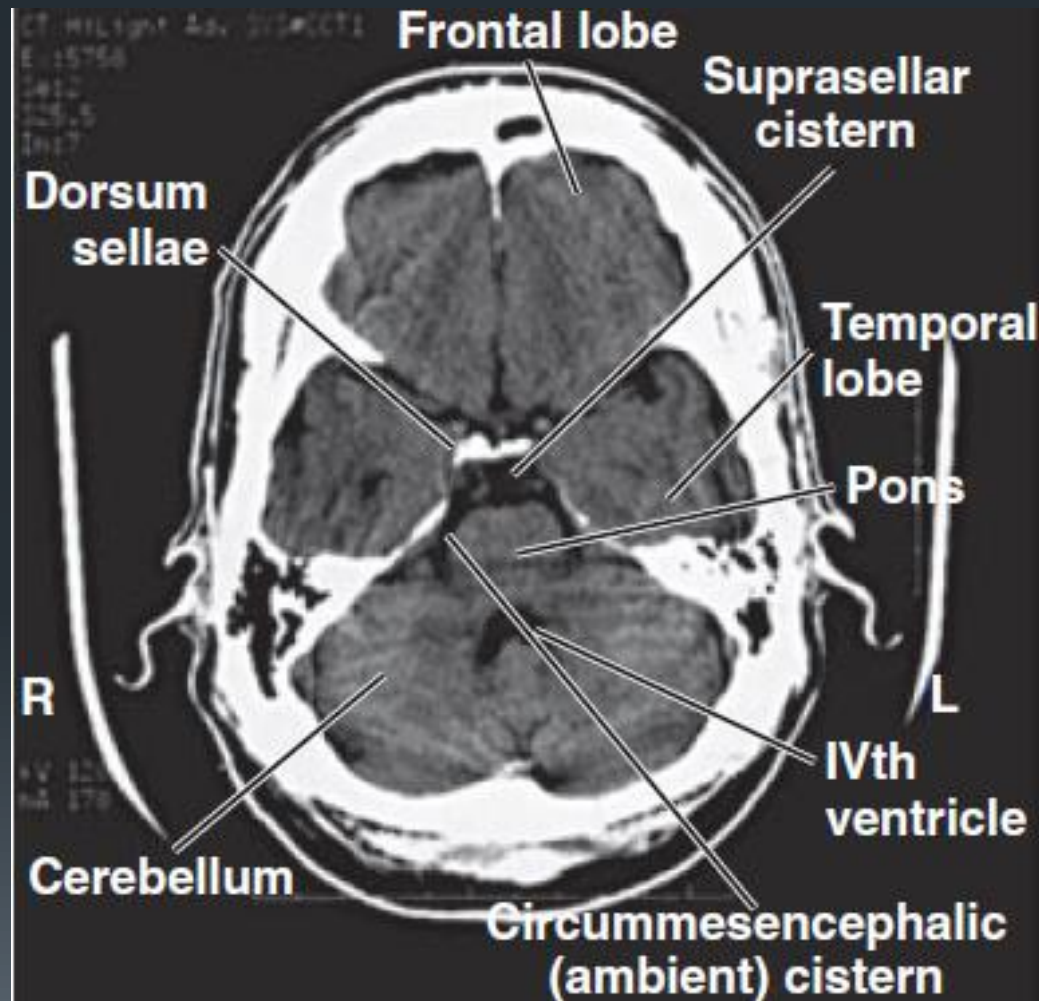
Brain CT Scan Reading...

Brain (Normal)



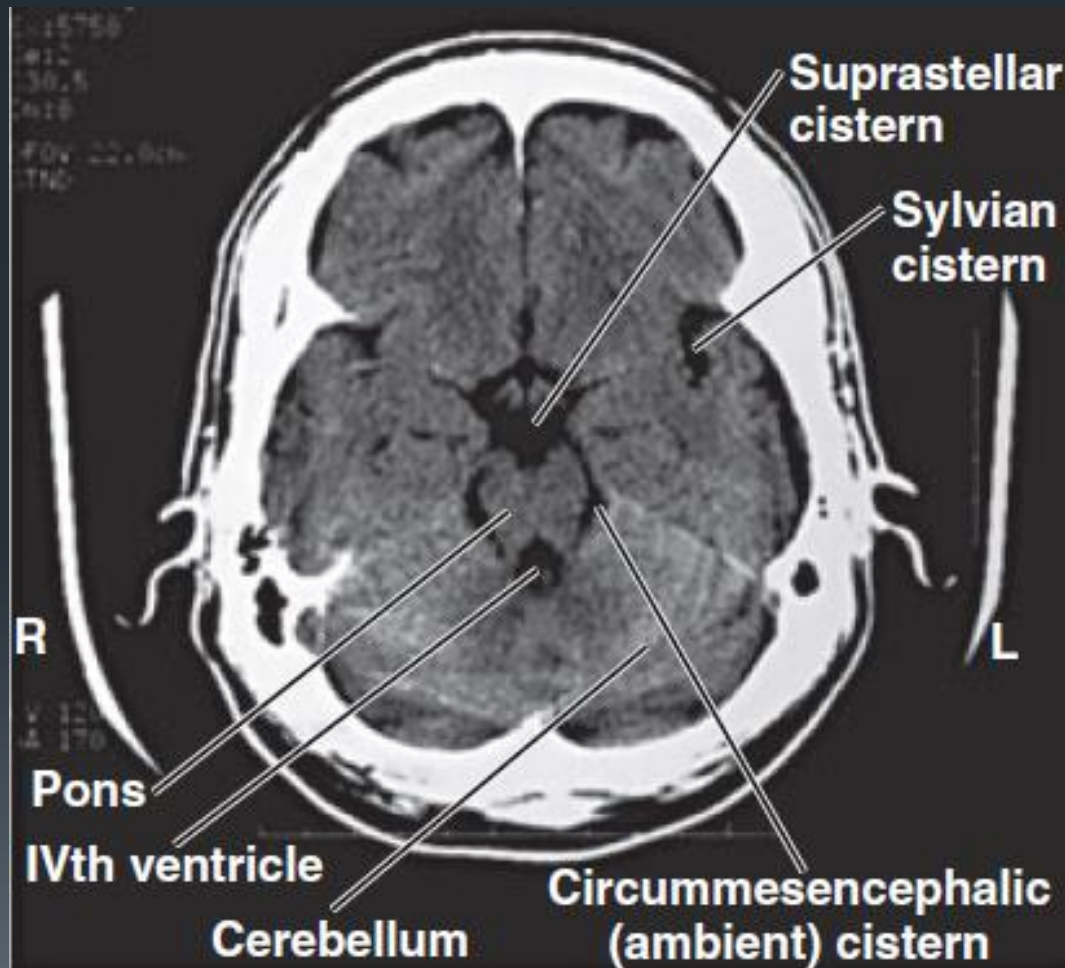
Brain CT Scan Reading...

Brain (Normal)



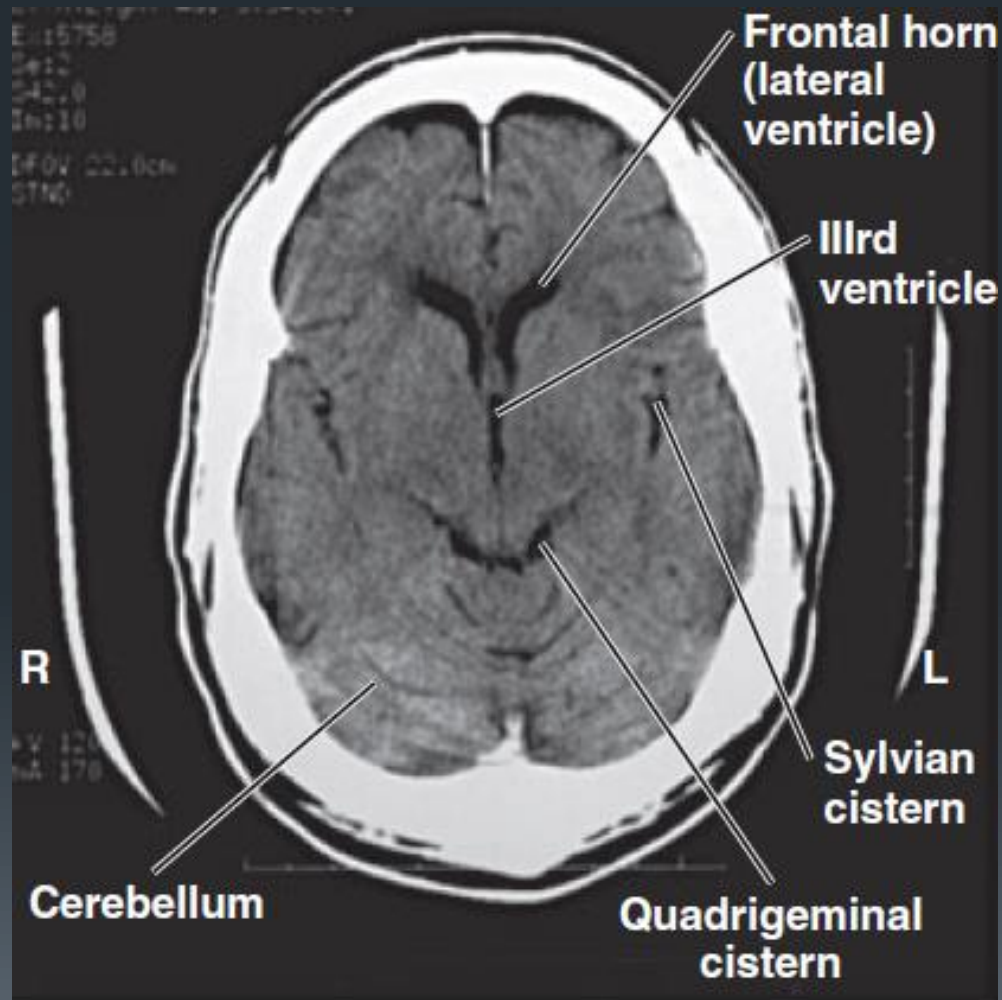
Brain CT Scan Reading...

Brain (Normal)



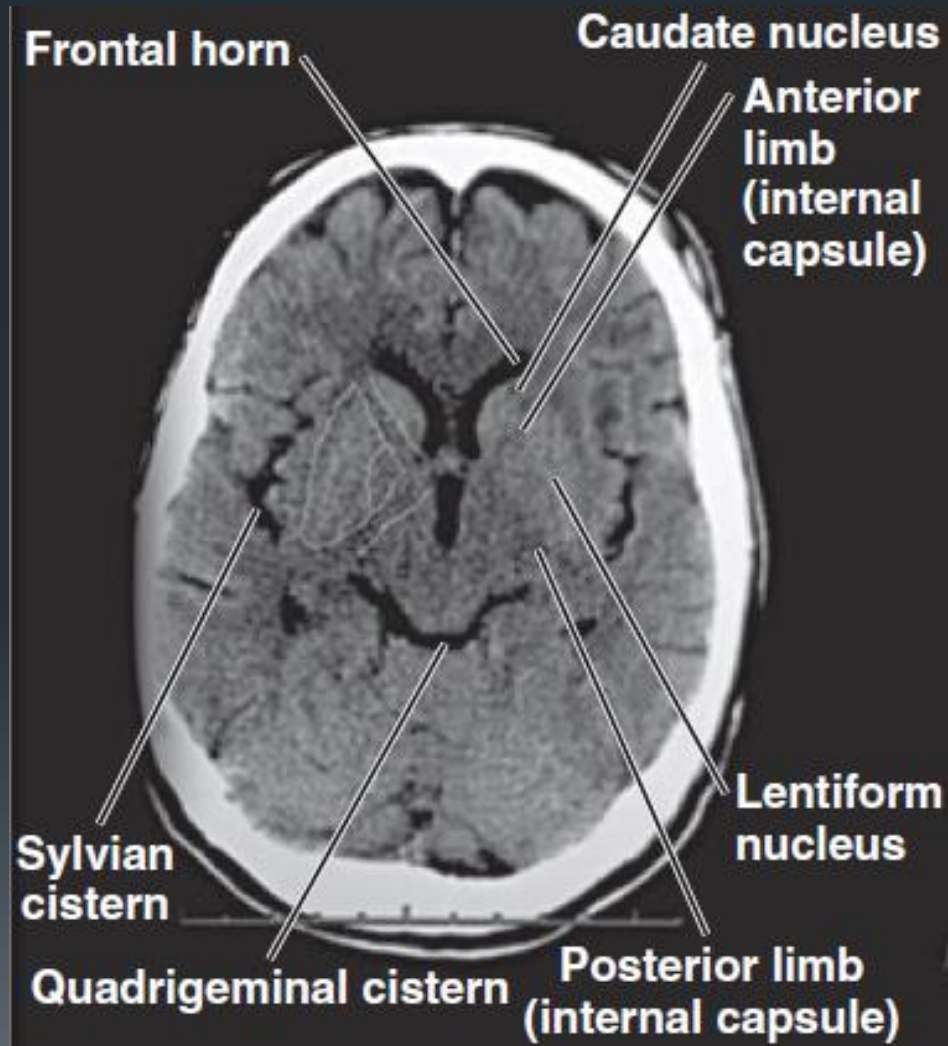
Brain CT Scan Reading...

Brain (Normal)



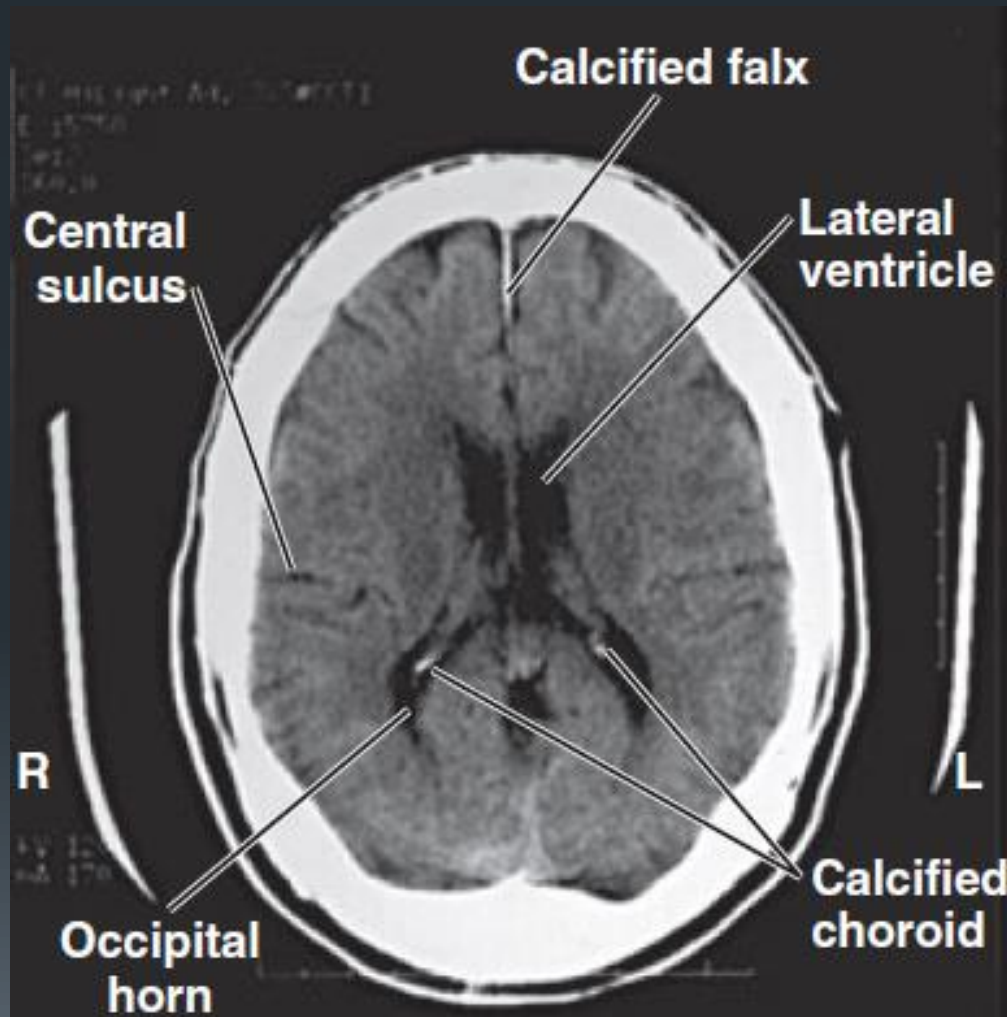
Brain CT Scan Reading...

Brain (Normal)



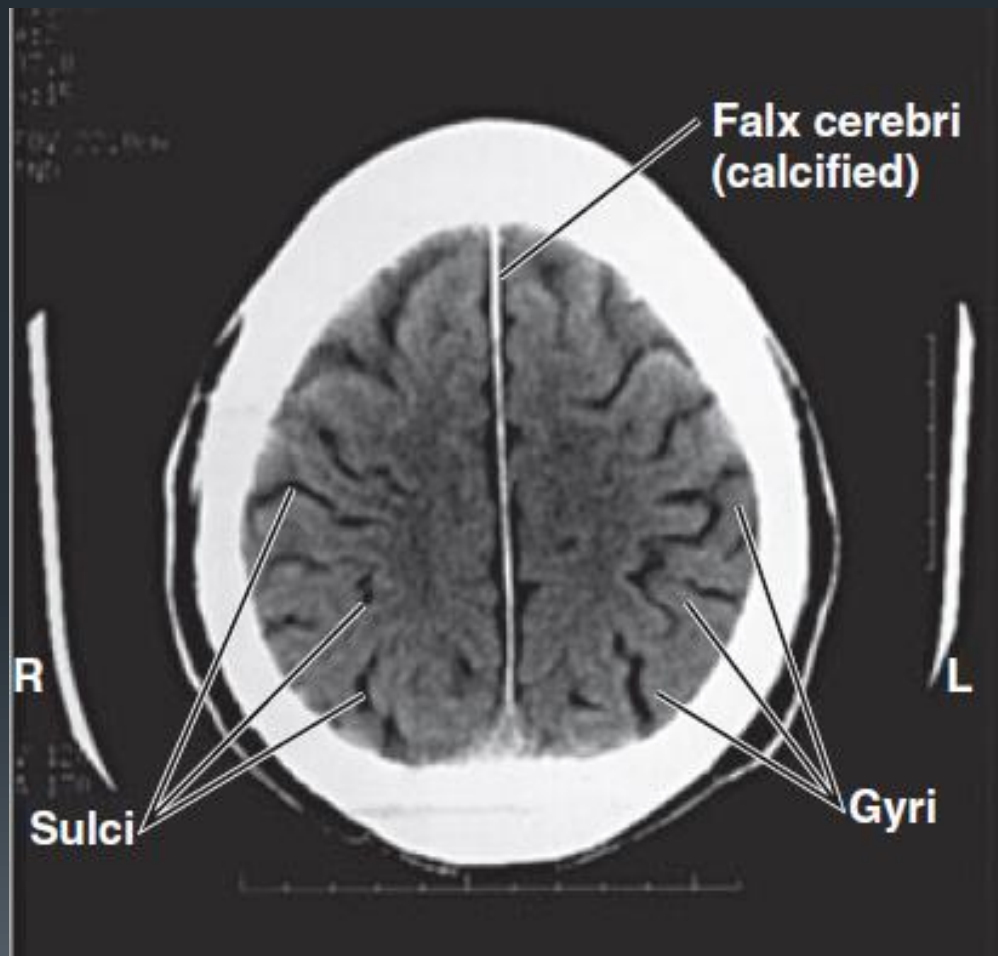
Brain CT Scan Reading...

Brain (Normal)



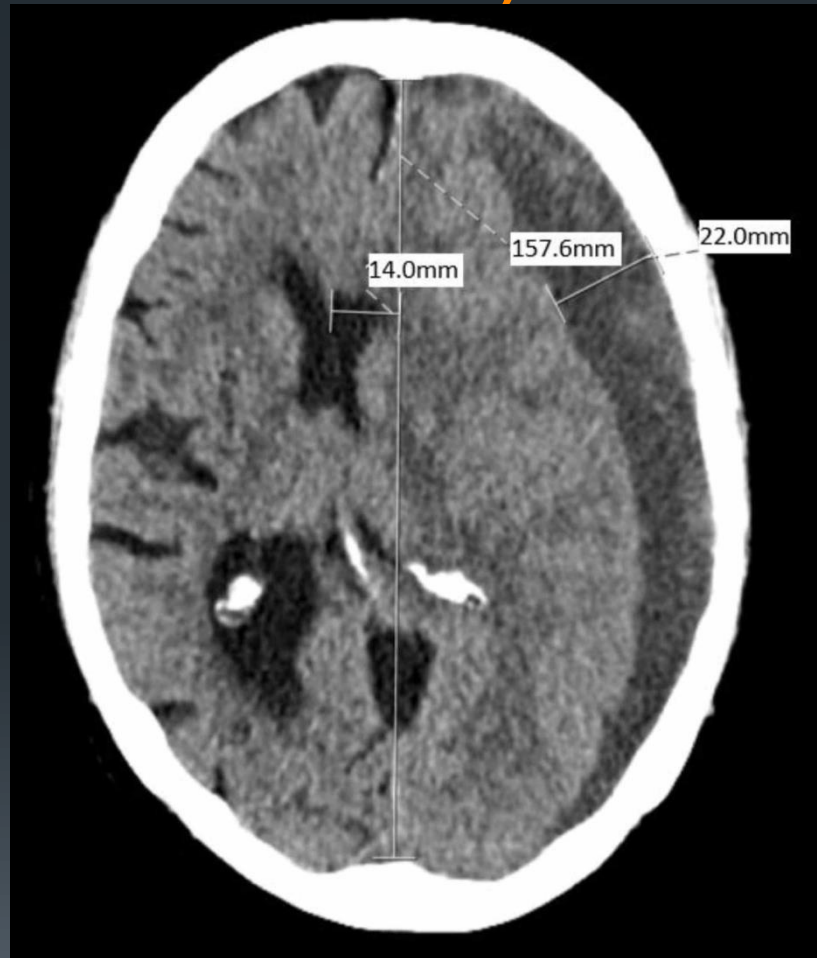Brain CT Scan Reading...

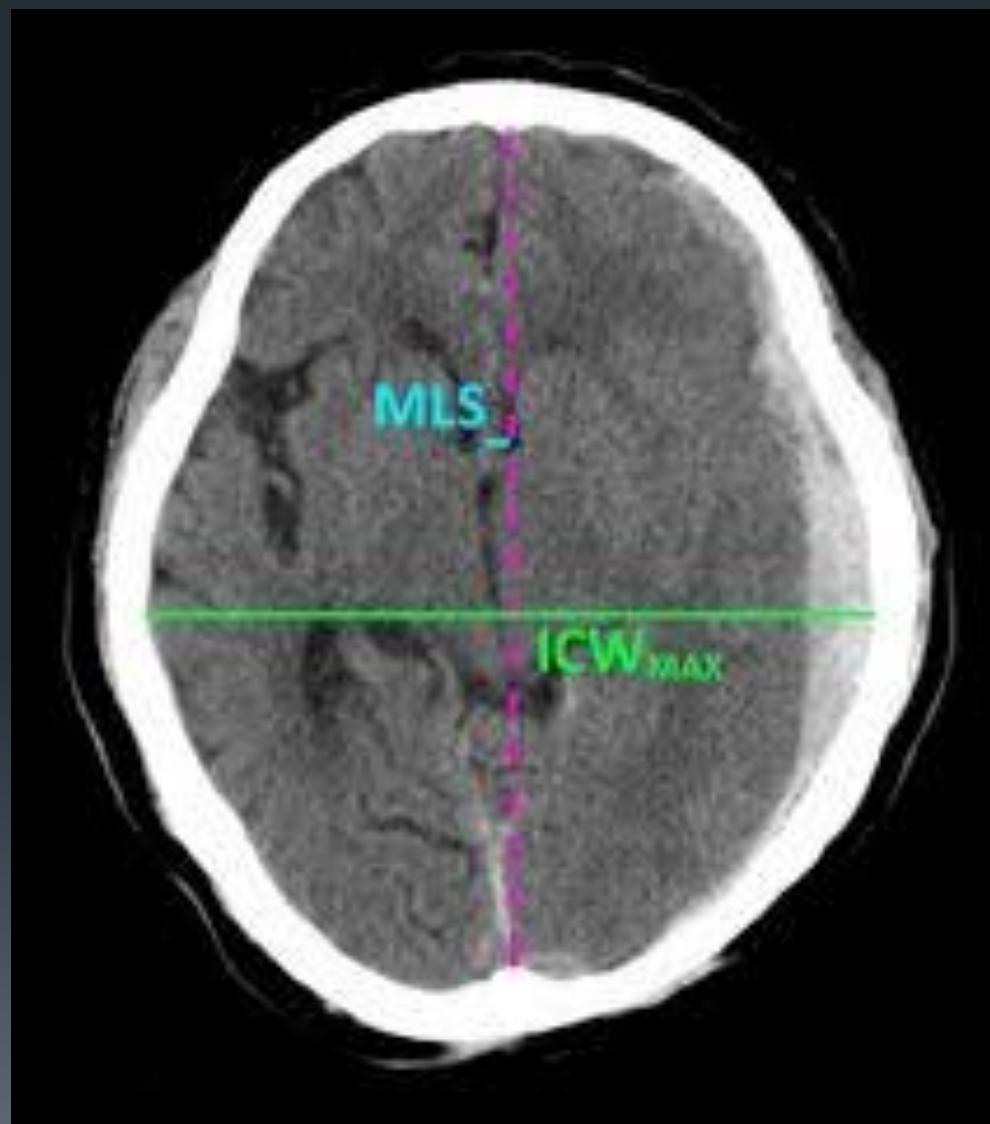
Brain (Normal)



Brain CT Scan Reading...

Brain (Midline Shift)

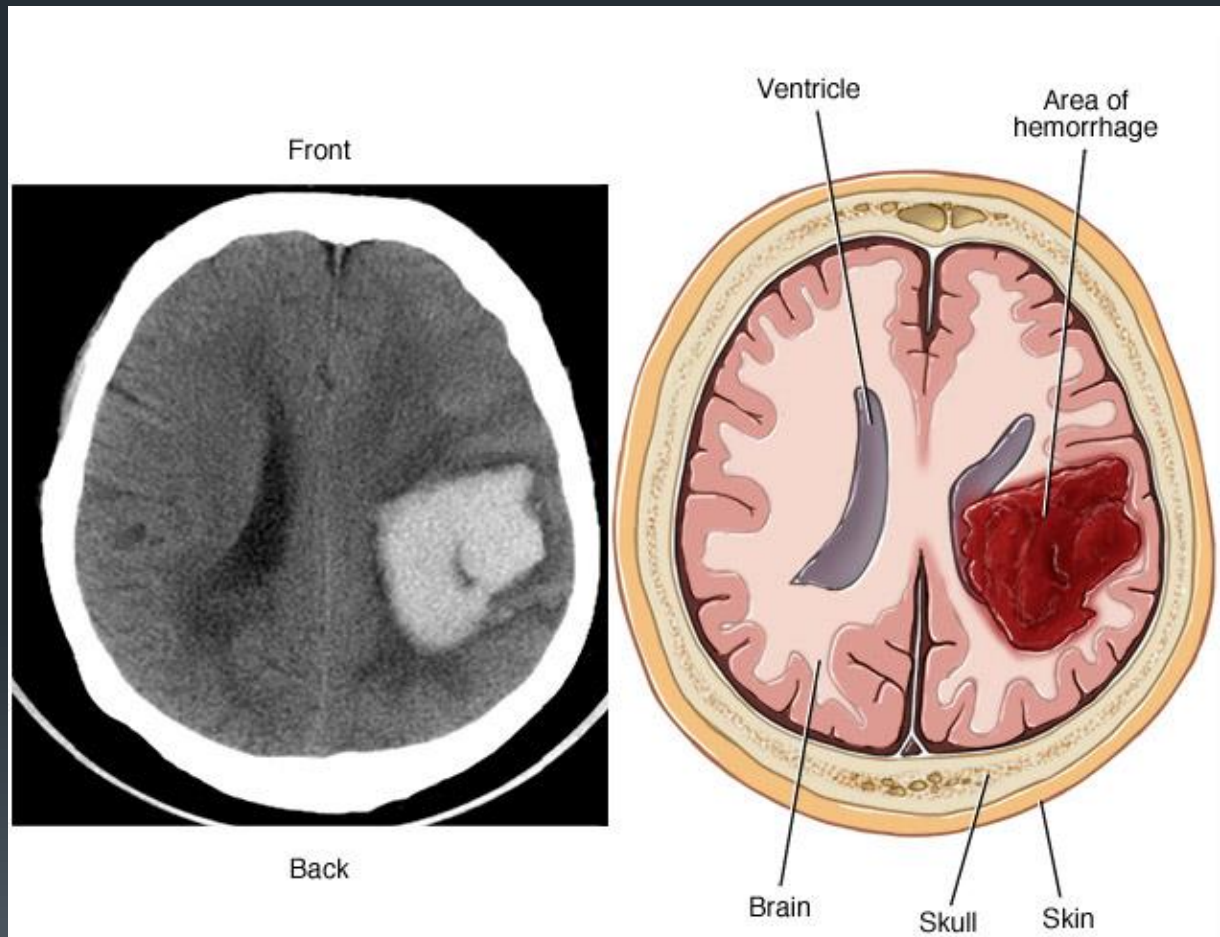




Brain CT Scan Reading...

Brain

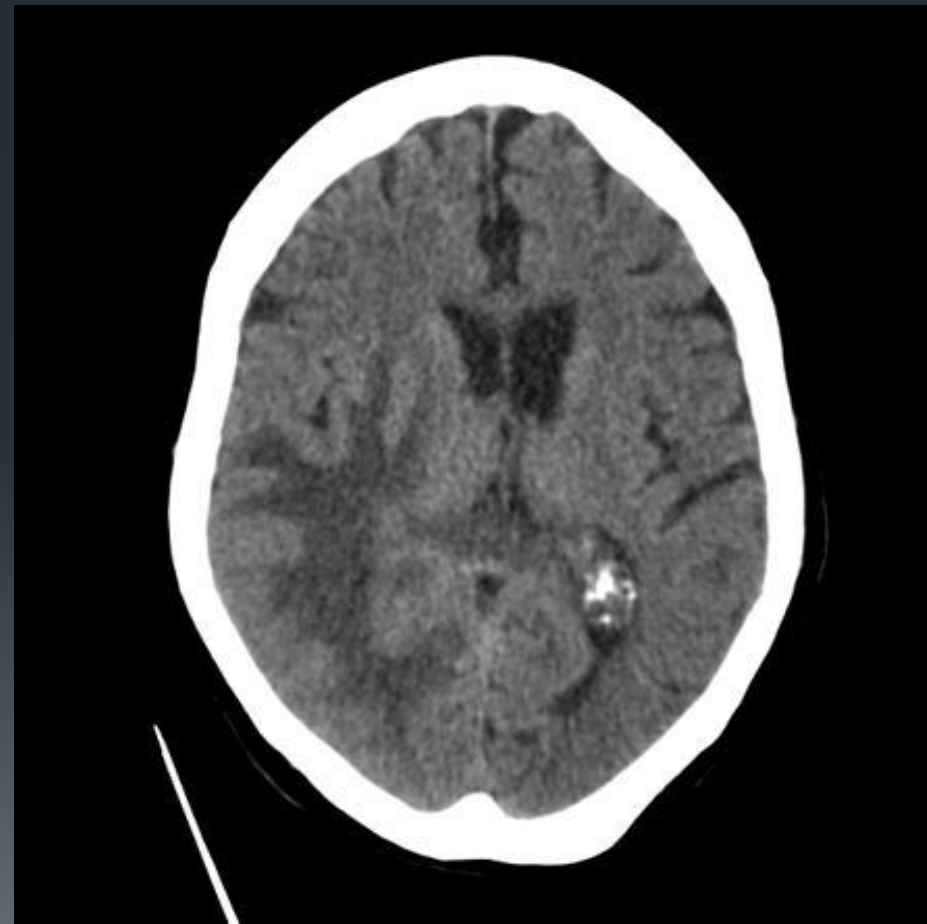- ICH



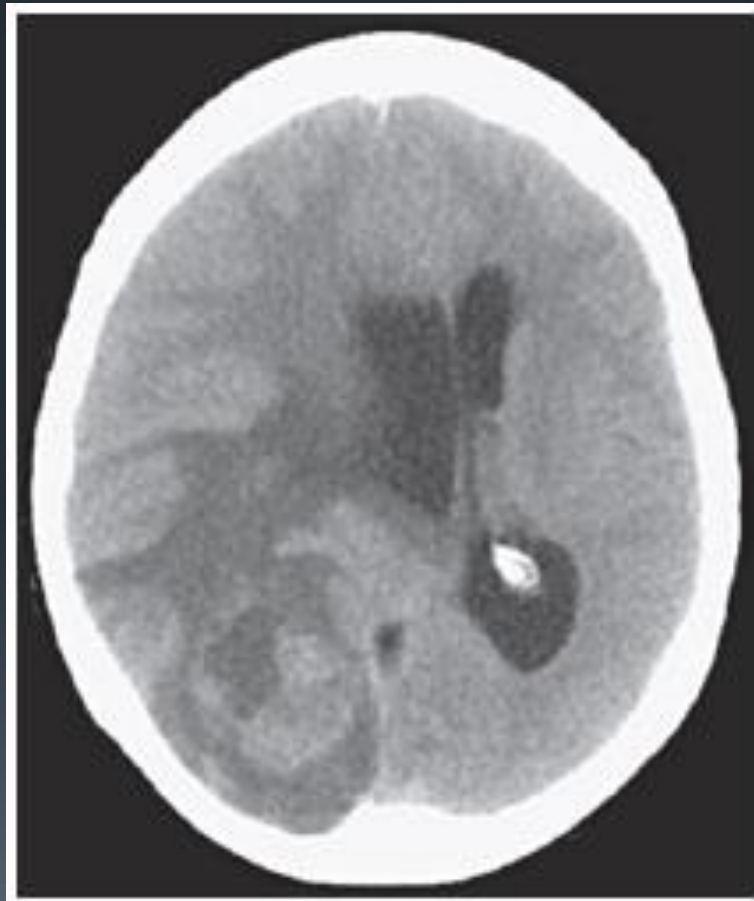
Brain CT Scan Reading...

Brain

- Vasogenic Edema



- Vasogenic Edema

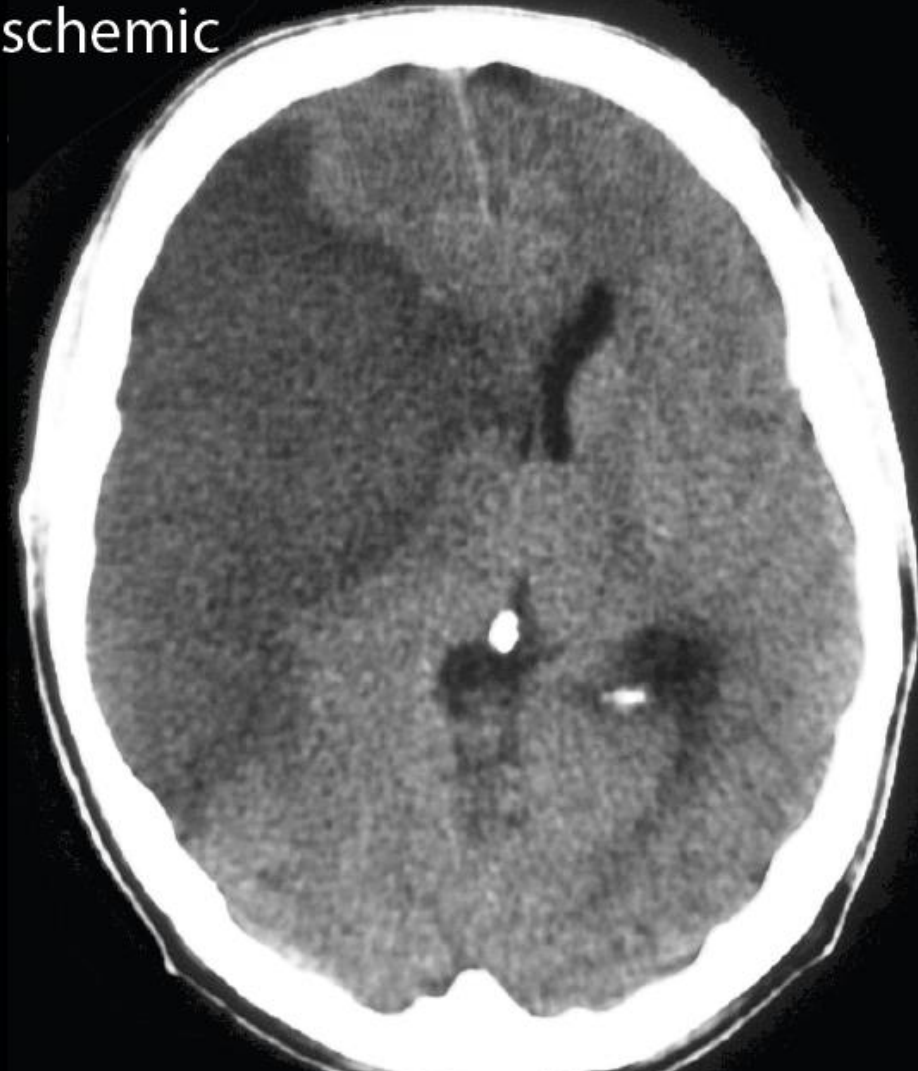

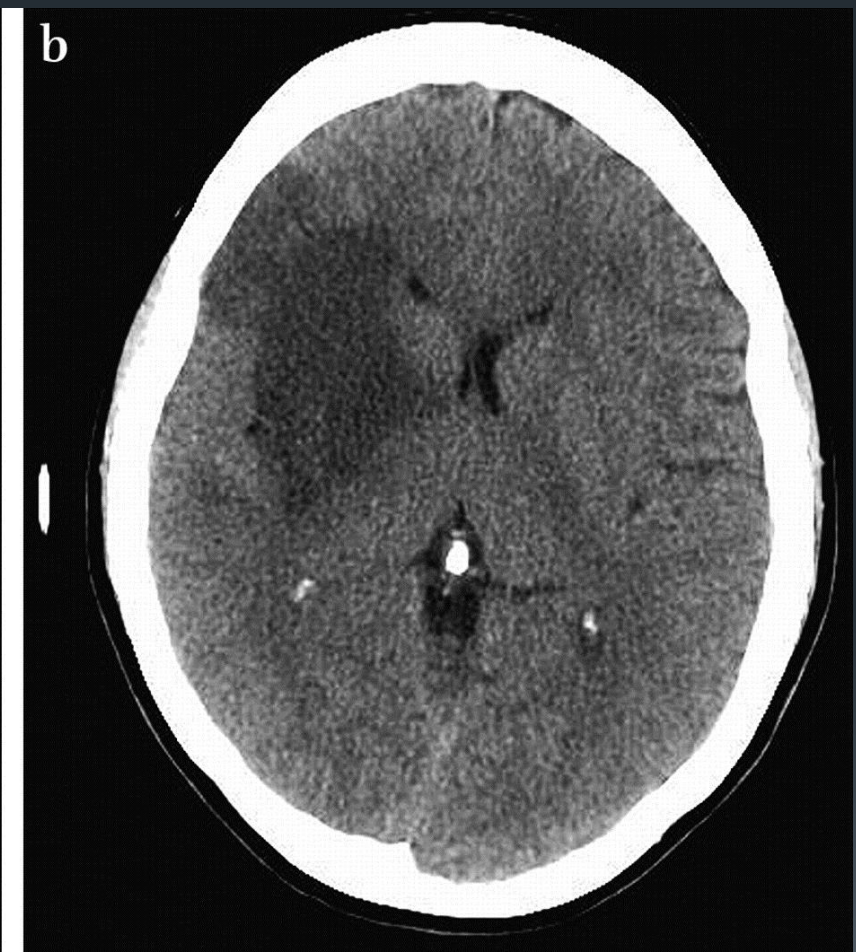
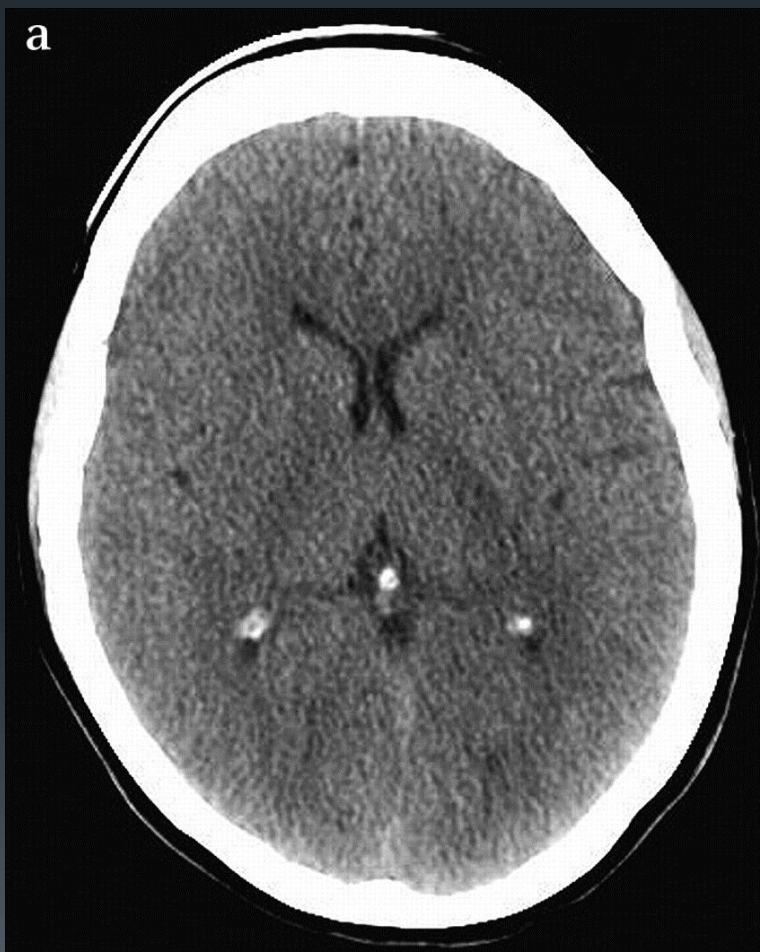Brain CT Scan Reading...

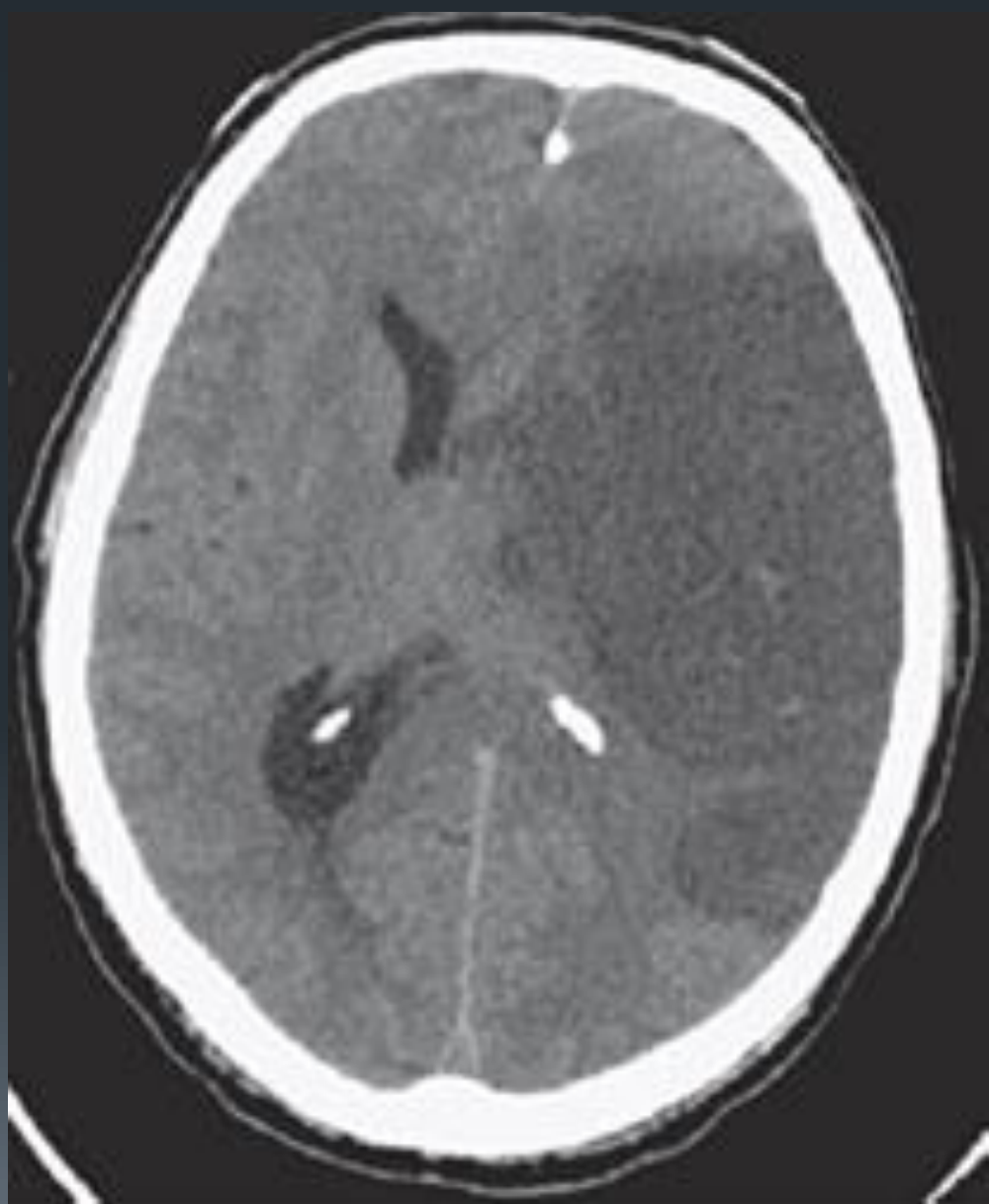
Brain

- Ischemic Stroke
(with ischemic edema)

ischemic



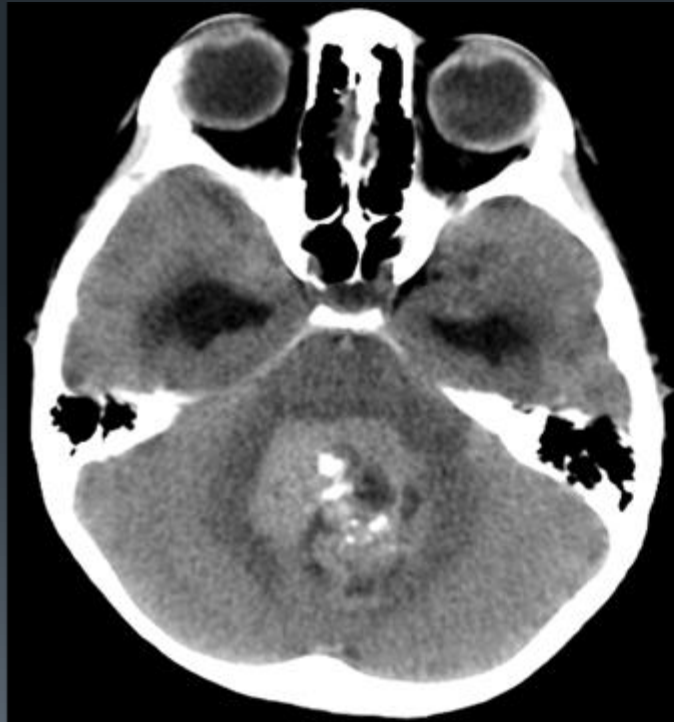



Brain CT Scan Reading...

Brain

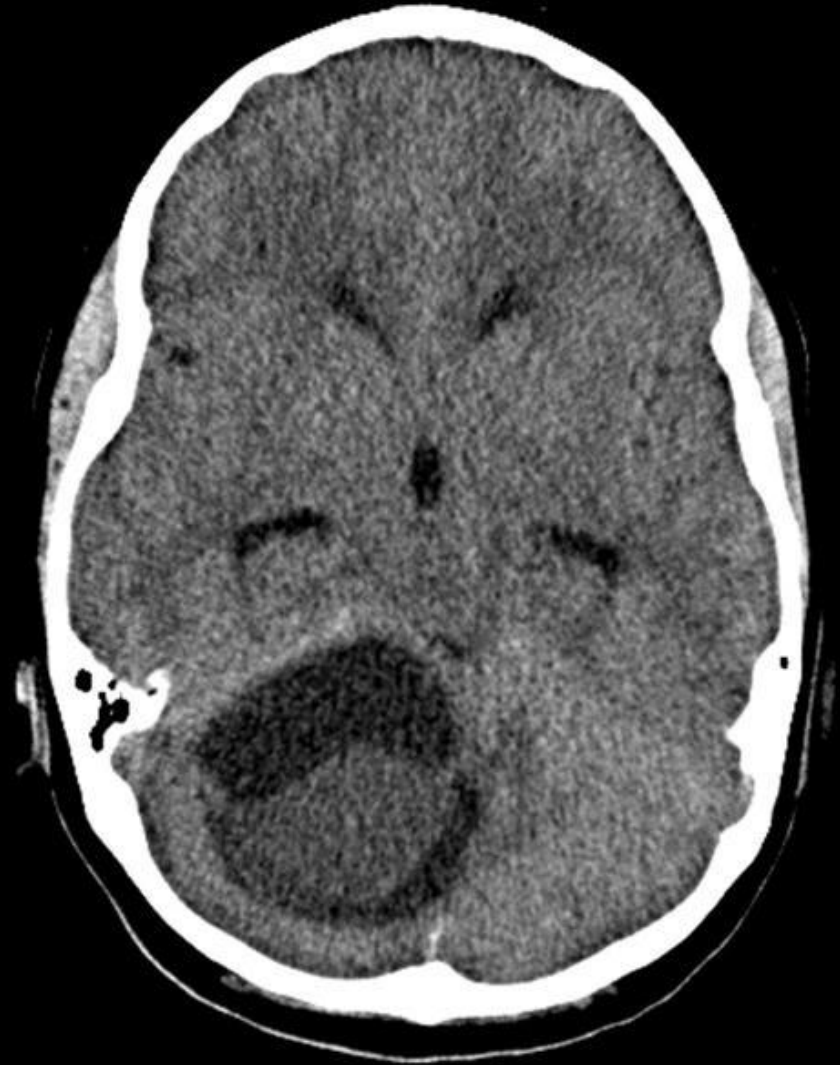- Tumors



Brain CT Scan Reading...

Brain

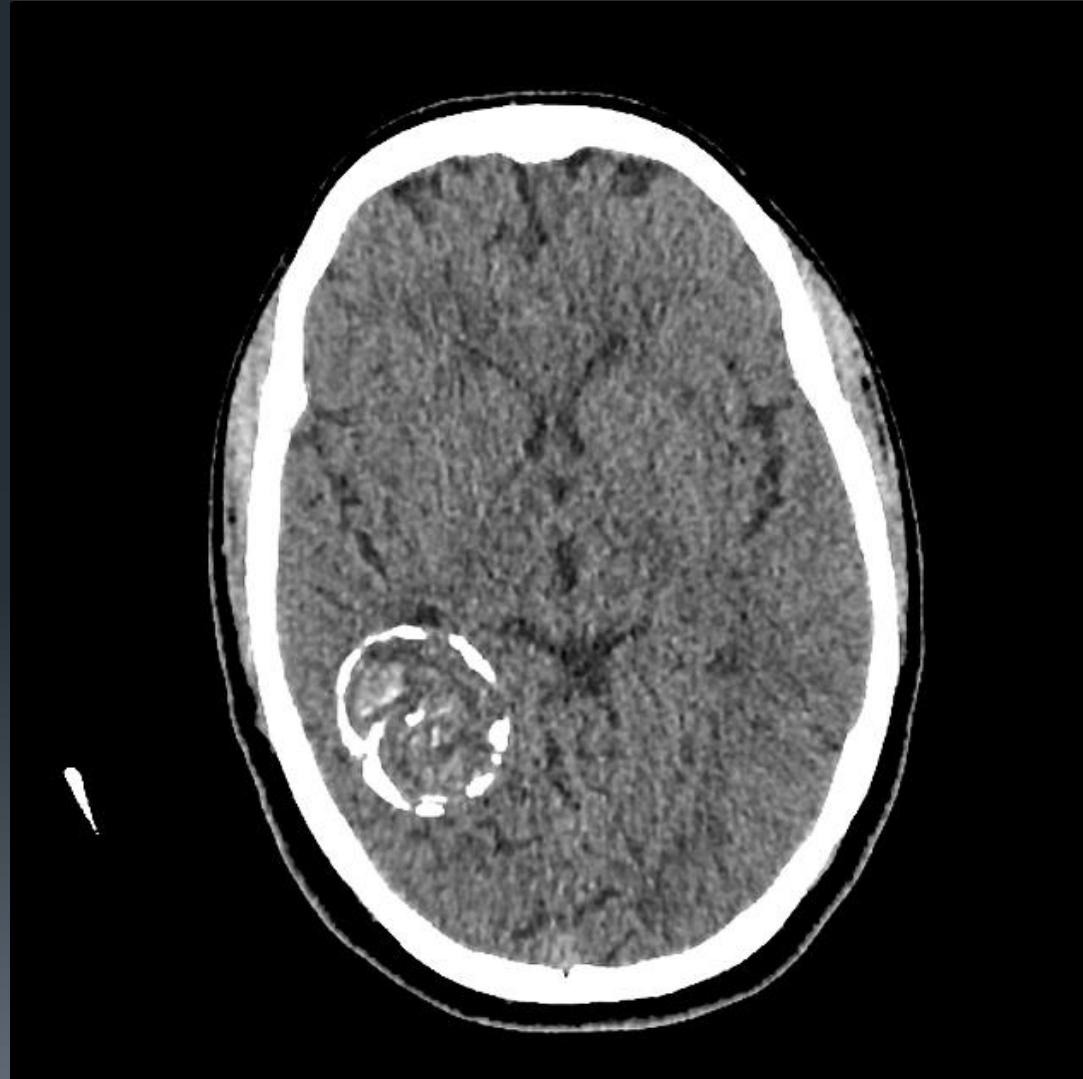- Tumors



Brain CT Scan Reading...

Brain

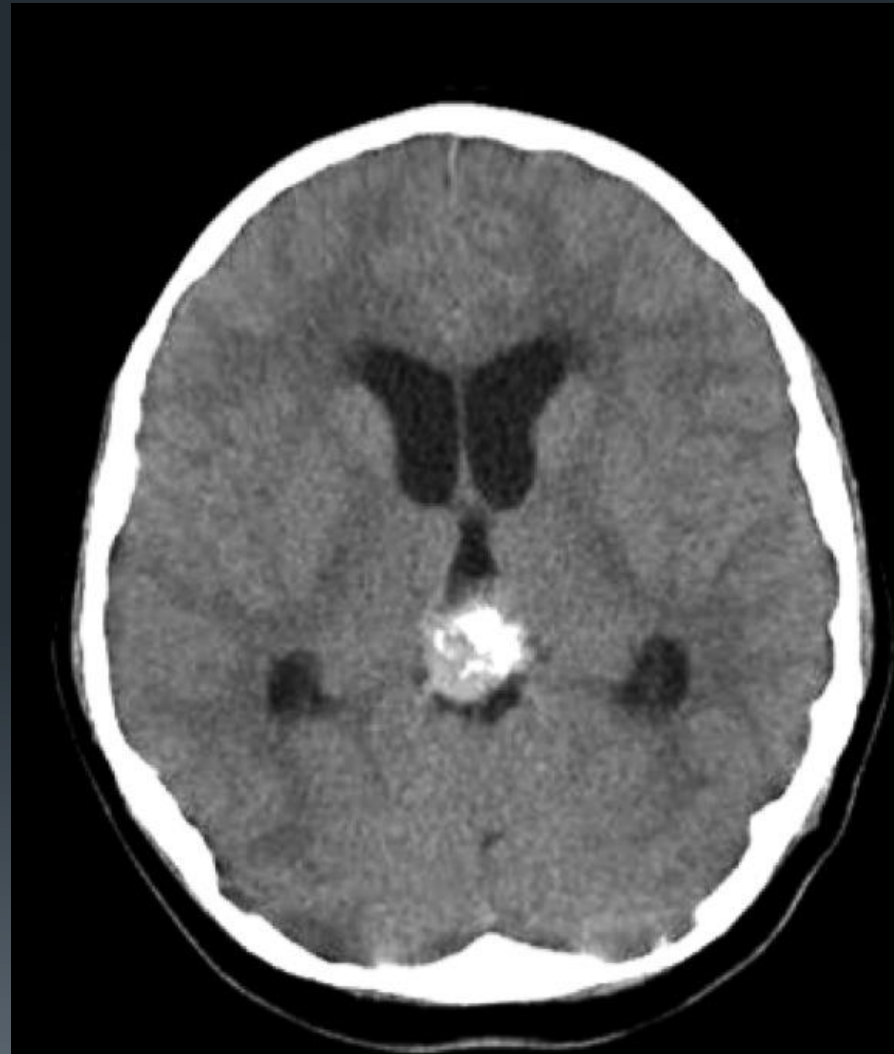- Tumors



Brain CT Scan Reading...

Brain

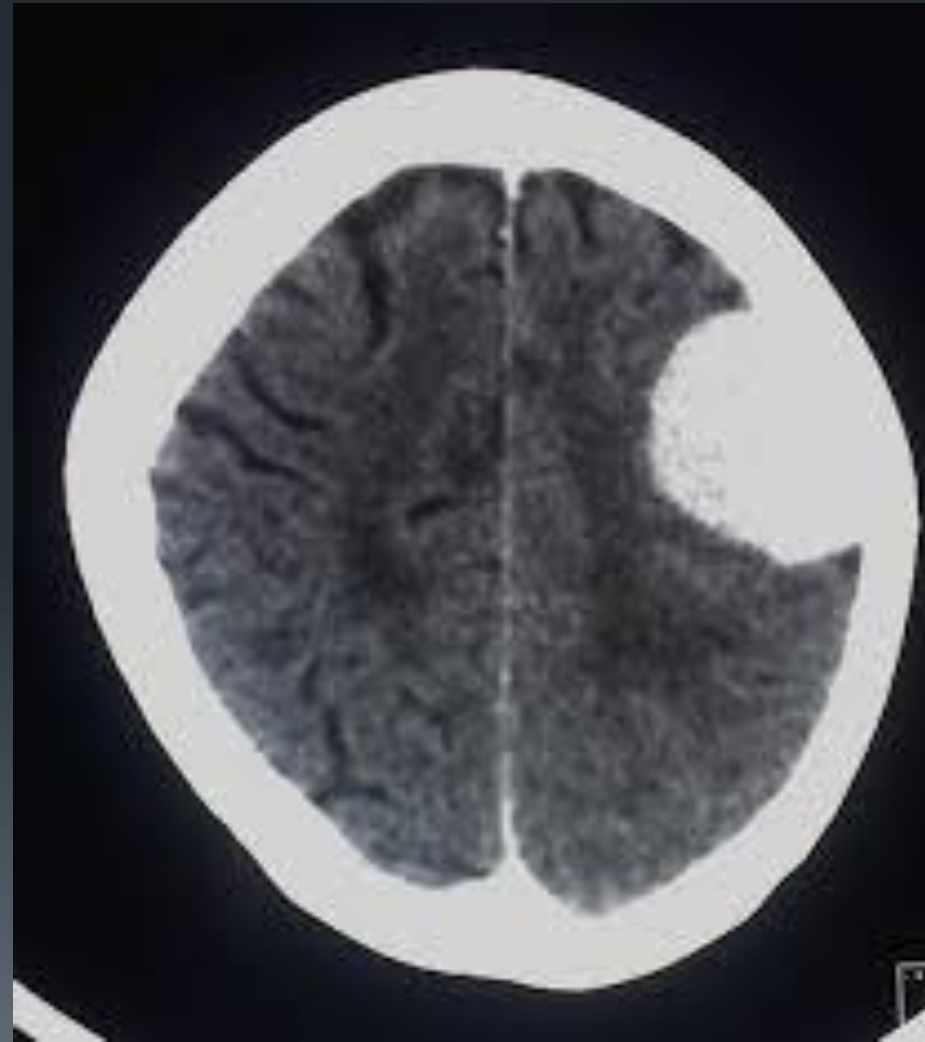
- Tumors



Brain CT Scan Reading...

Brain

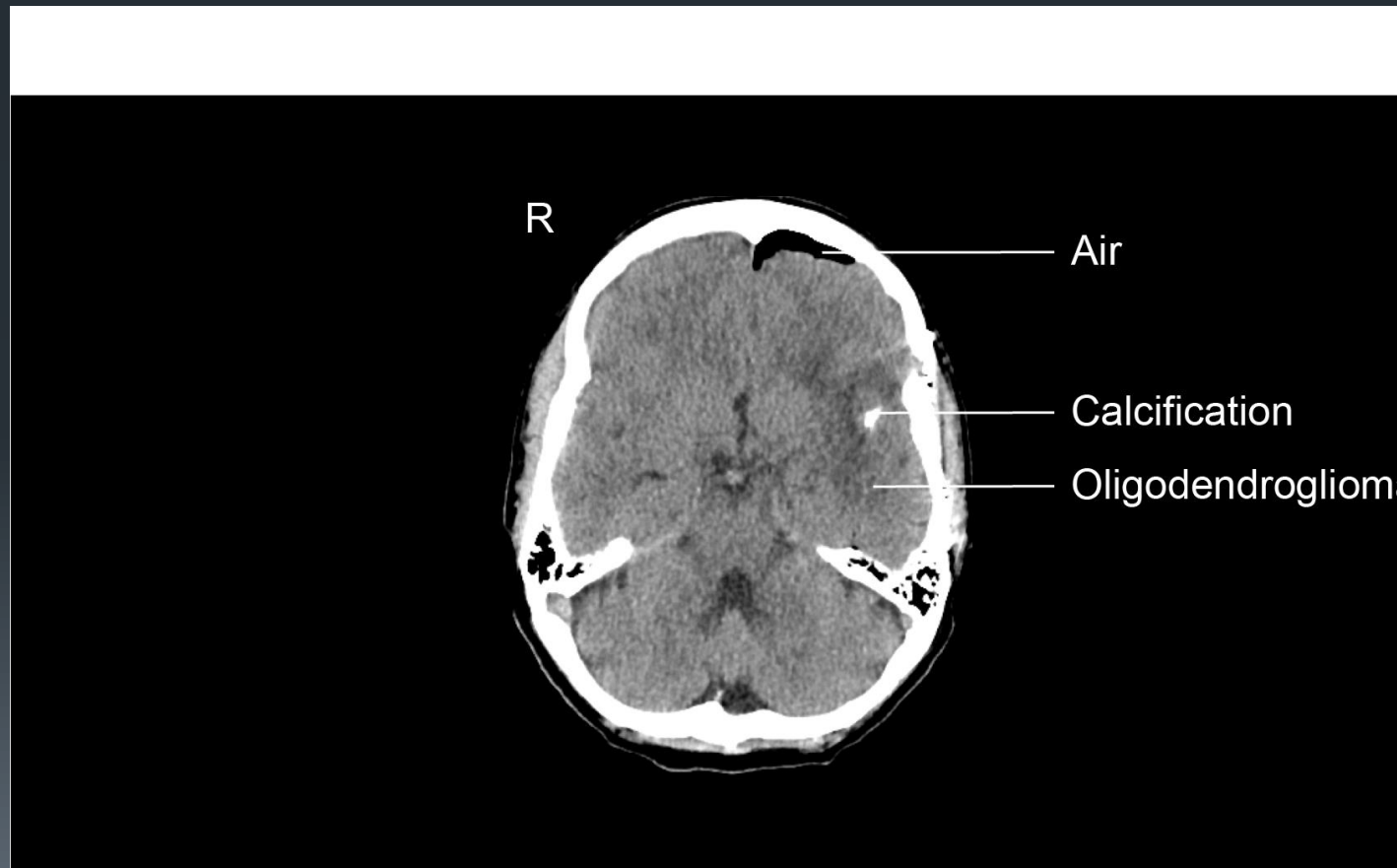
- Tumors



Brain CT Scan Reading...

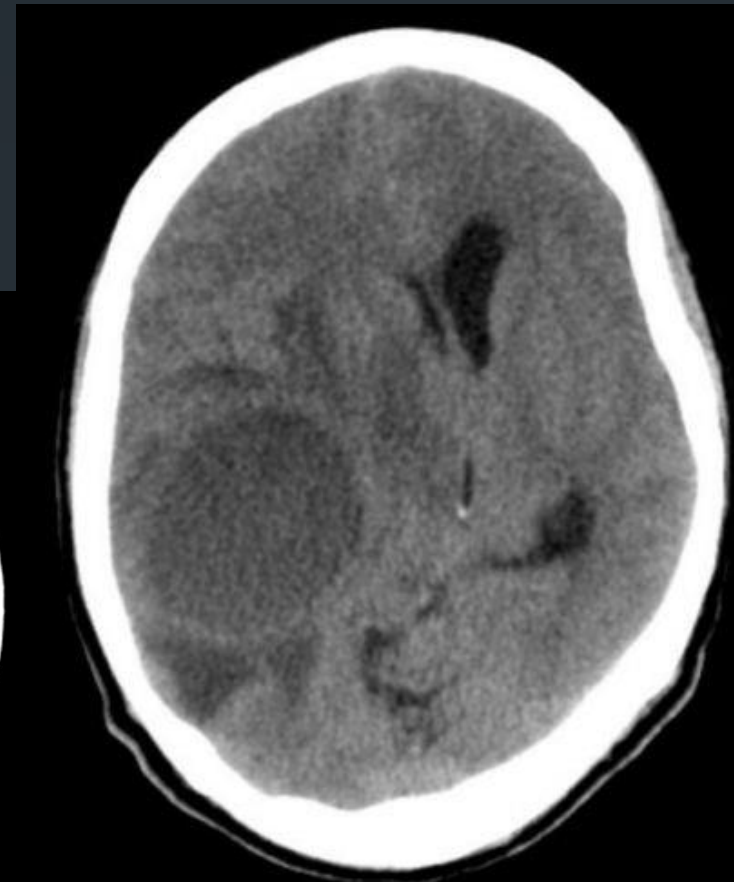
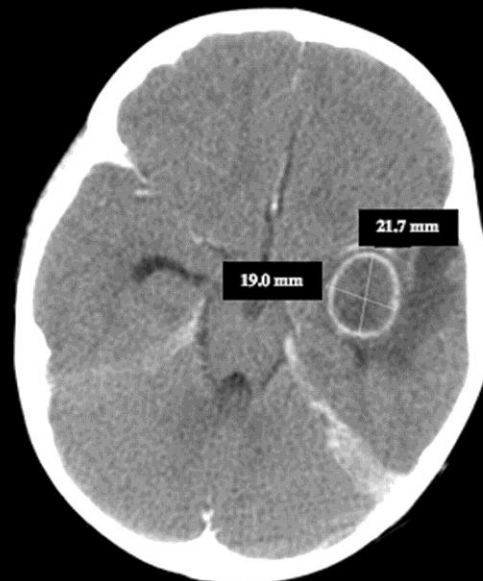
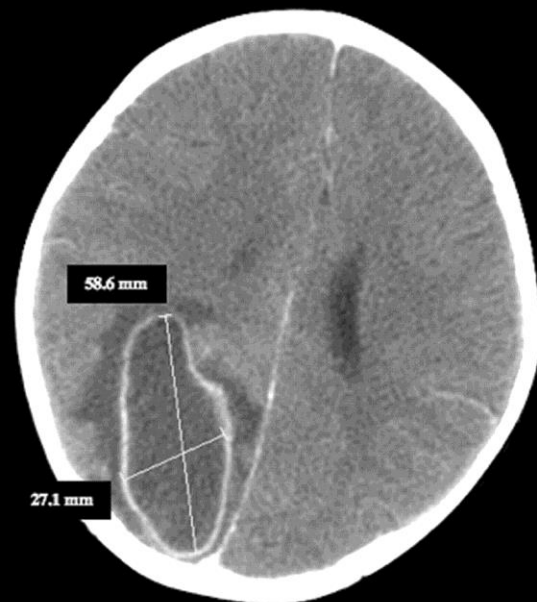Brain

- Tumor



Brain CT Scan Reading...

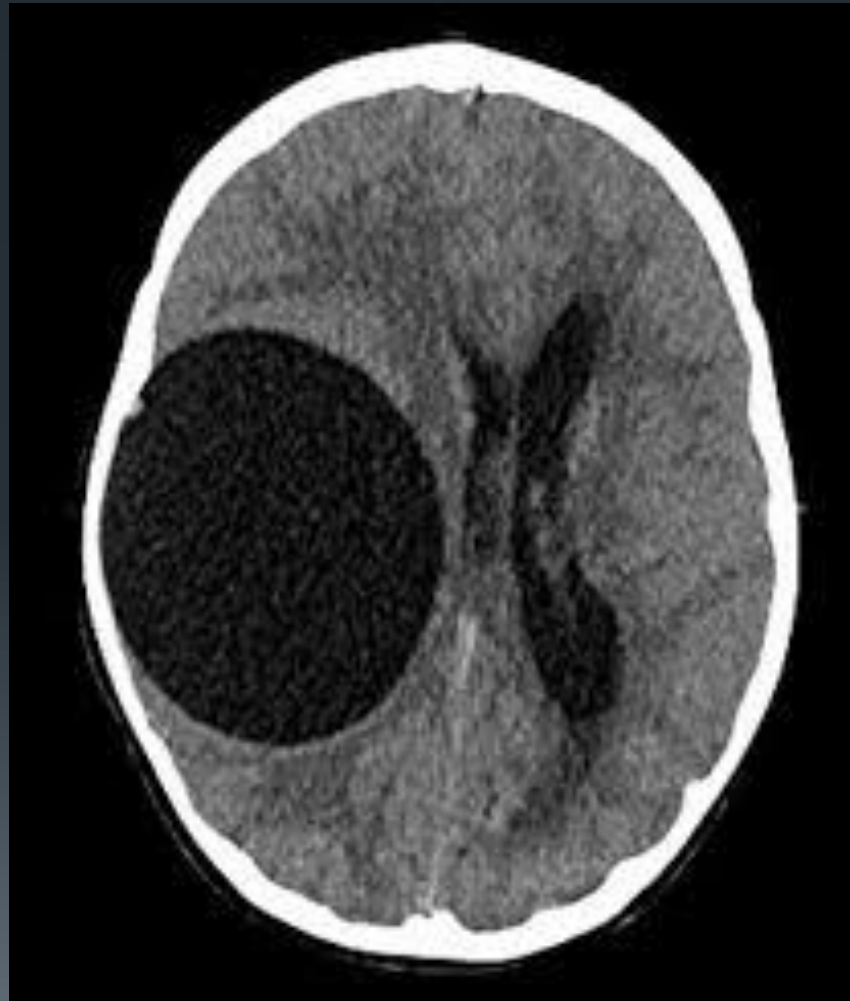
- Abscess



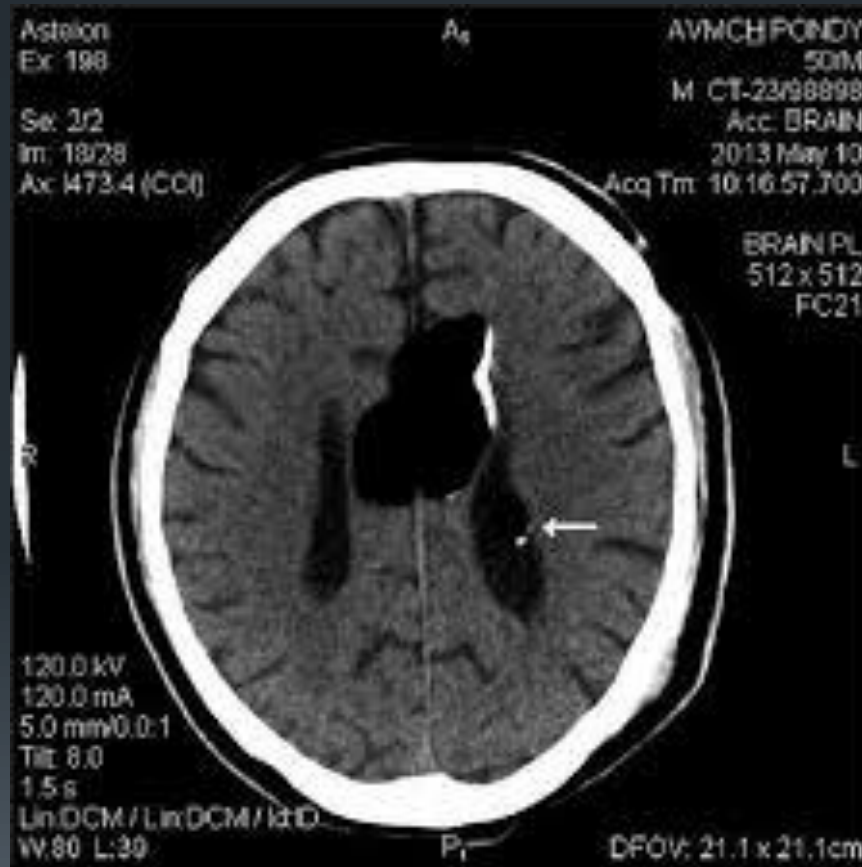
Brain CT Scan Reading...

Brain

- Cyst

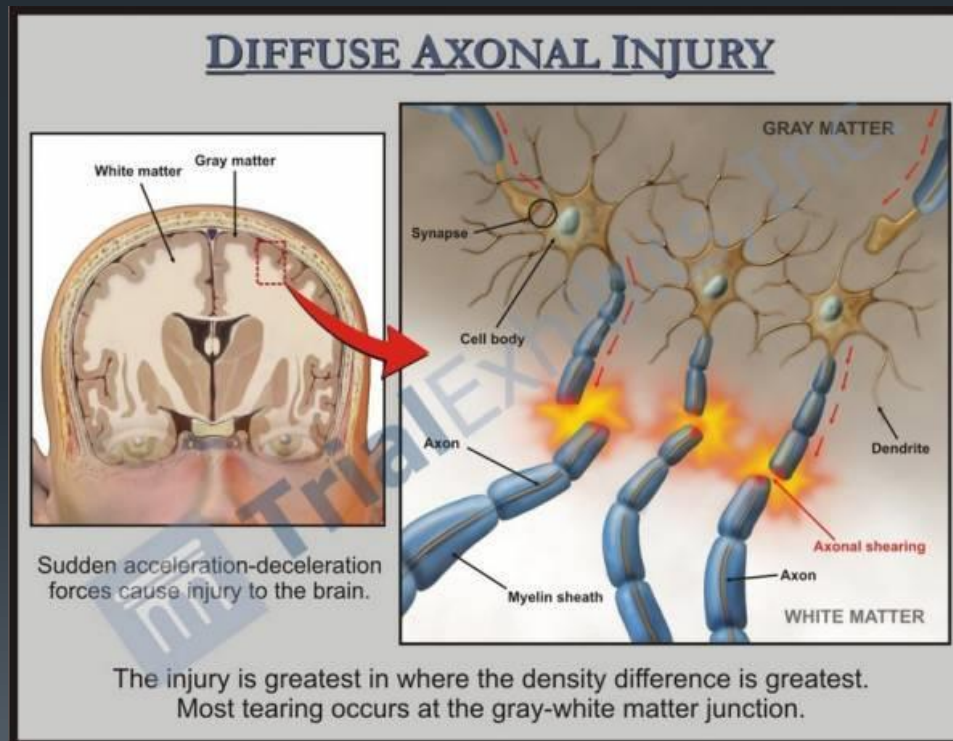


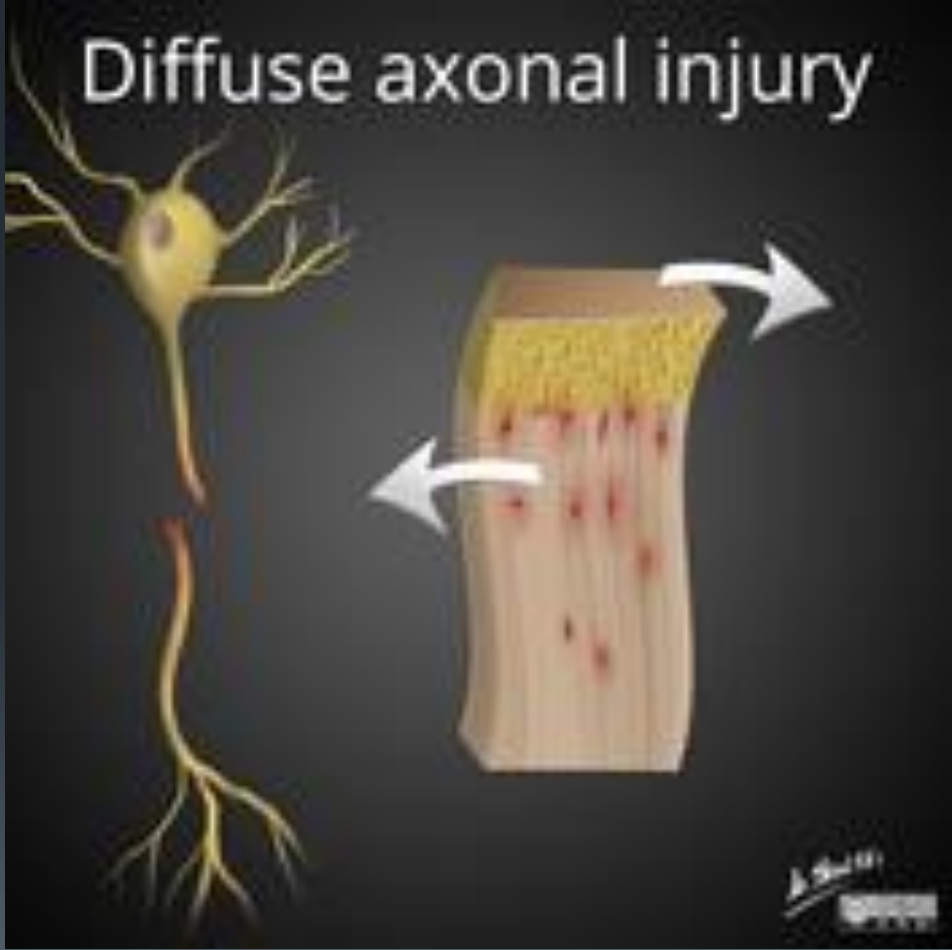lipoma

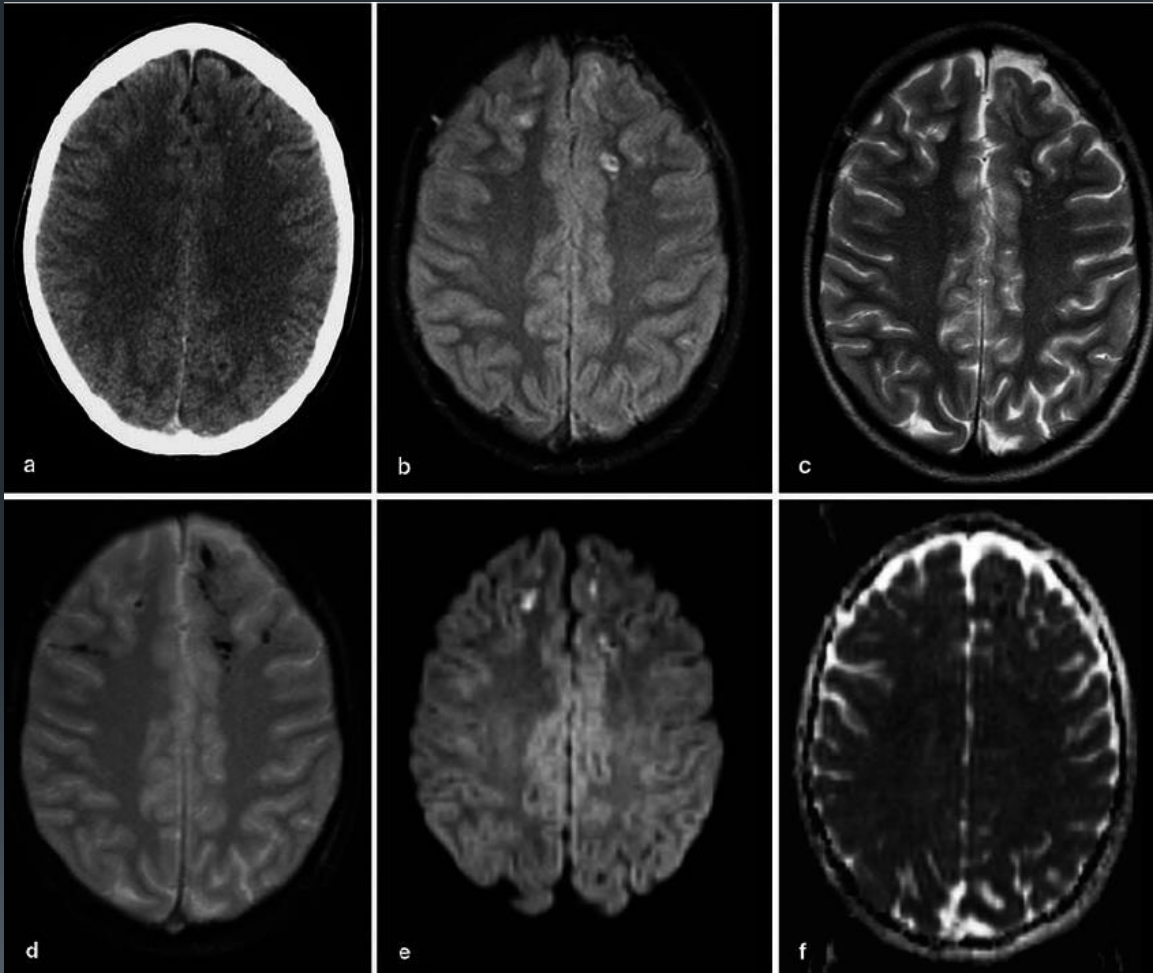


Brain CT Scan Reading...

Brain

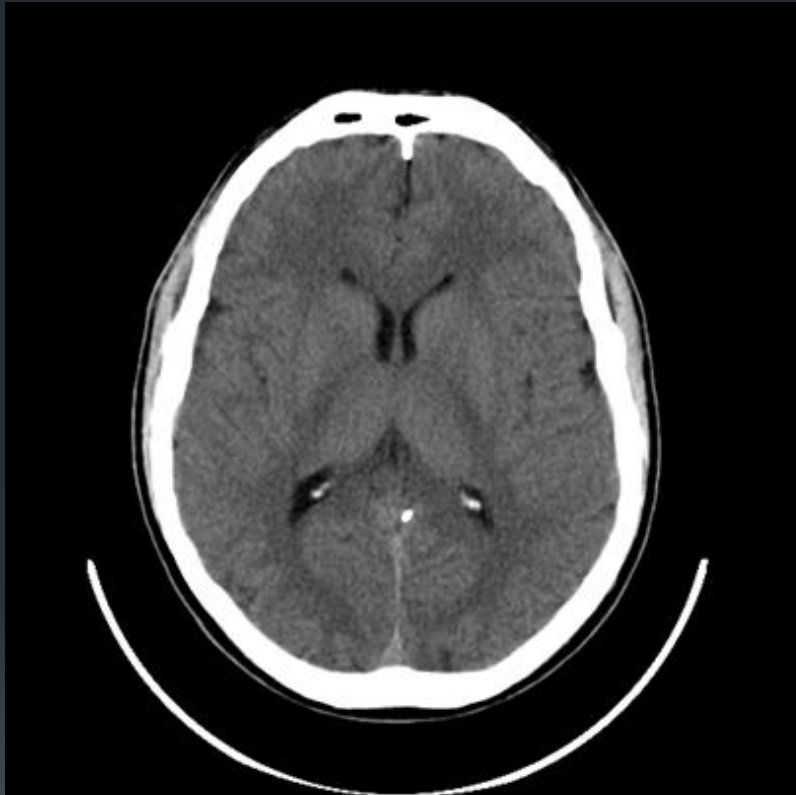




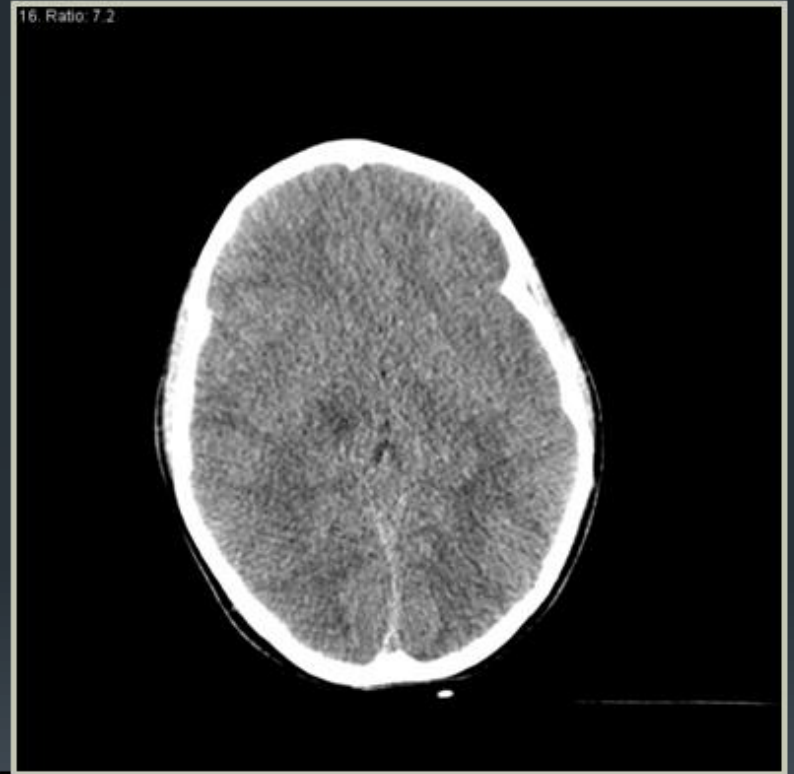
Brain CT Scan Reading...

Brain



Normal CT



Diffuse Injury

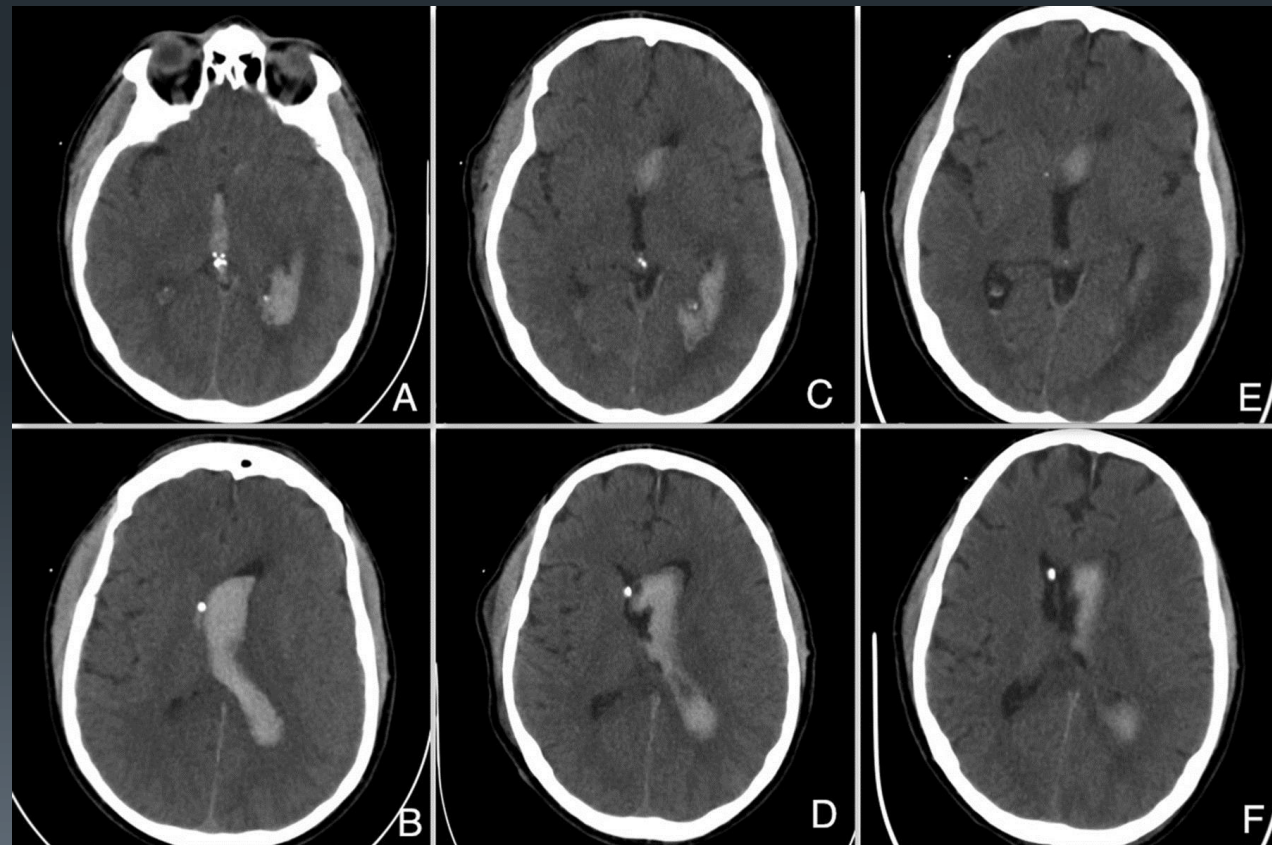


Ventricle

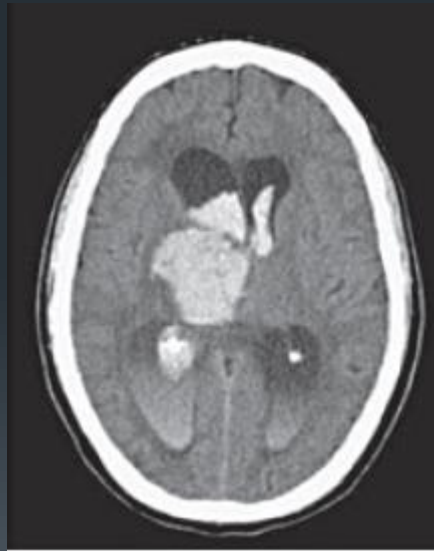Brain CT Scan Reading...

Ventricles

- IVH



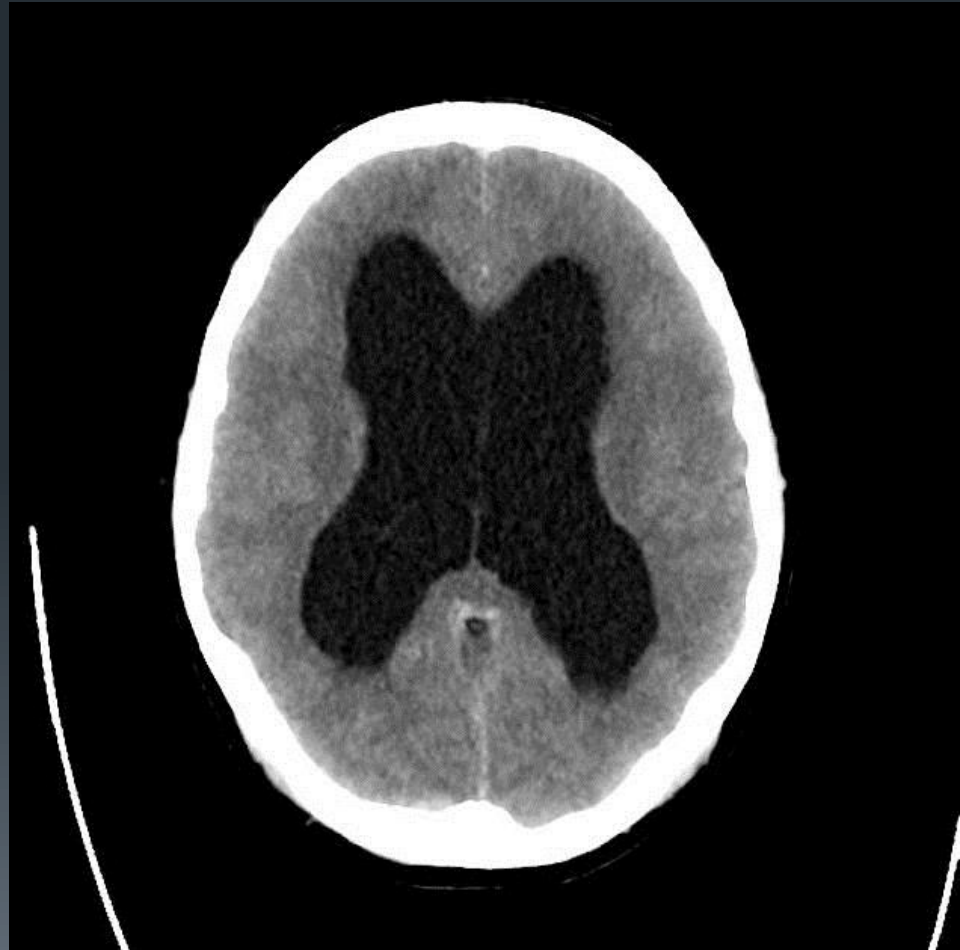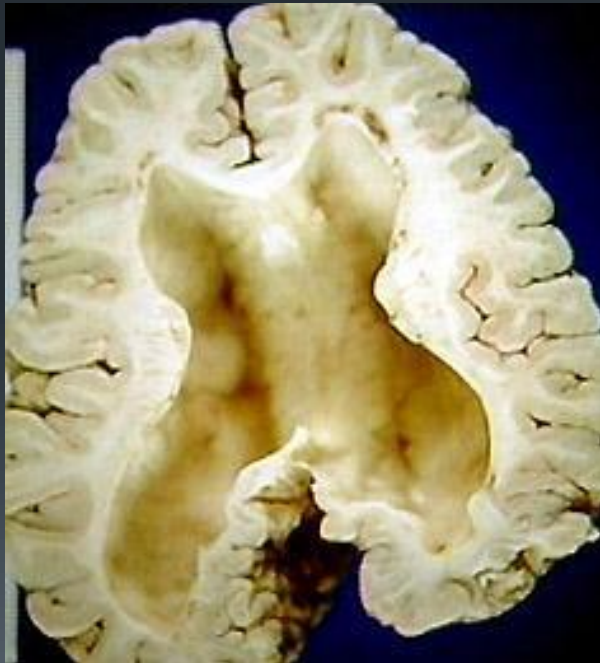ICH & IVH

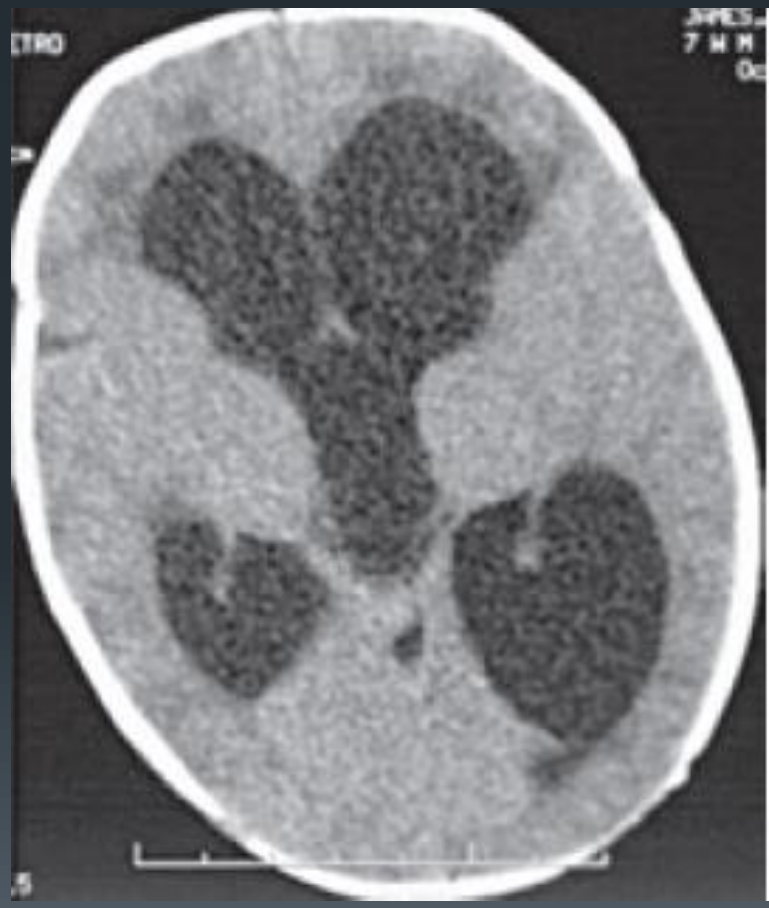

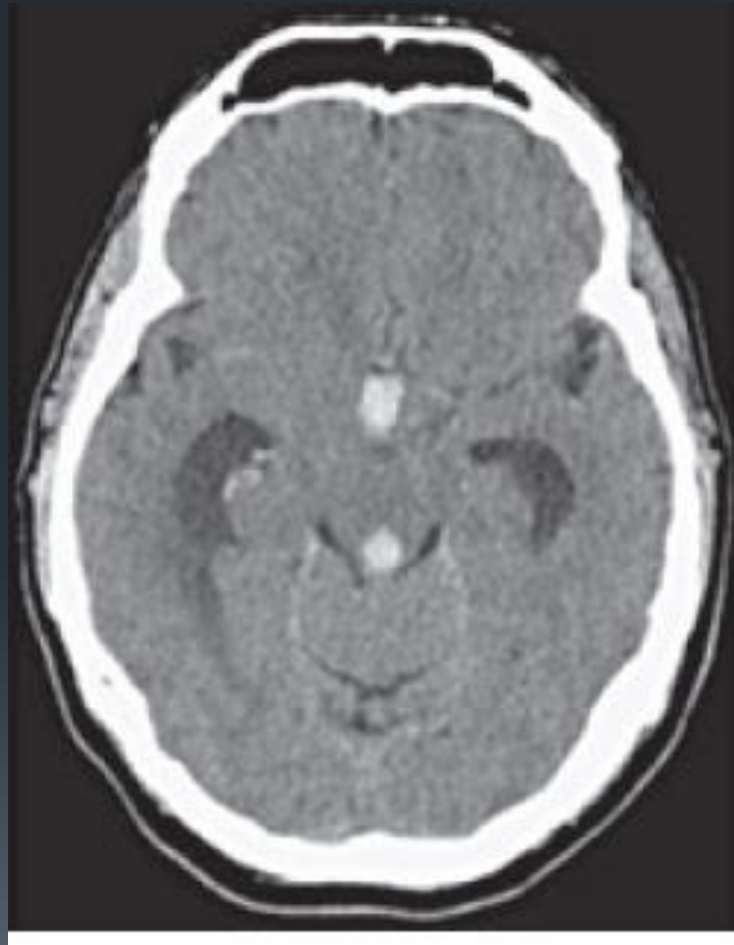Brain CT Scan Reading...

Ventricles

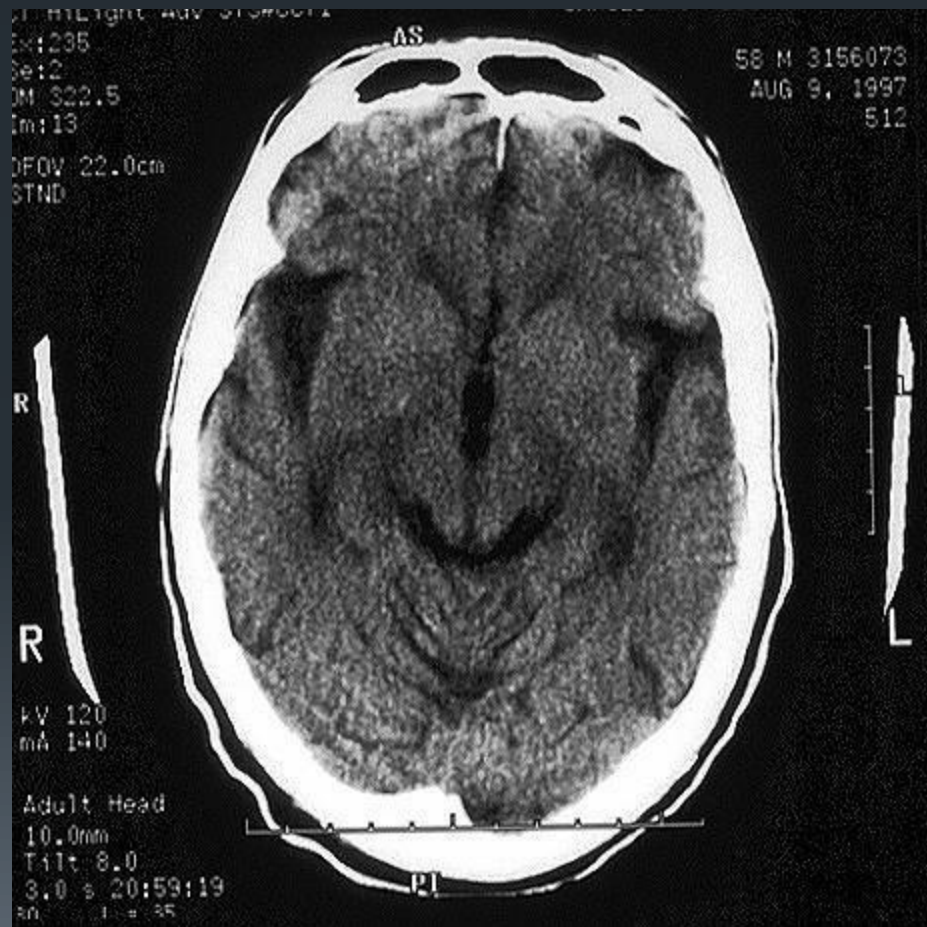
- Hydrocephalus



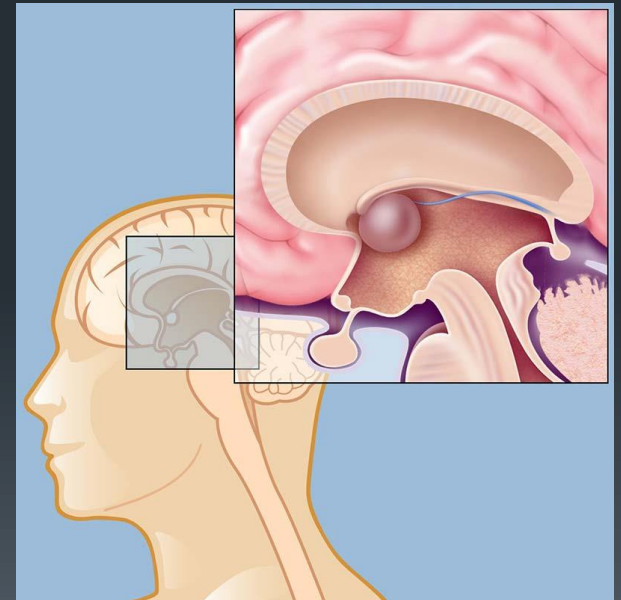
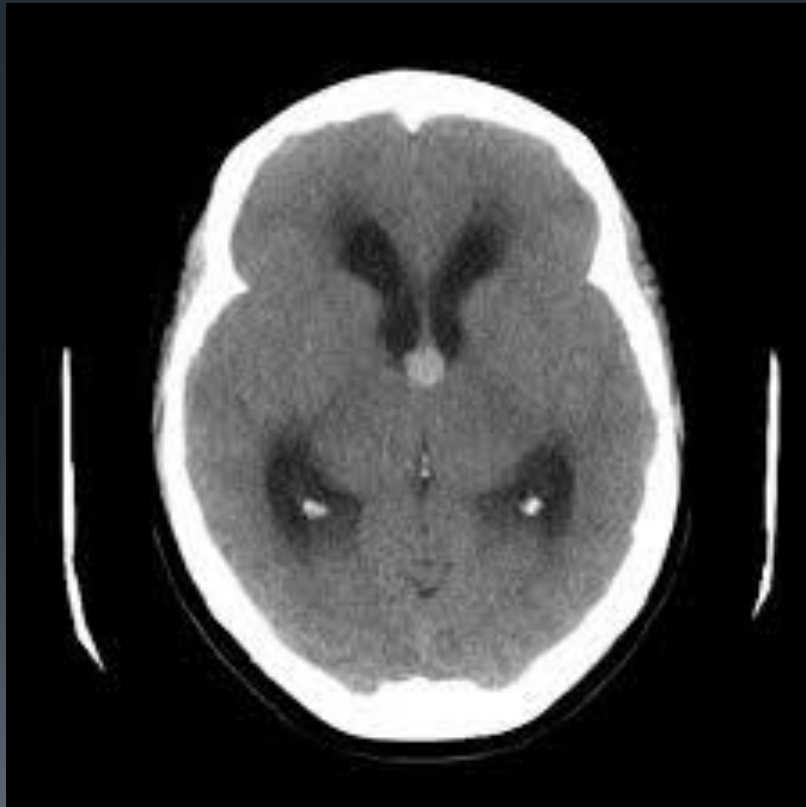




- Brain Atrophy



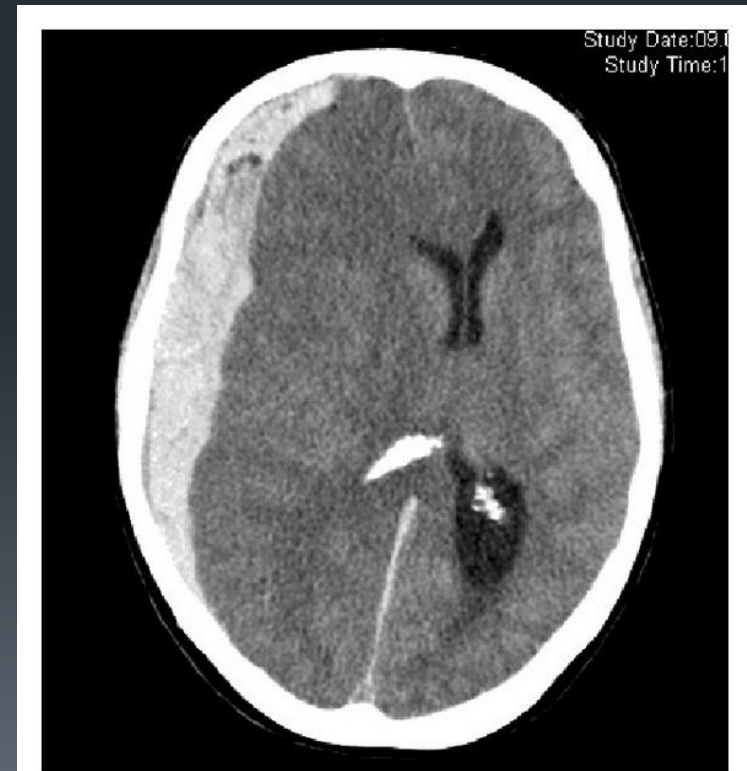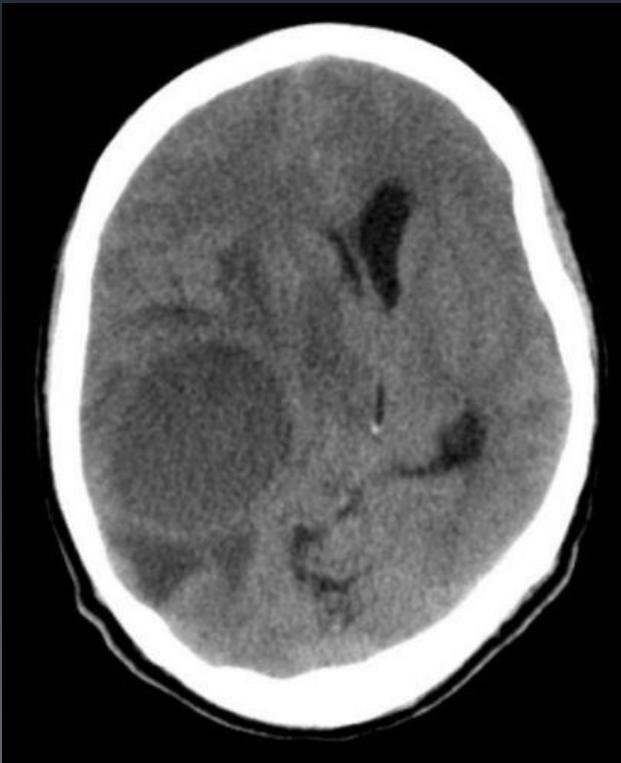
Colloid Cyst



Brain CT Scan Reading...

Ventricles

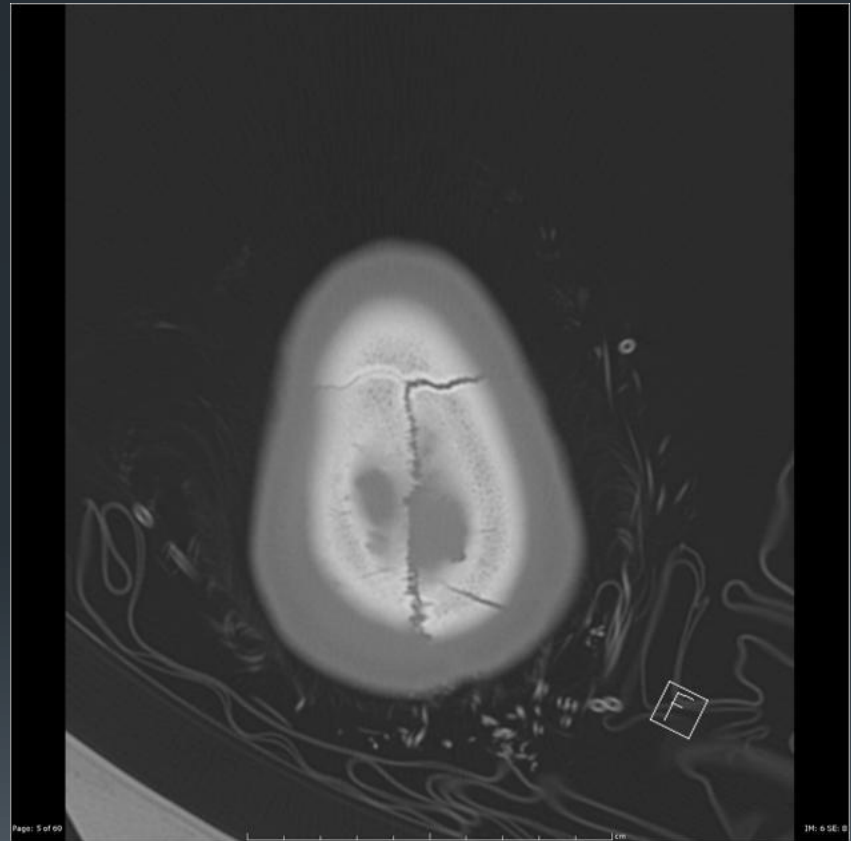
- Compression and Shifting



Brain CT Scan Reading...

Bone , Skull Sutures

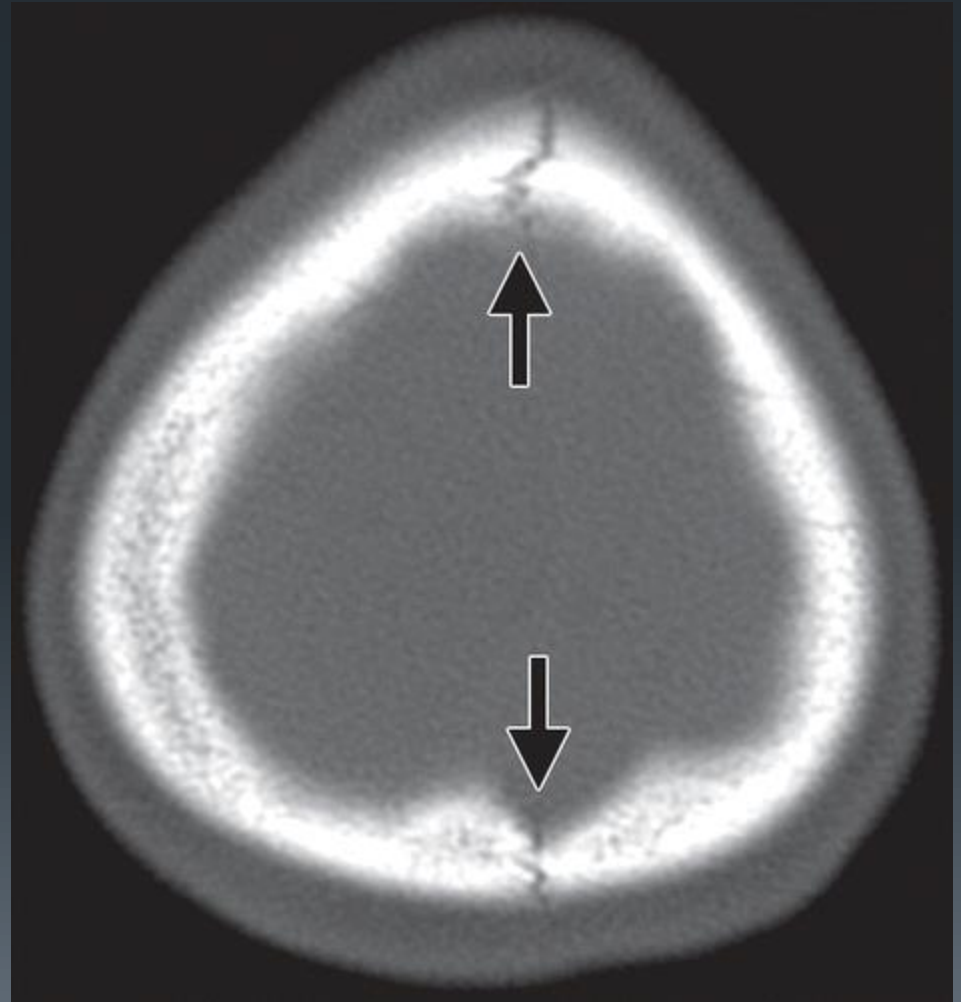
- Coronal S.



Brain CT Scan Reading...

Bone Skull Sutures

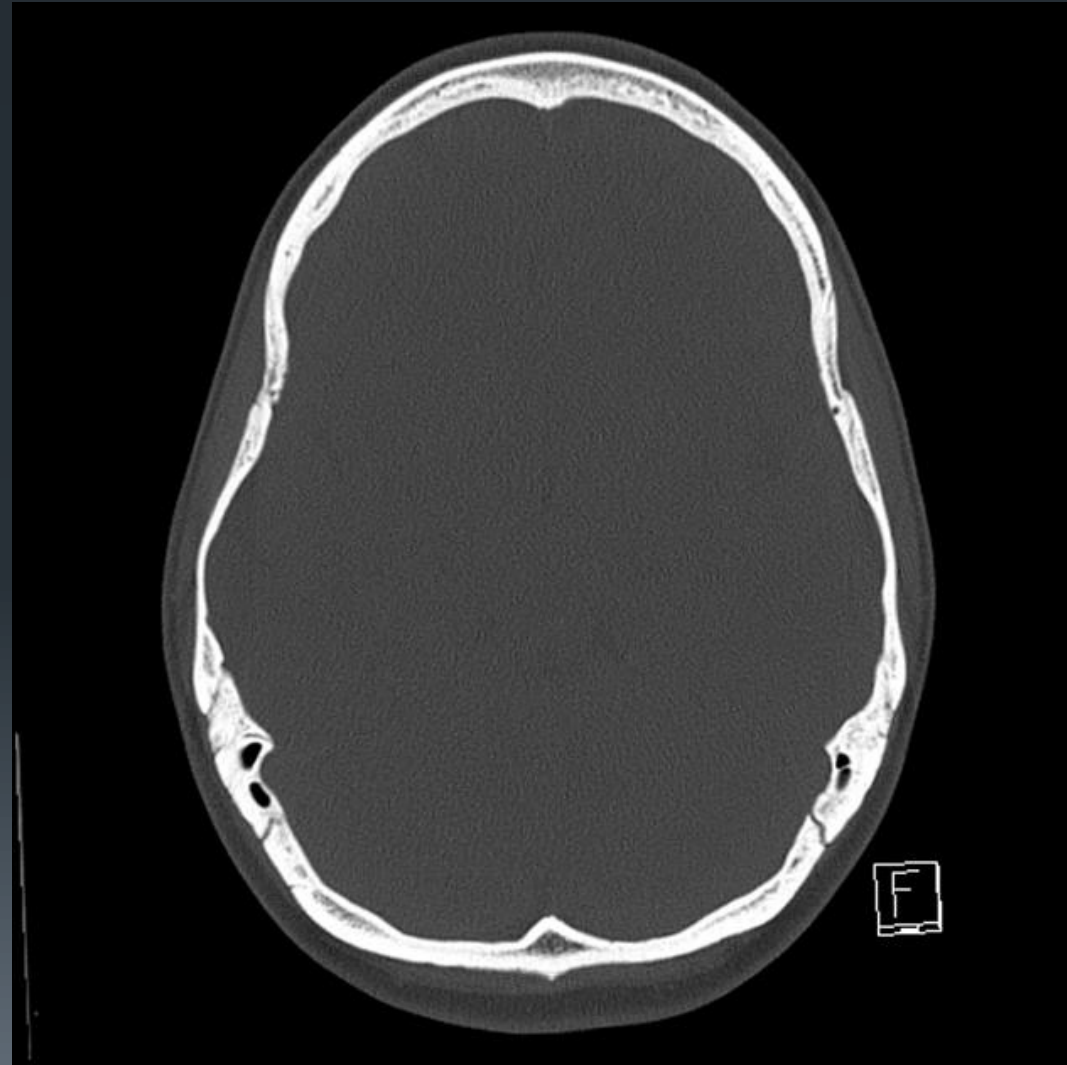- Sagittal S.

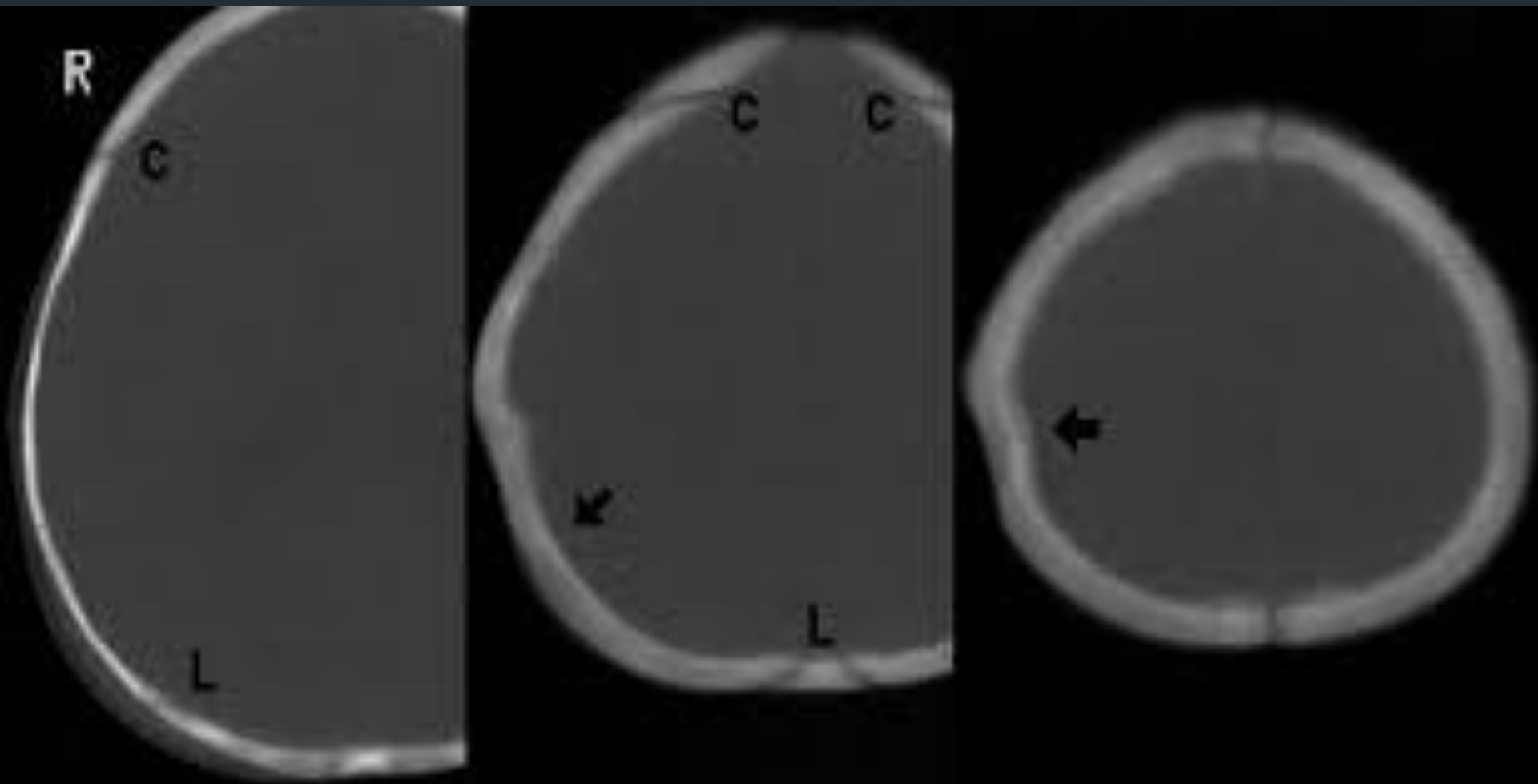


Brain CT Scan Reading...

Bone Skull Sutures

- Lambdoid S.

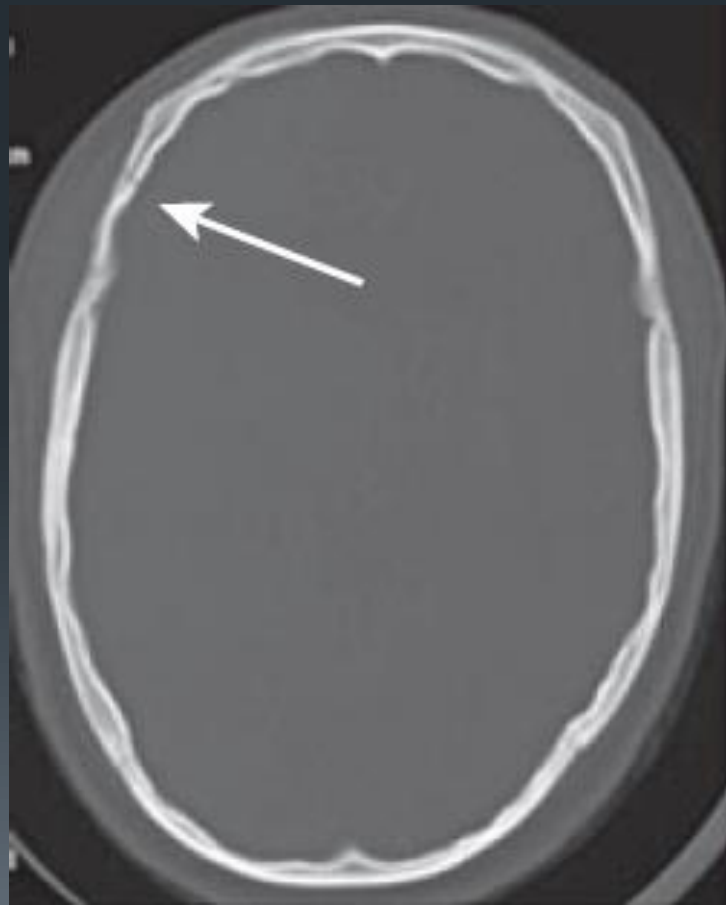




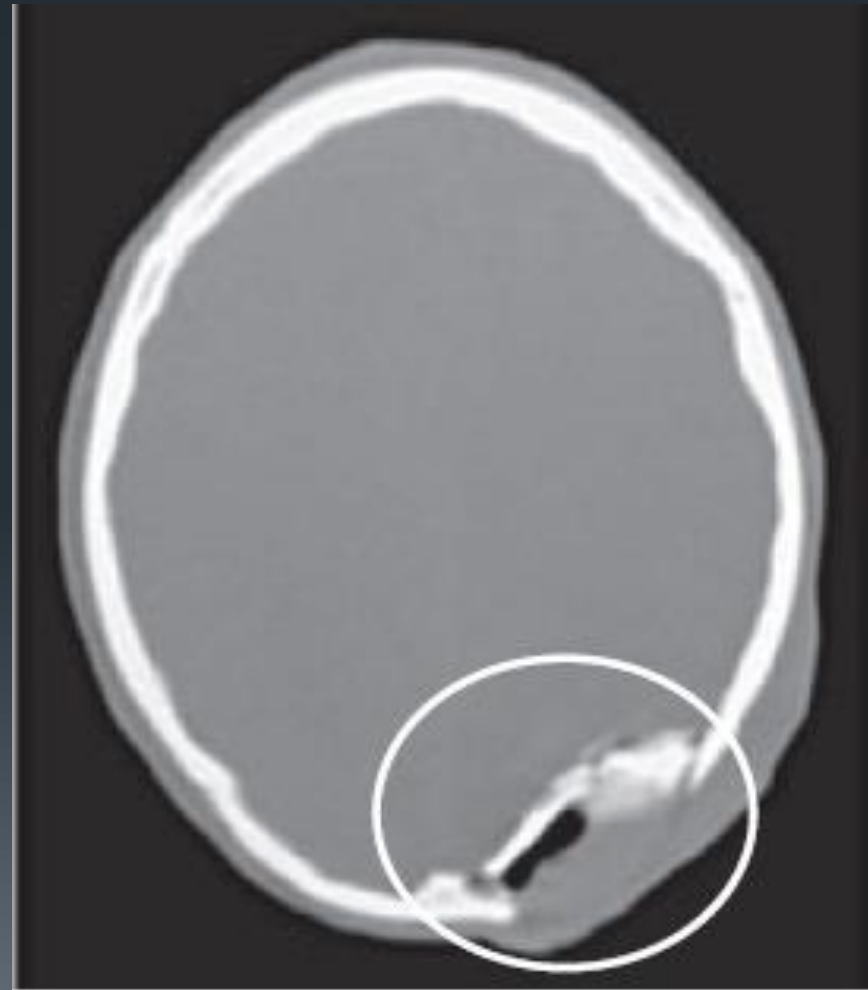
Brain CT Scan Reading...

Bone

- Linear skull Fractures



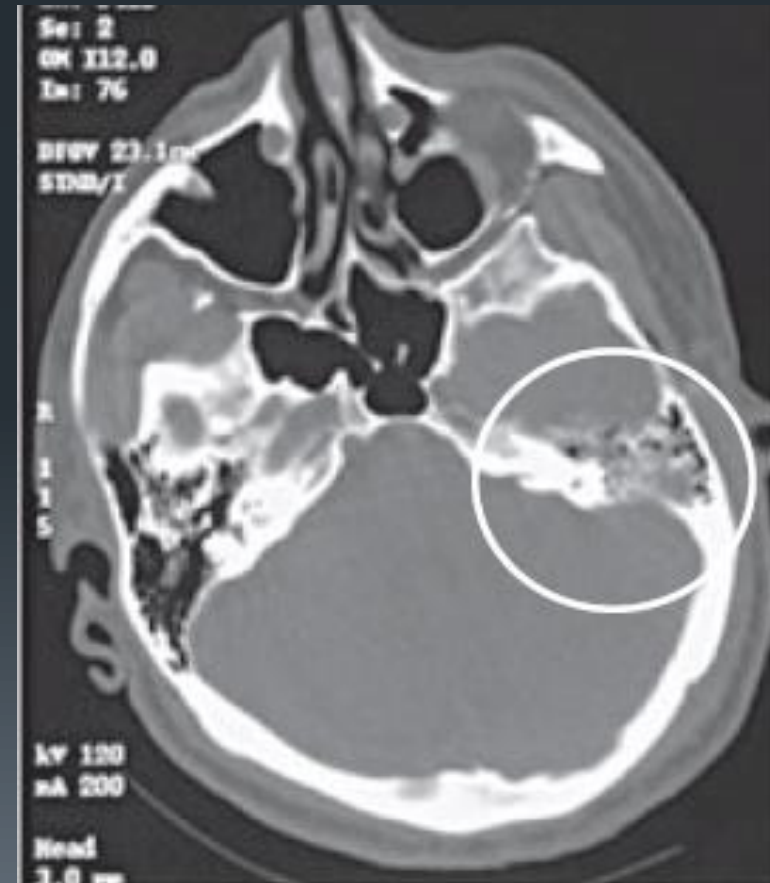
- Depressed Skull Fracture

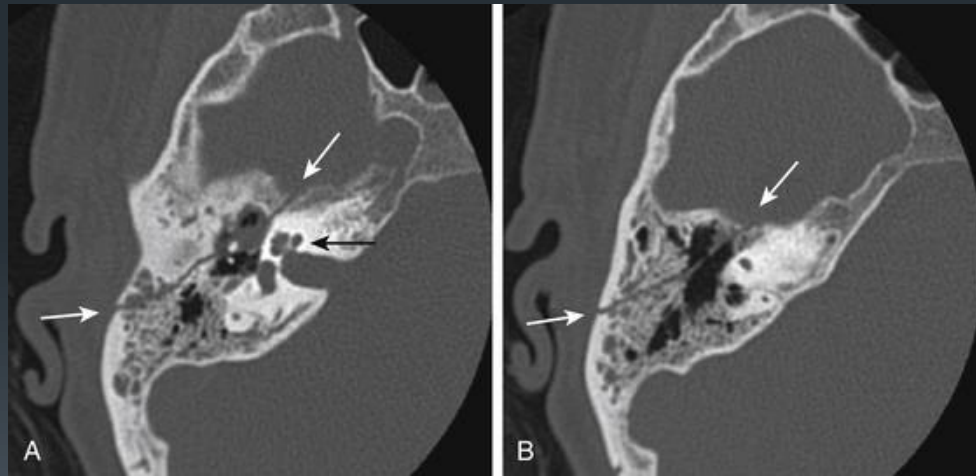


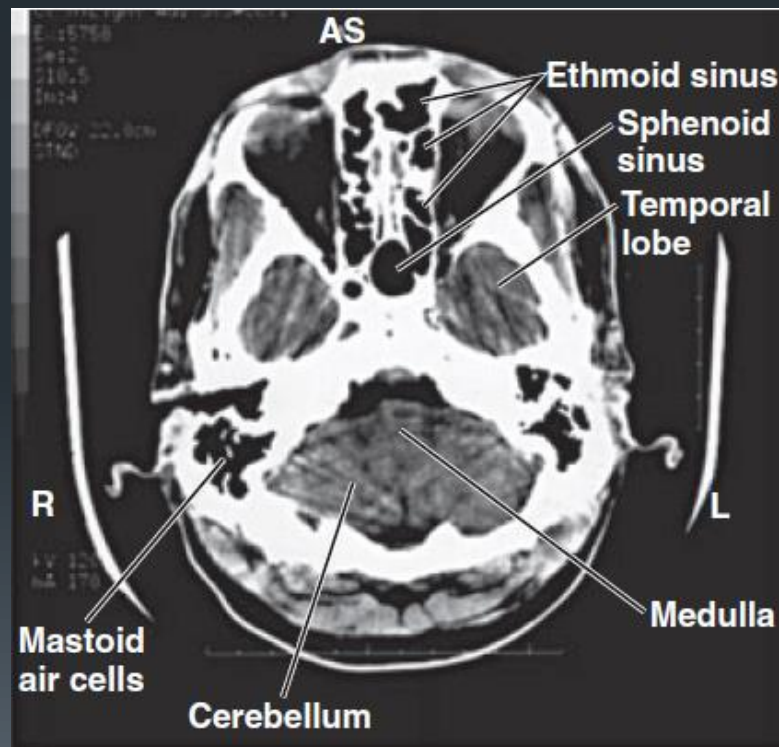
Brain CT Scan Reading...

Bone

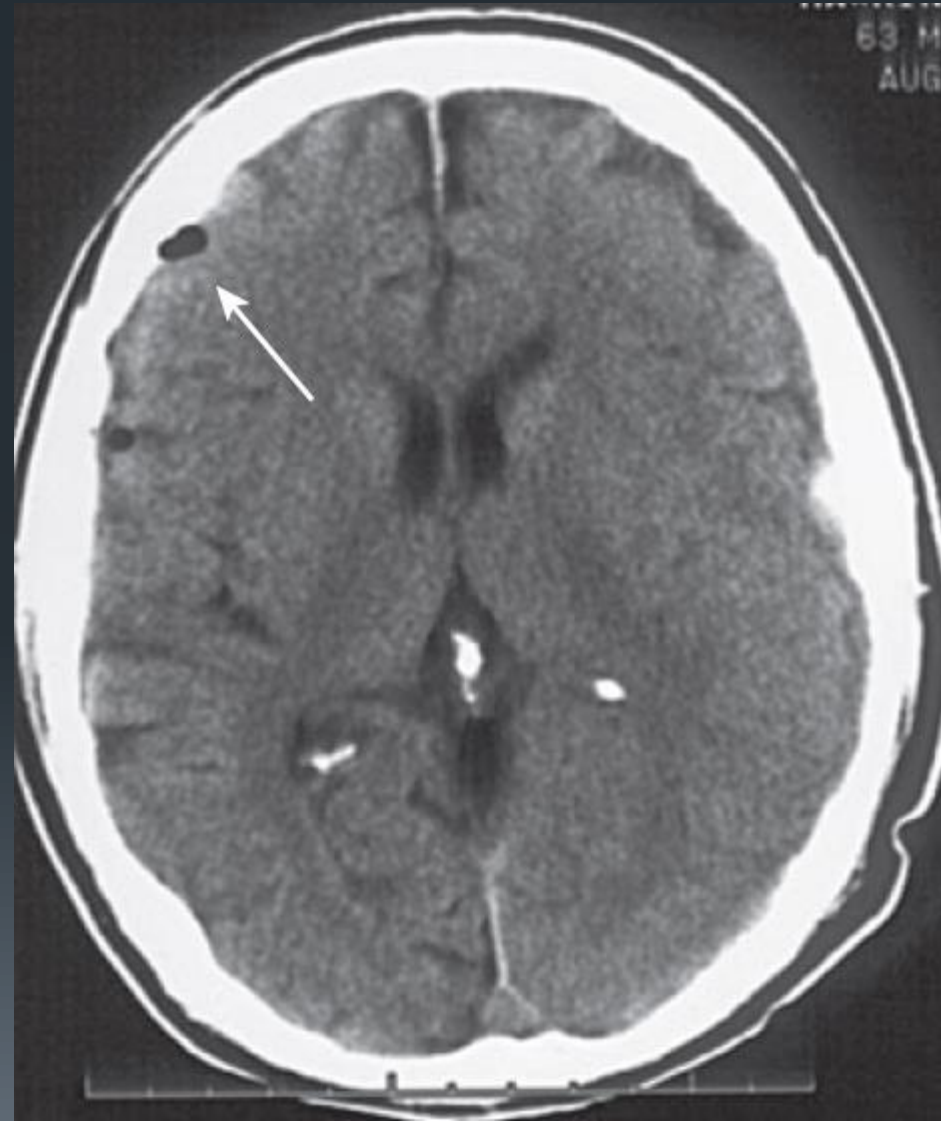
- Fractures of Skull base





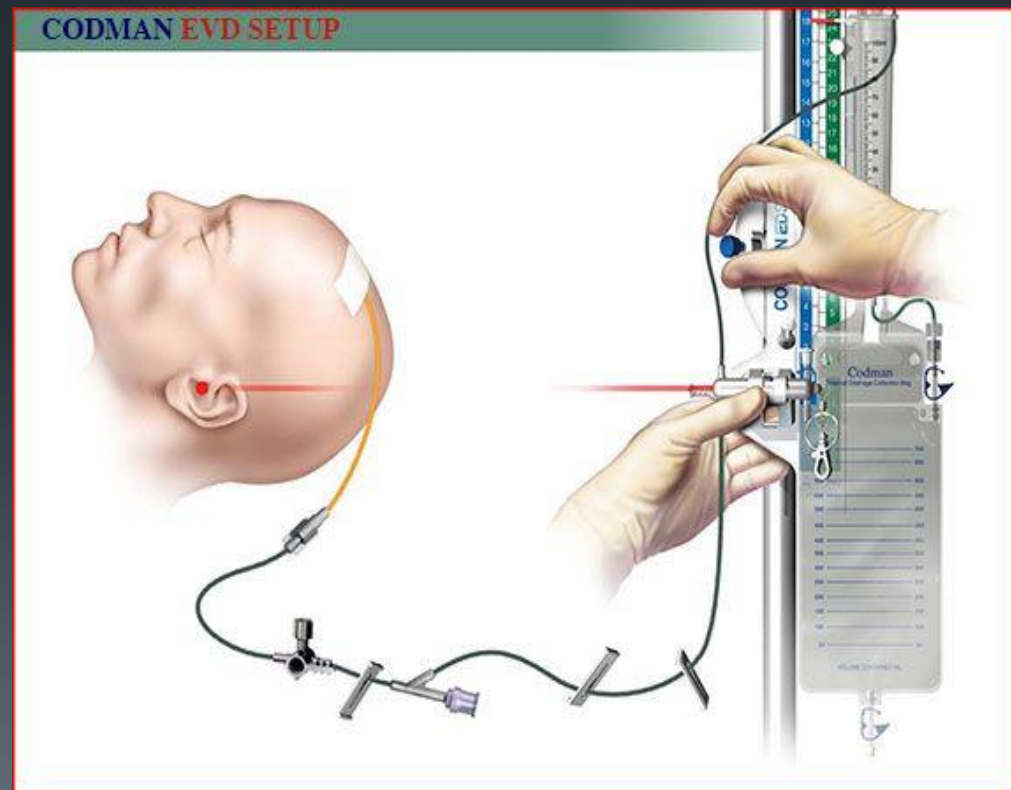
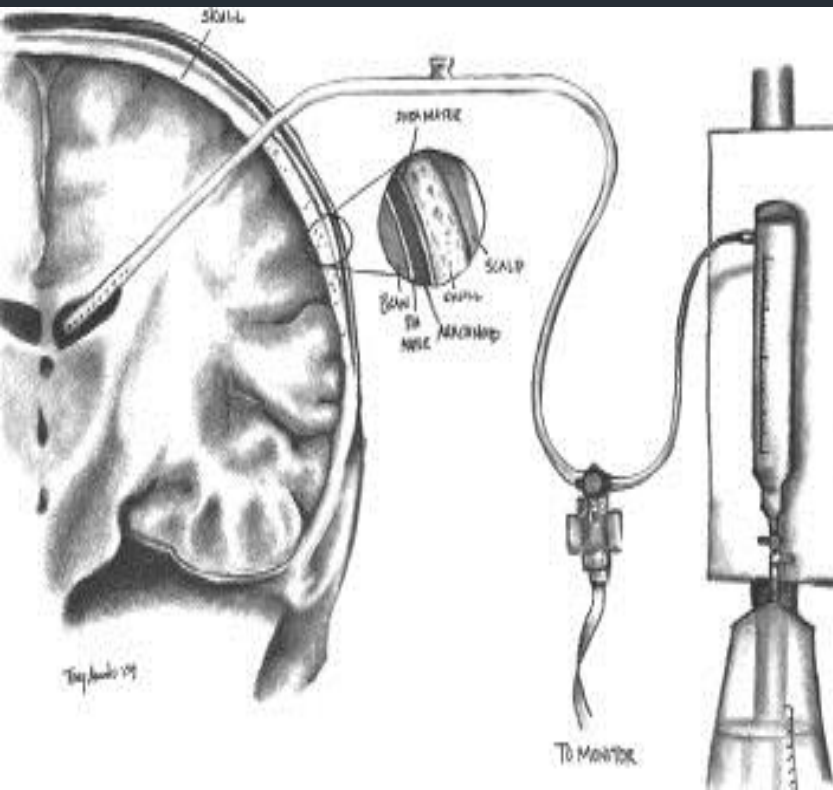


- Pneumocephaly



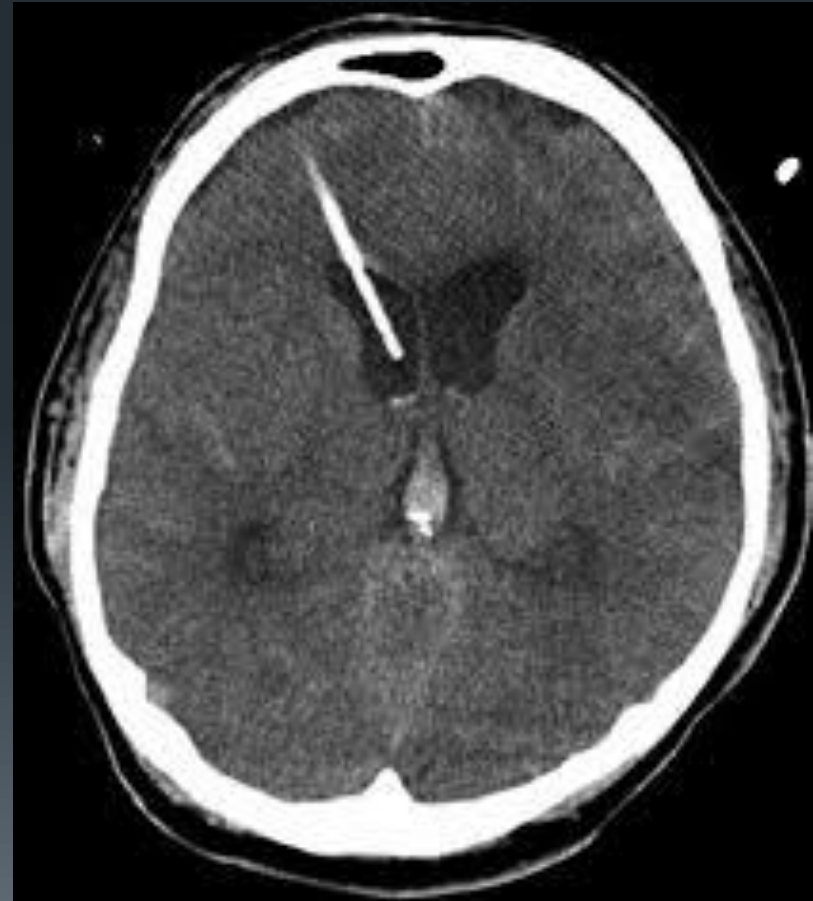Post Operation Changes in Cranial Ct Scan

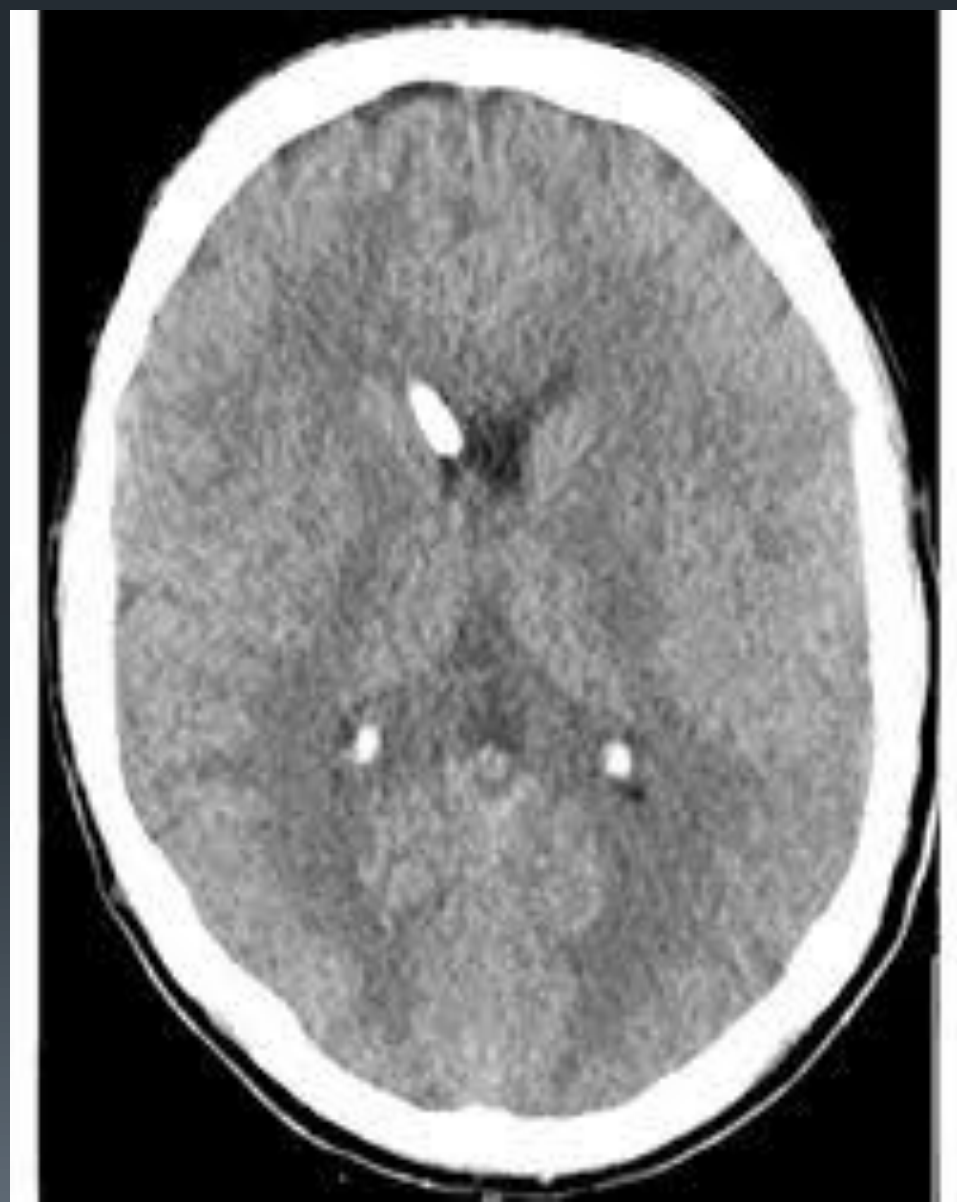- External Ventricular Drainage



Post Operation Changes in Cranial Ct Scan

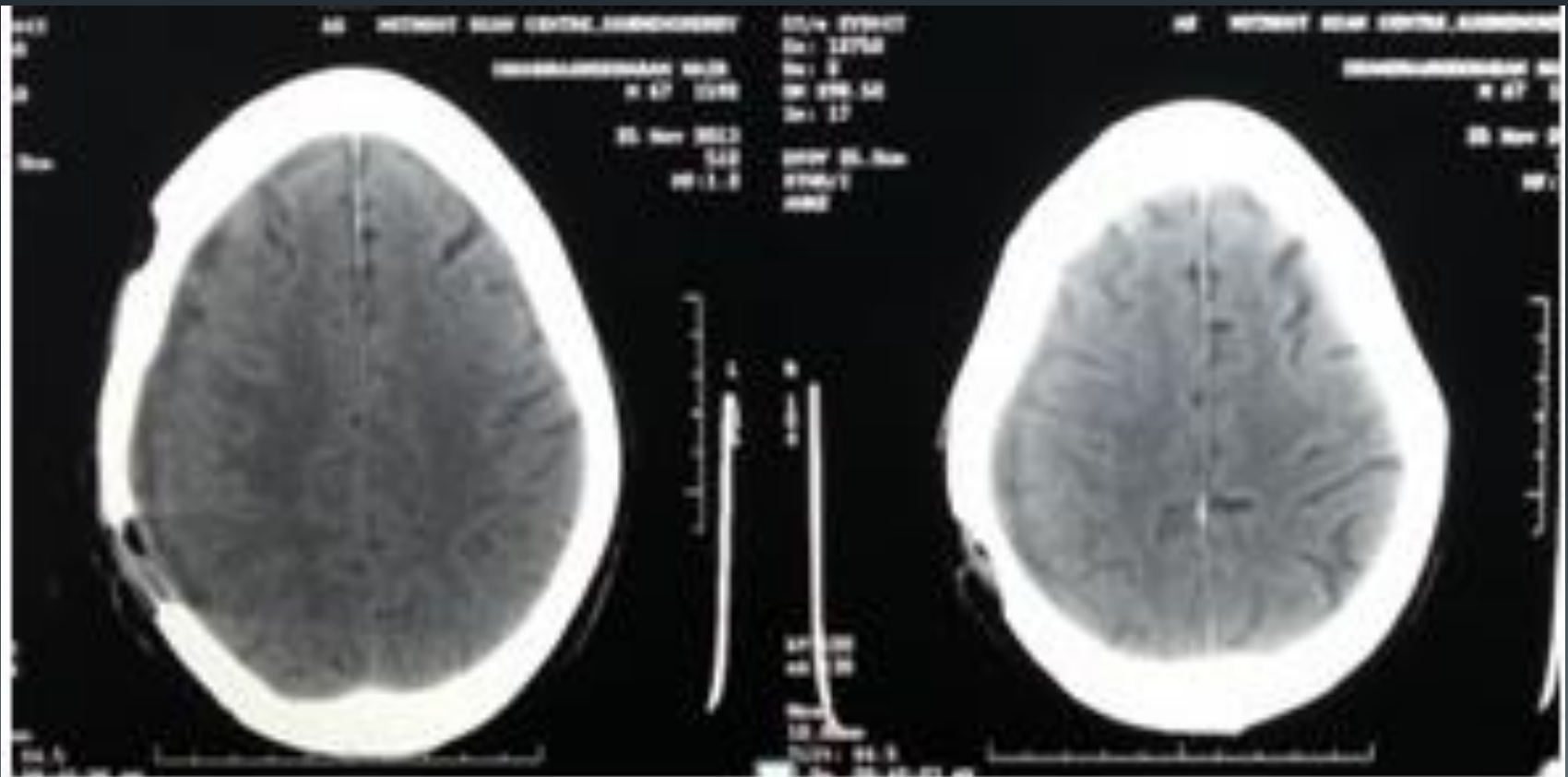
- External Ventricular Drainage





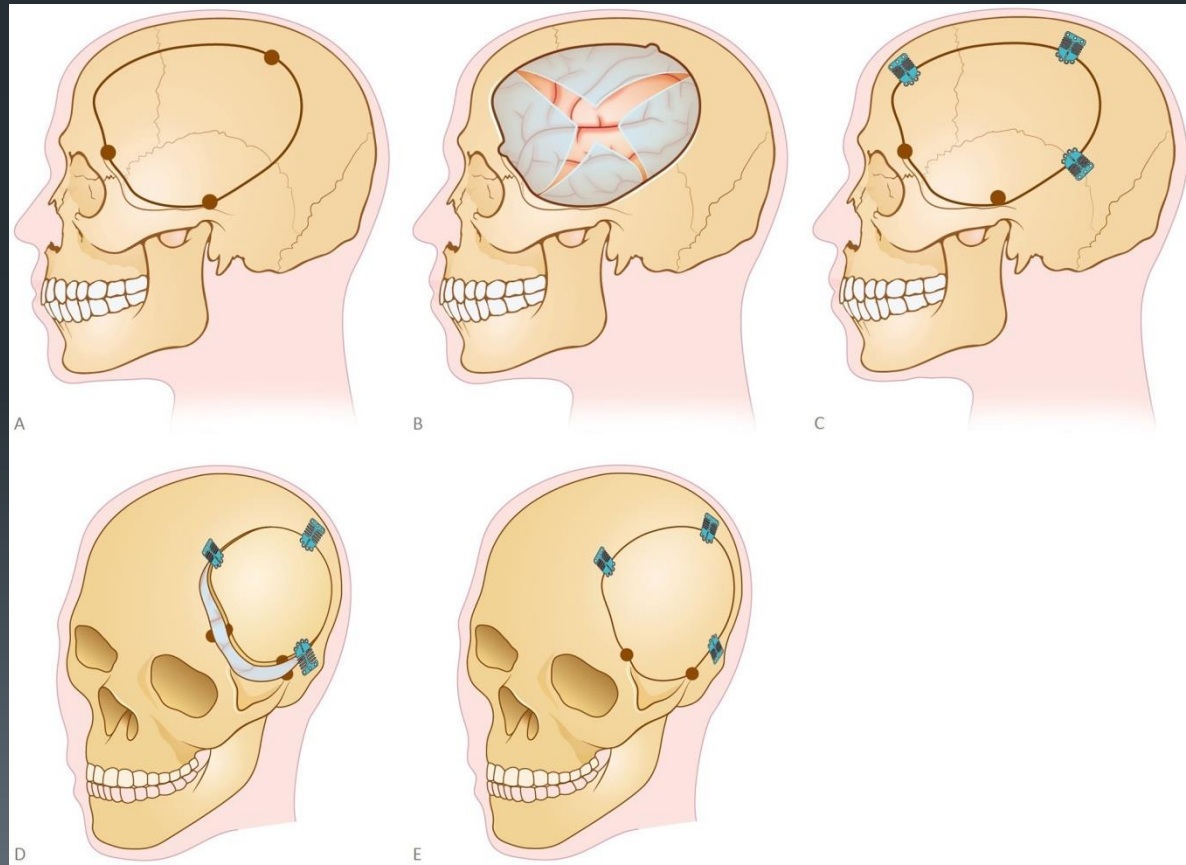
Post Operation Changes in Cranial Ct Scan

- Burr Hole Craniostomy

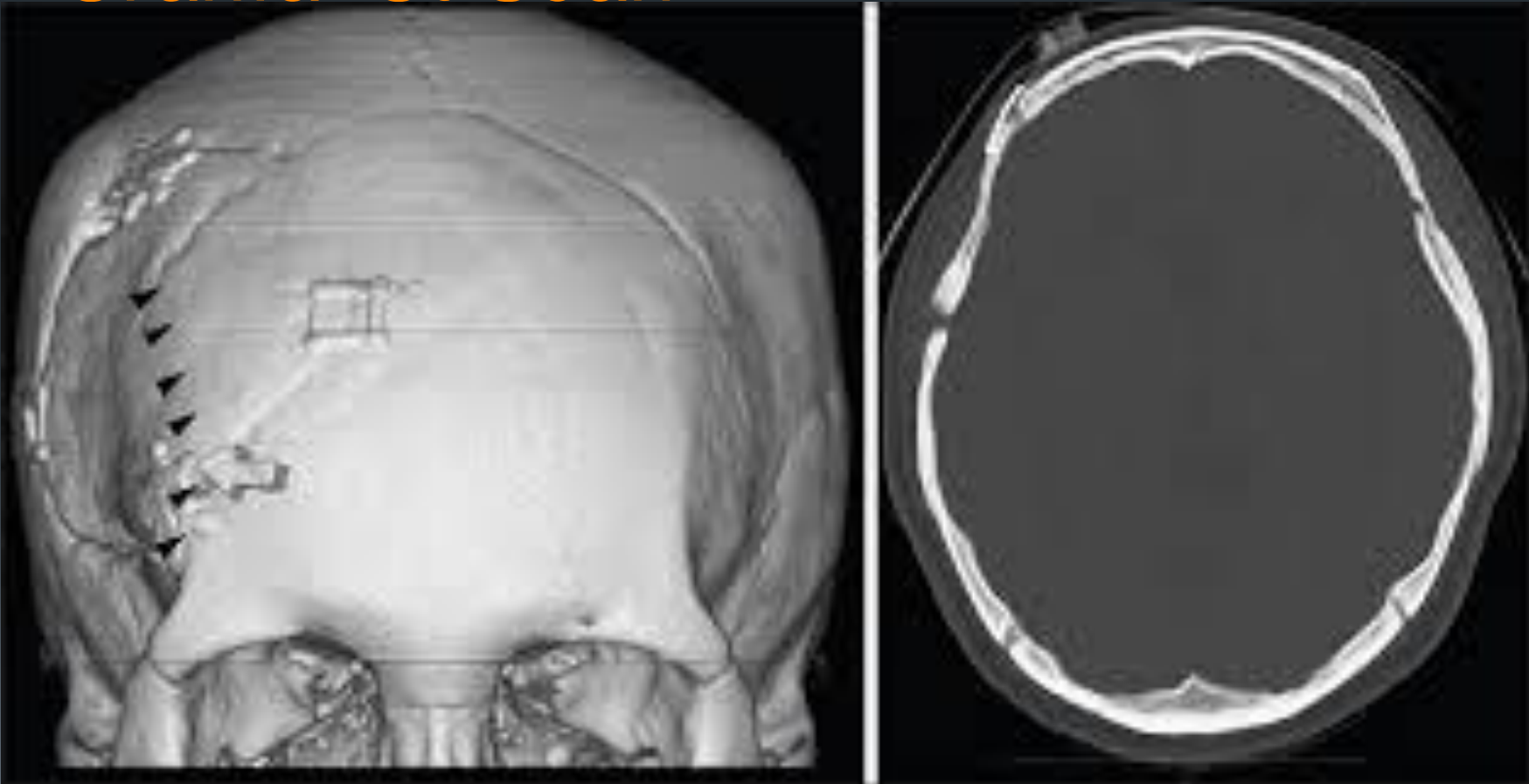

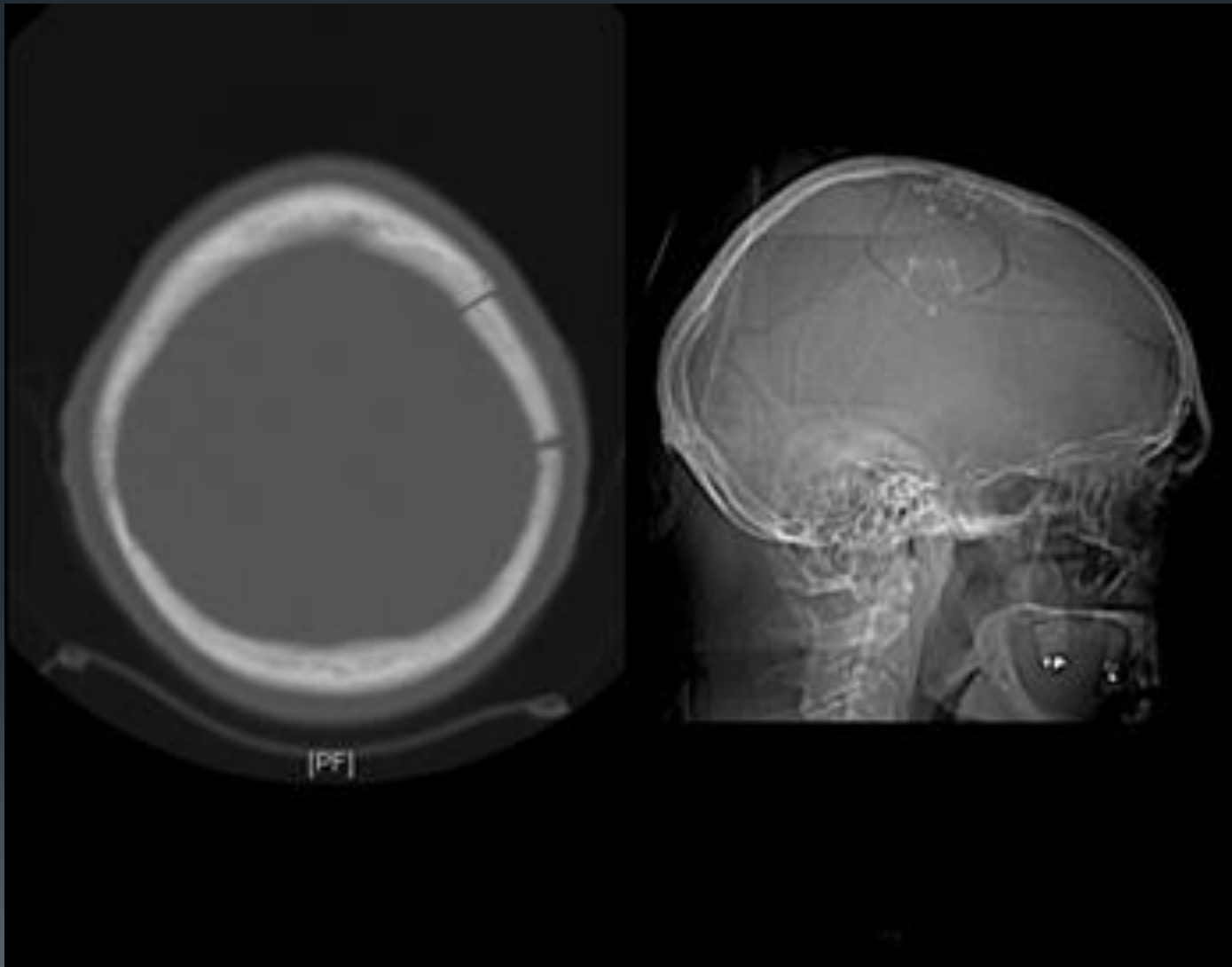Post Operation Changes in Cranial Ct Scan

- Craniotomy & Cranioplasty



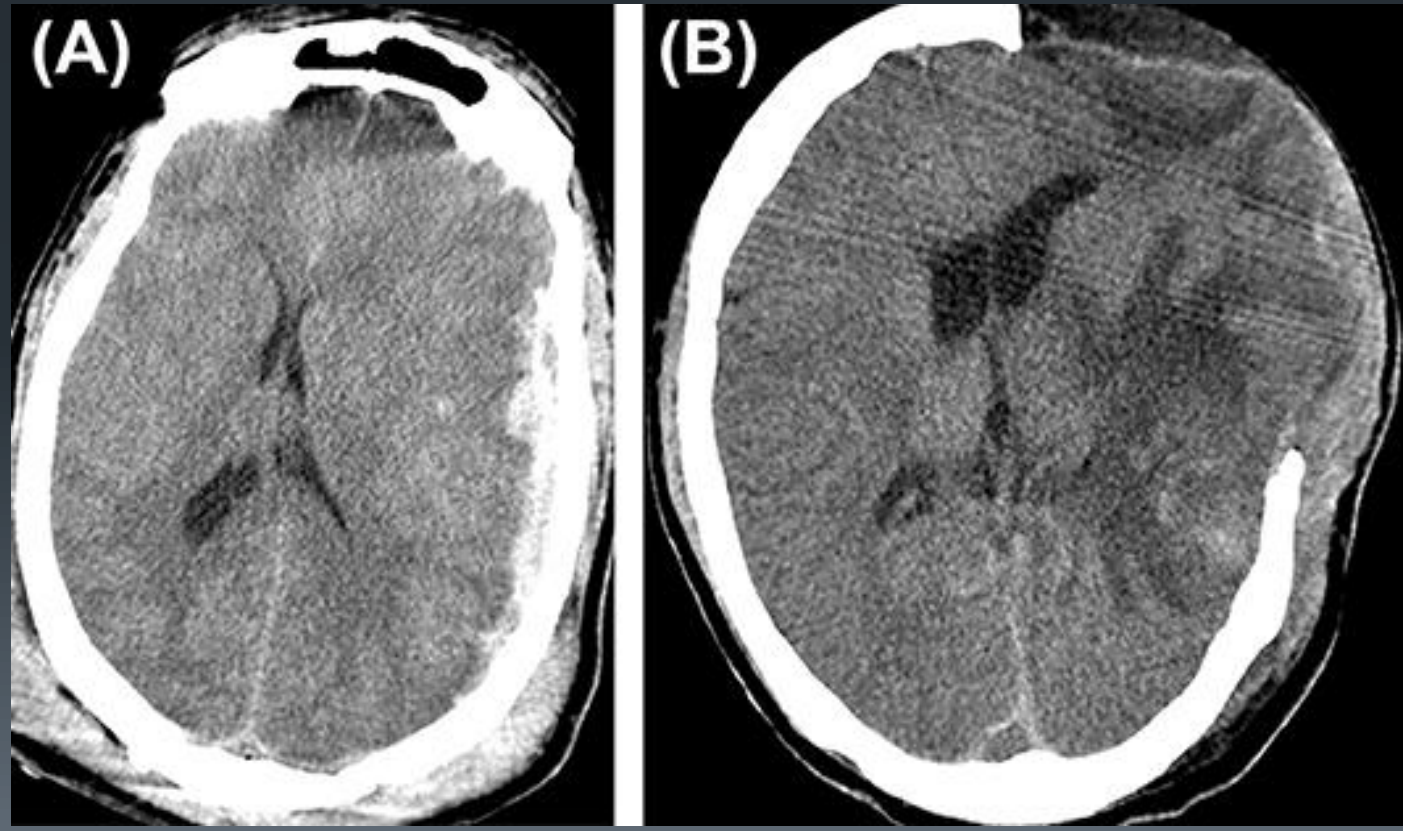
Post Operation Changes in Cranial Ct Scan

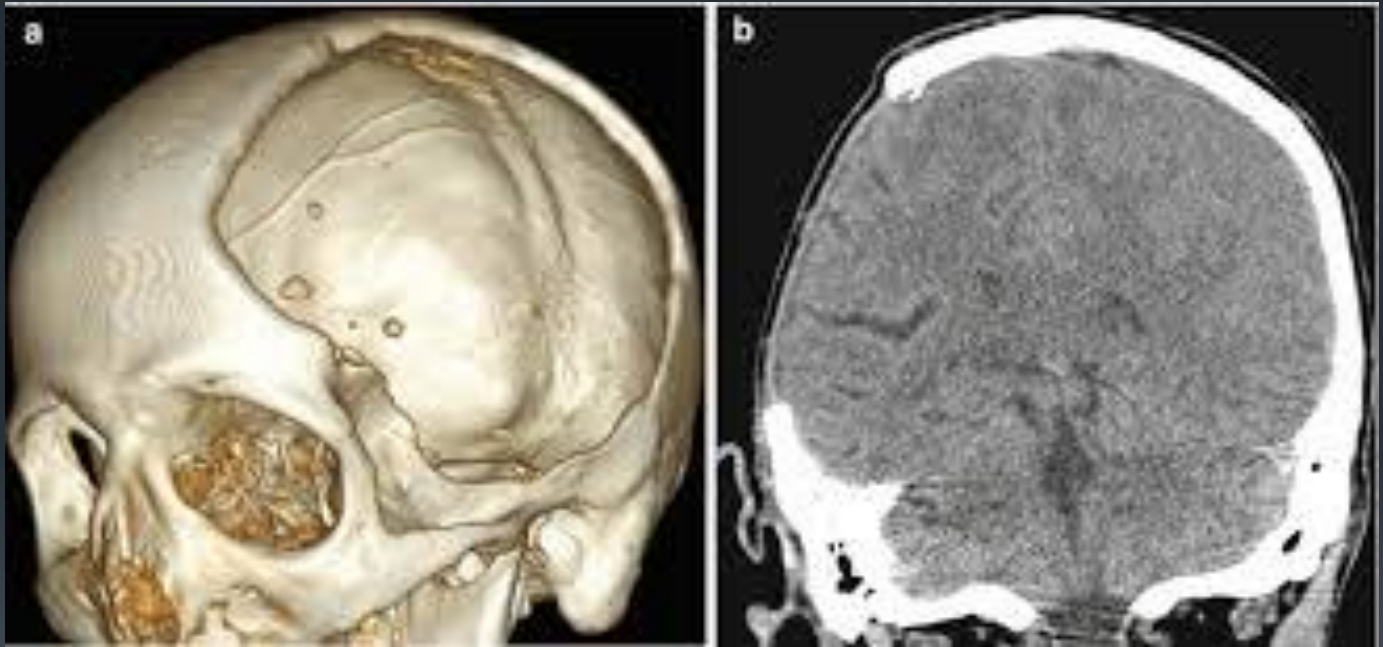




Post Operation Changes in Cranial Ct Scan

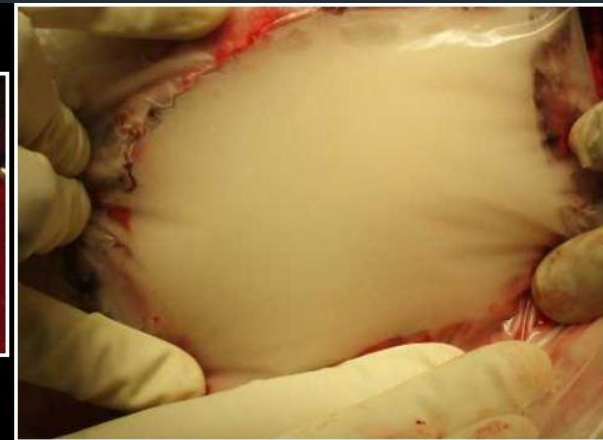

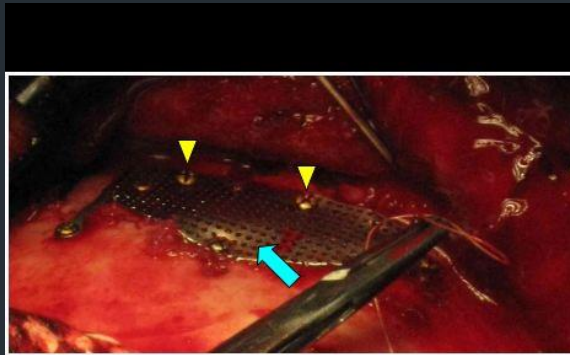
- Craniectomy





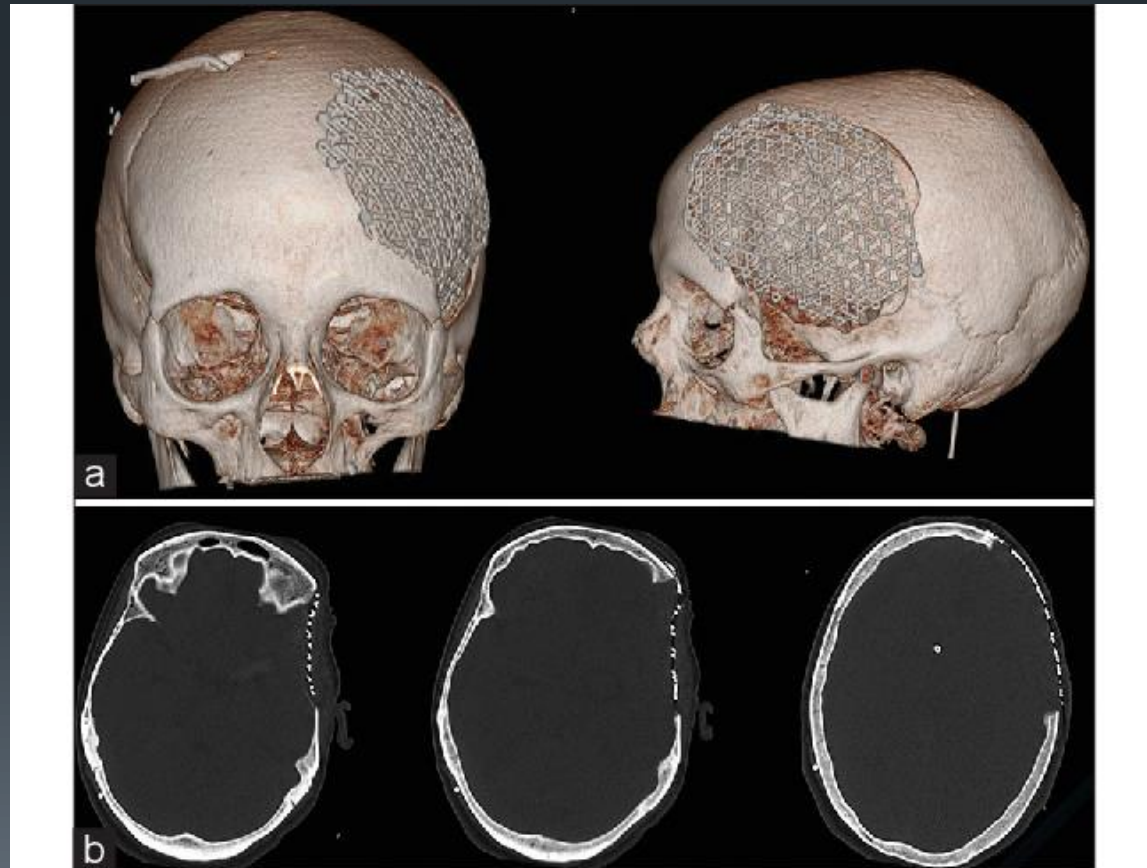
Post Operation Changes in Cranial Ct Scan

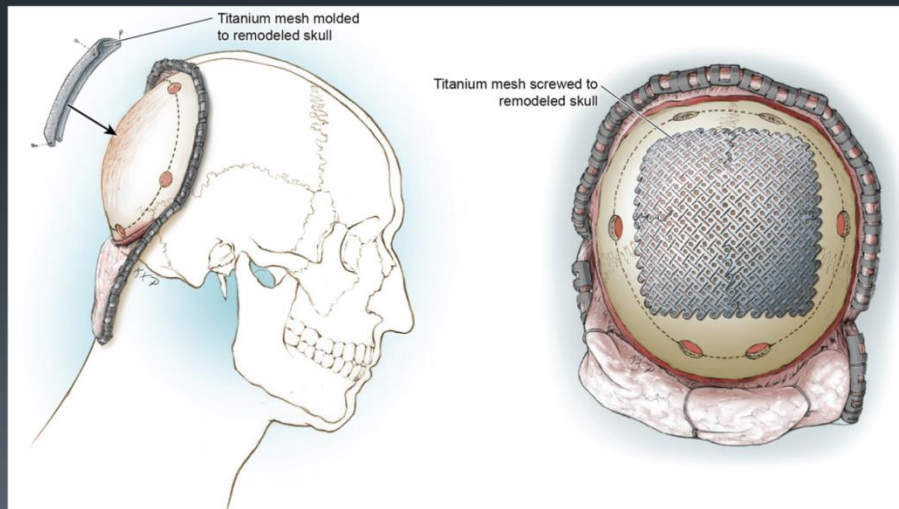
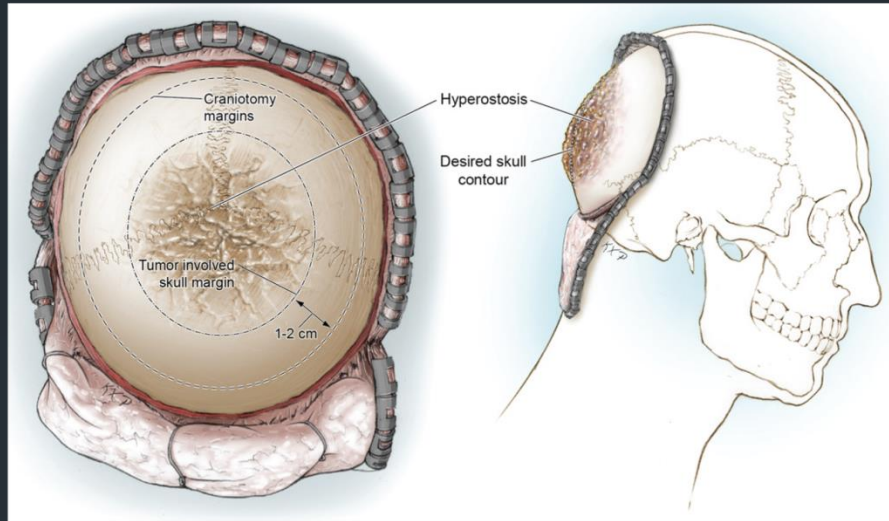
- Cranioplasty

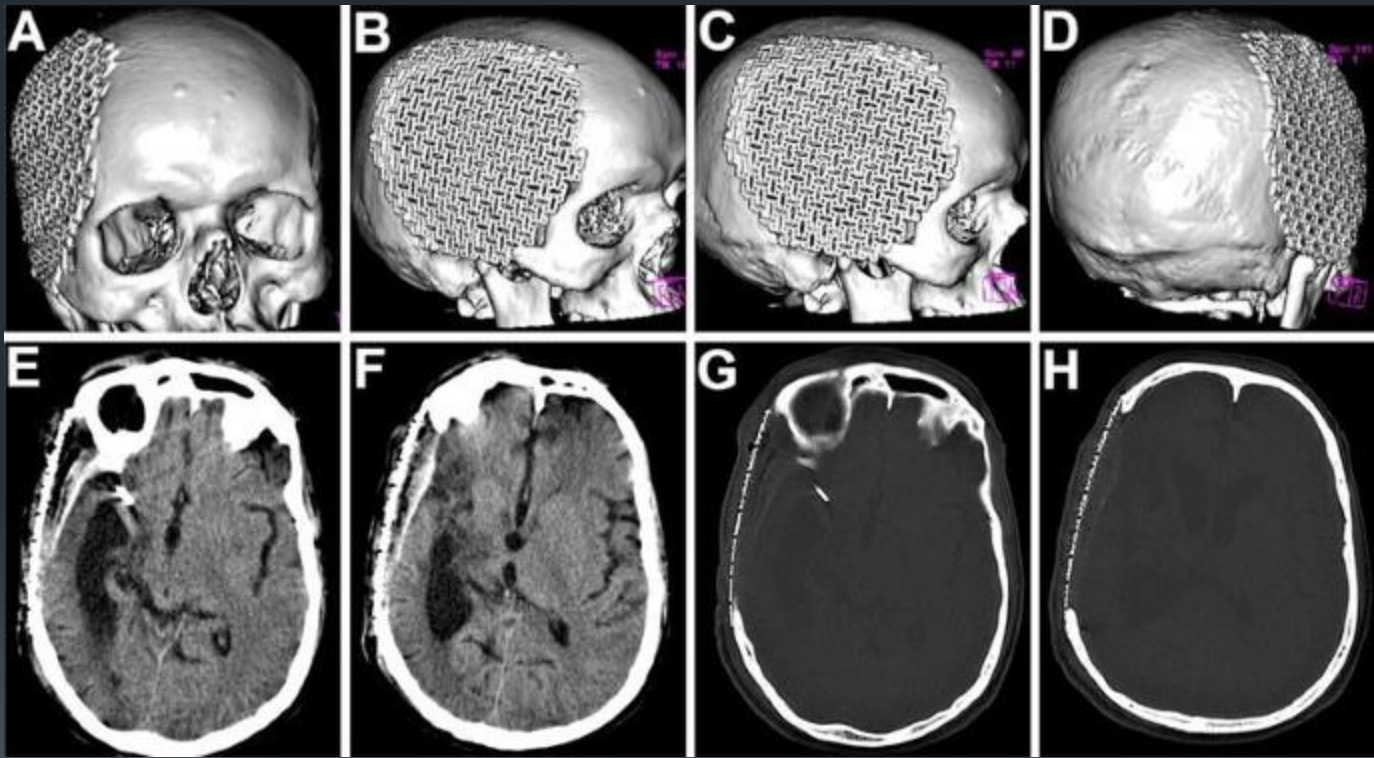


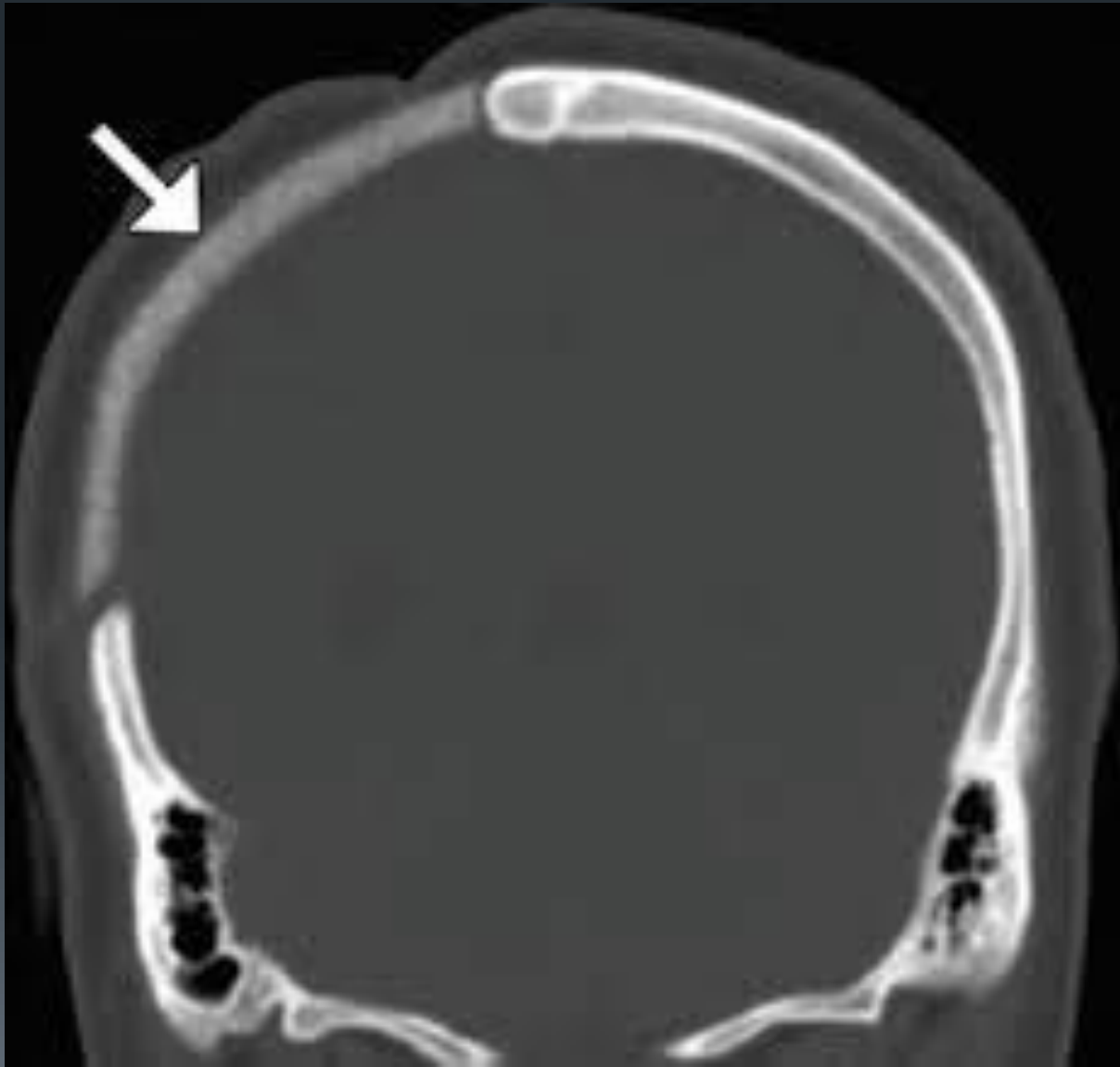Post Operation Changes in Cranial Ct Scan

- Cranioplasty



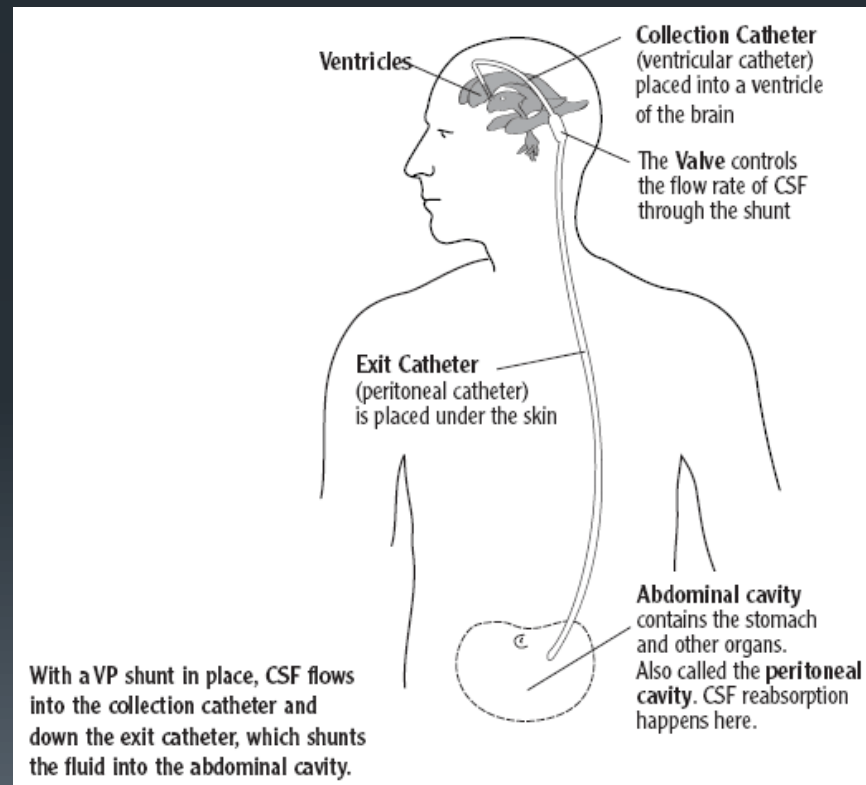


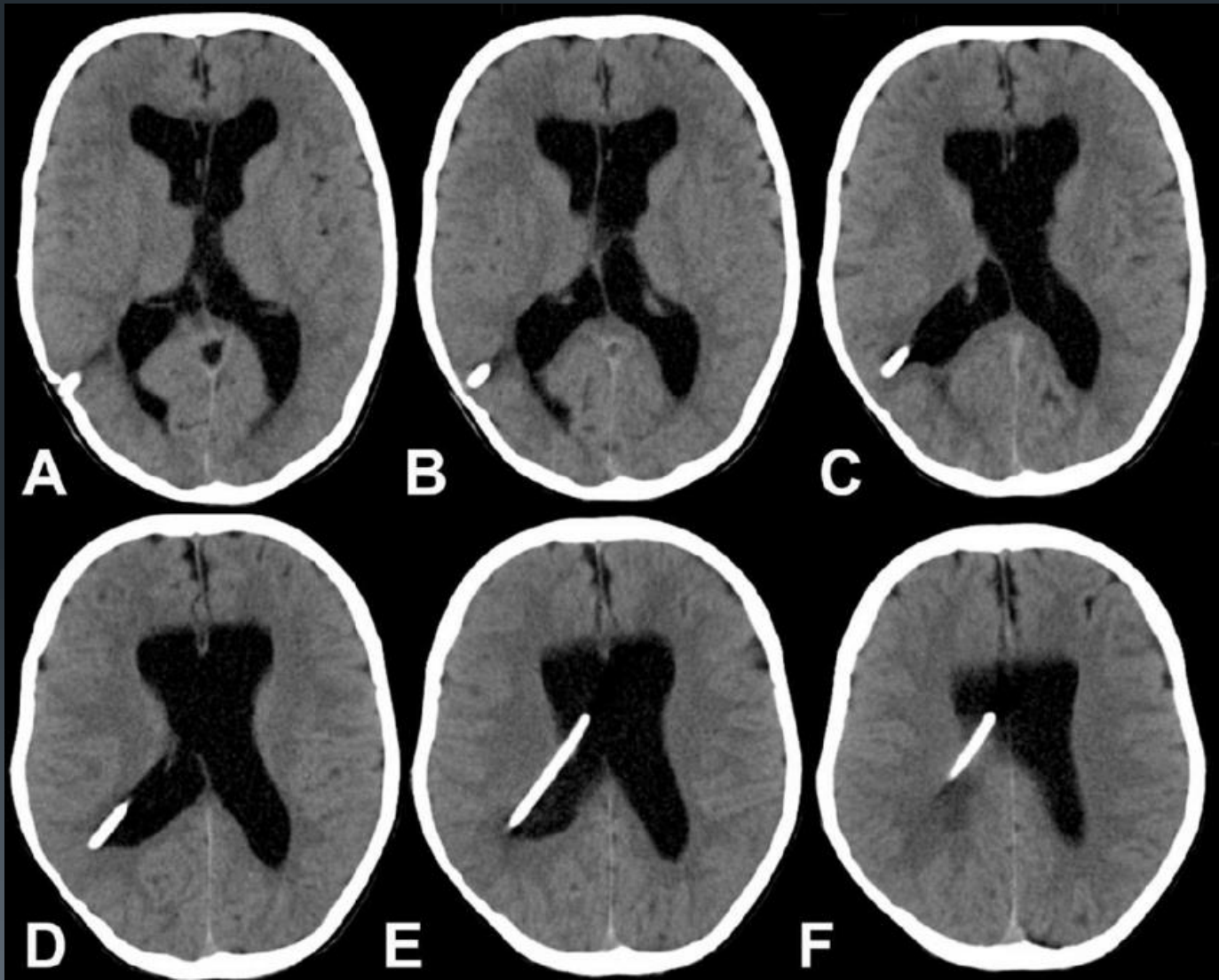




Post Operation Changes in Cranial Ct Scan

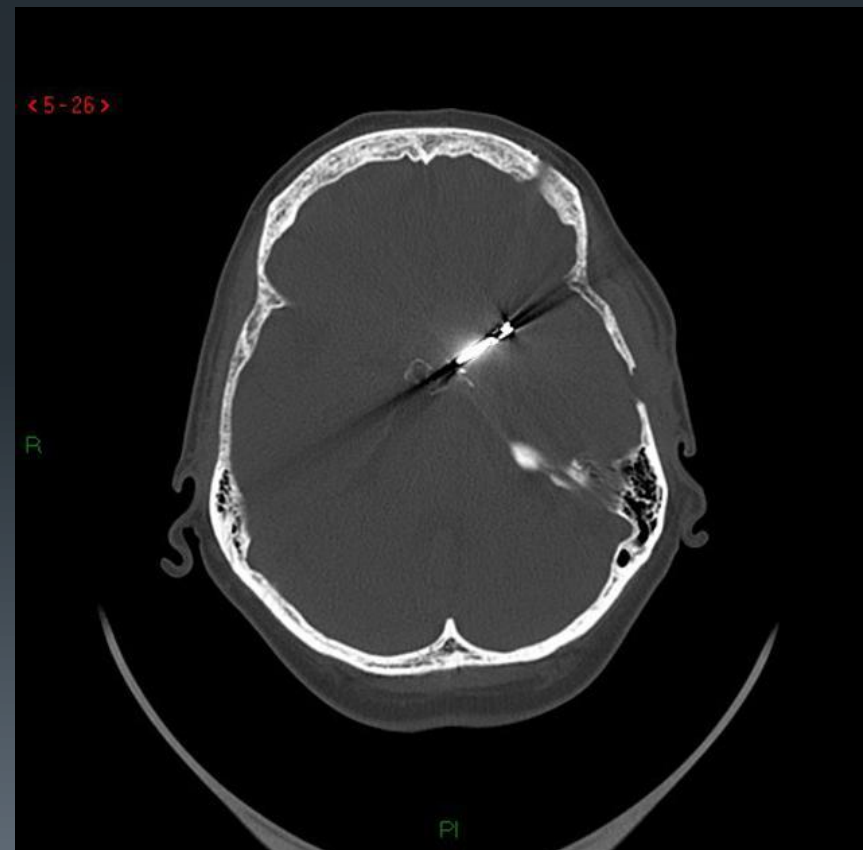
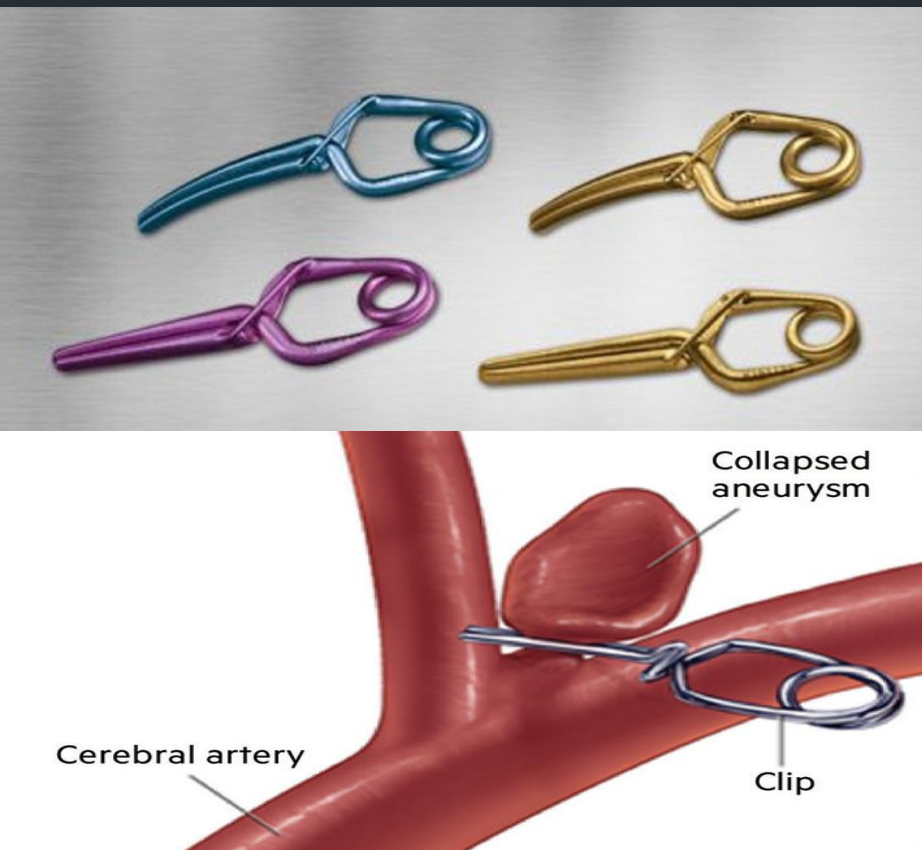
- Ventriculoperitoneal Shunting





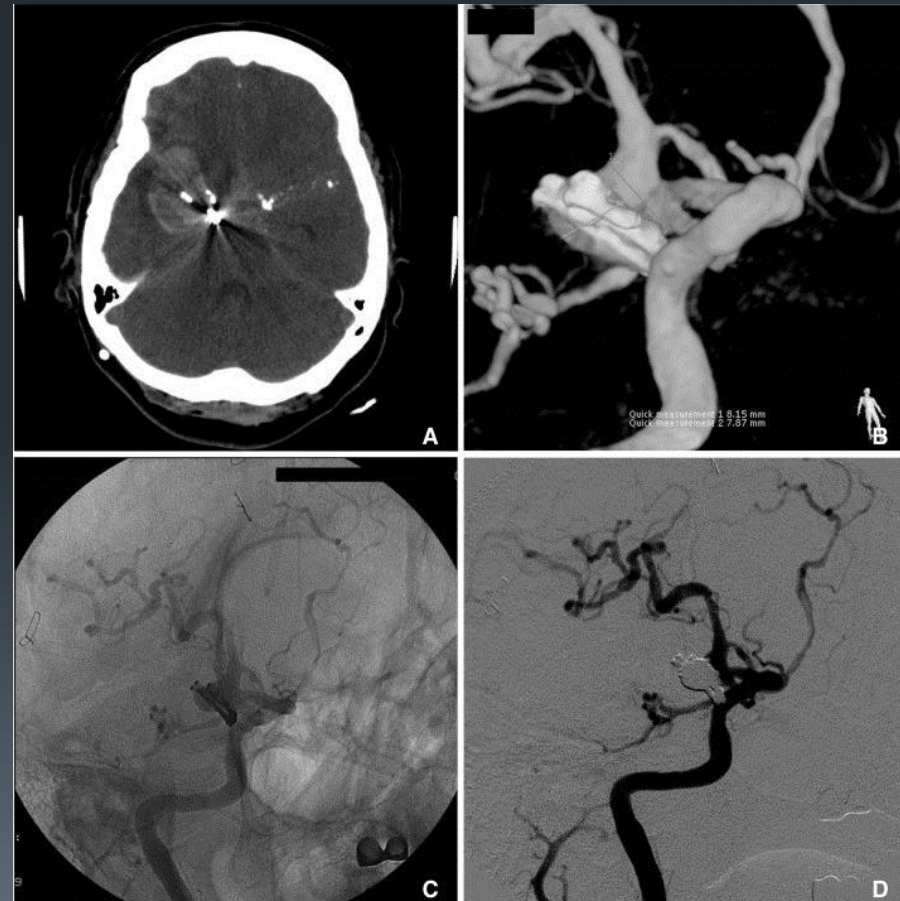
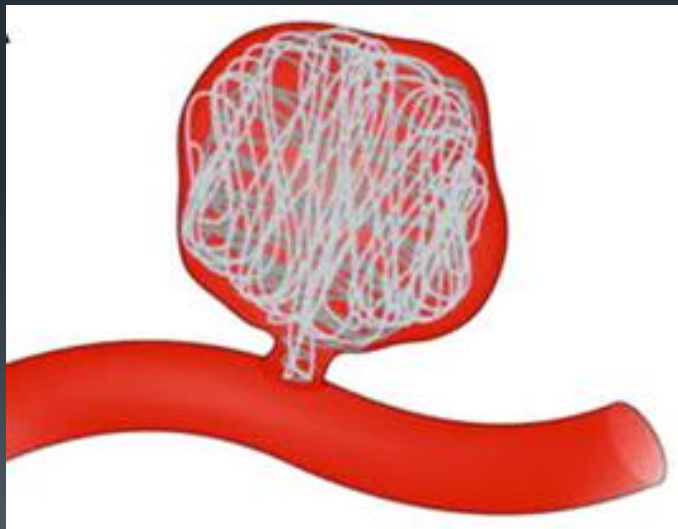
Post Operation Changes in Cranial Ct Scan

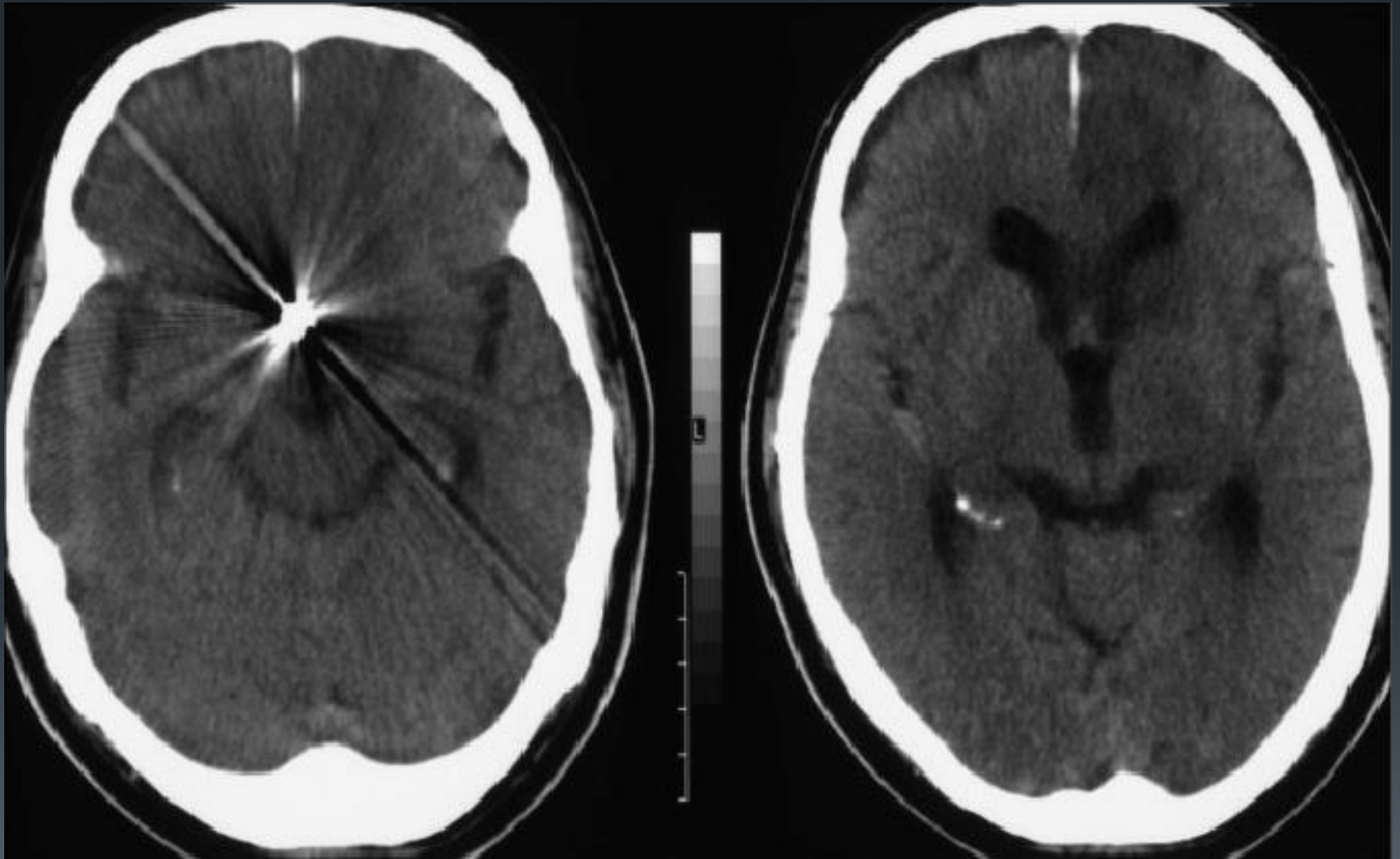- Aneurysm Clipping



Post Operation Changes in Cranial Ct Scan

Endovascular Interventions

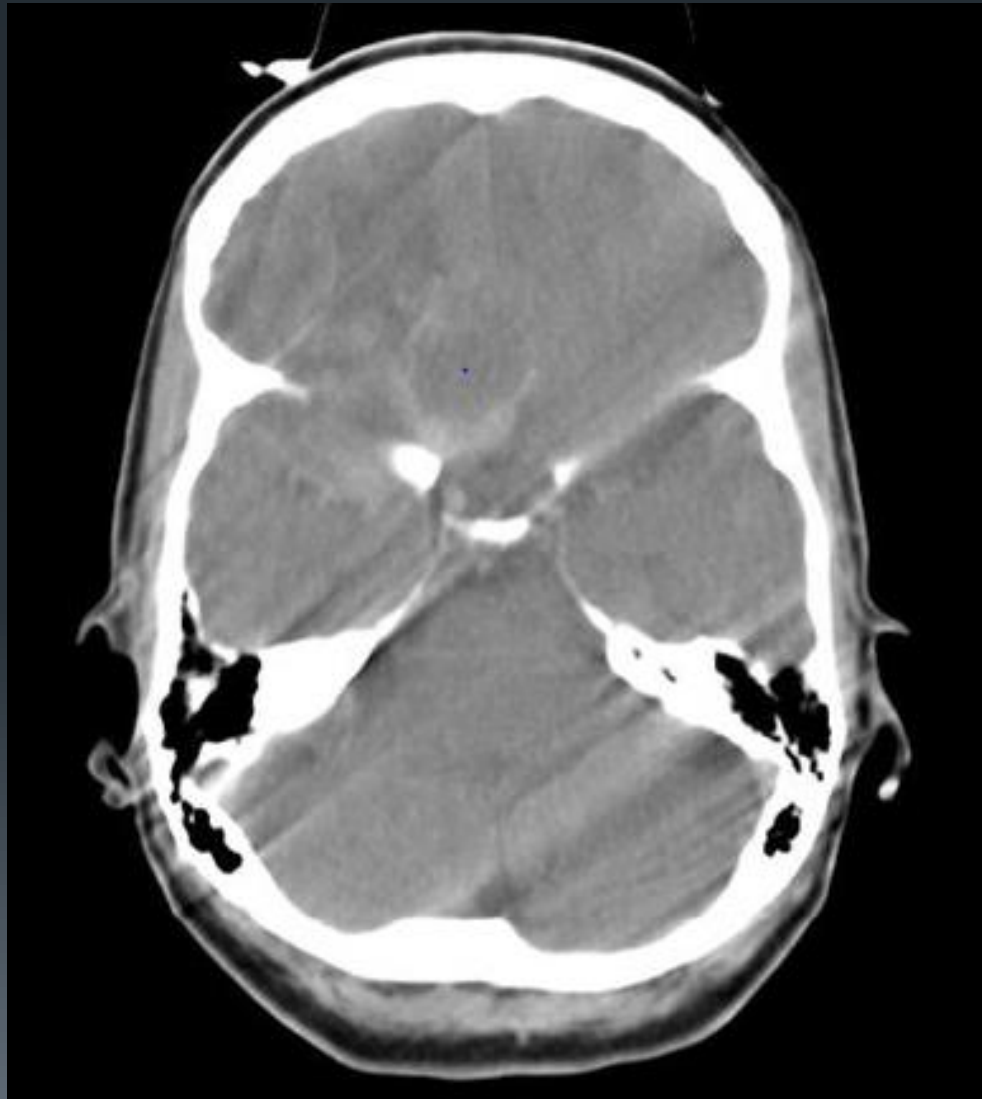




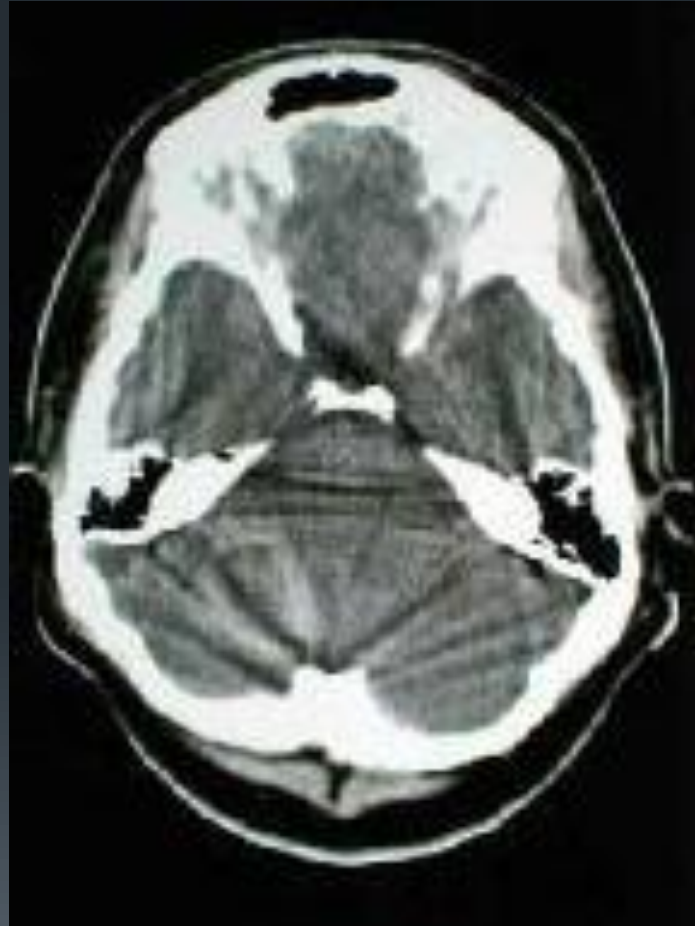
Artifacts

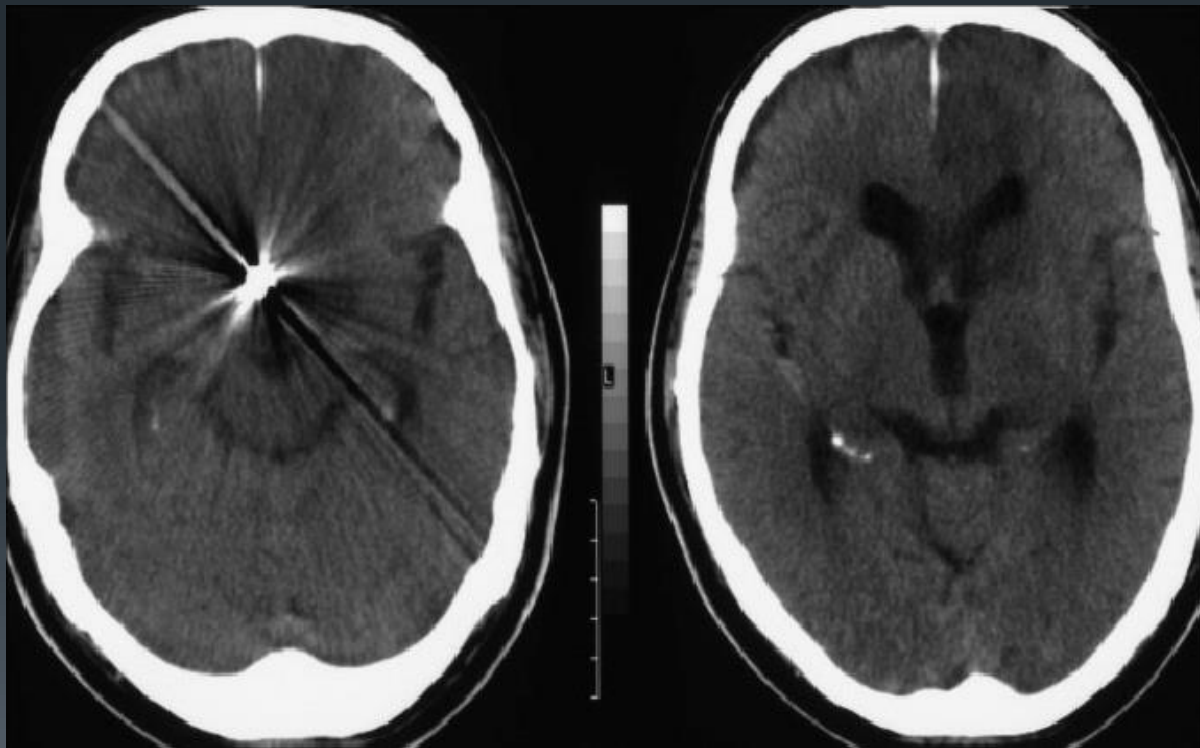
Motion Artifacts



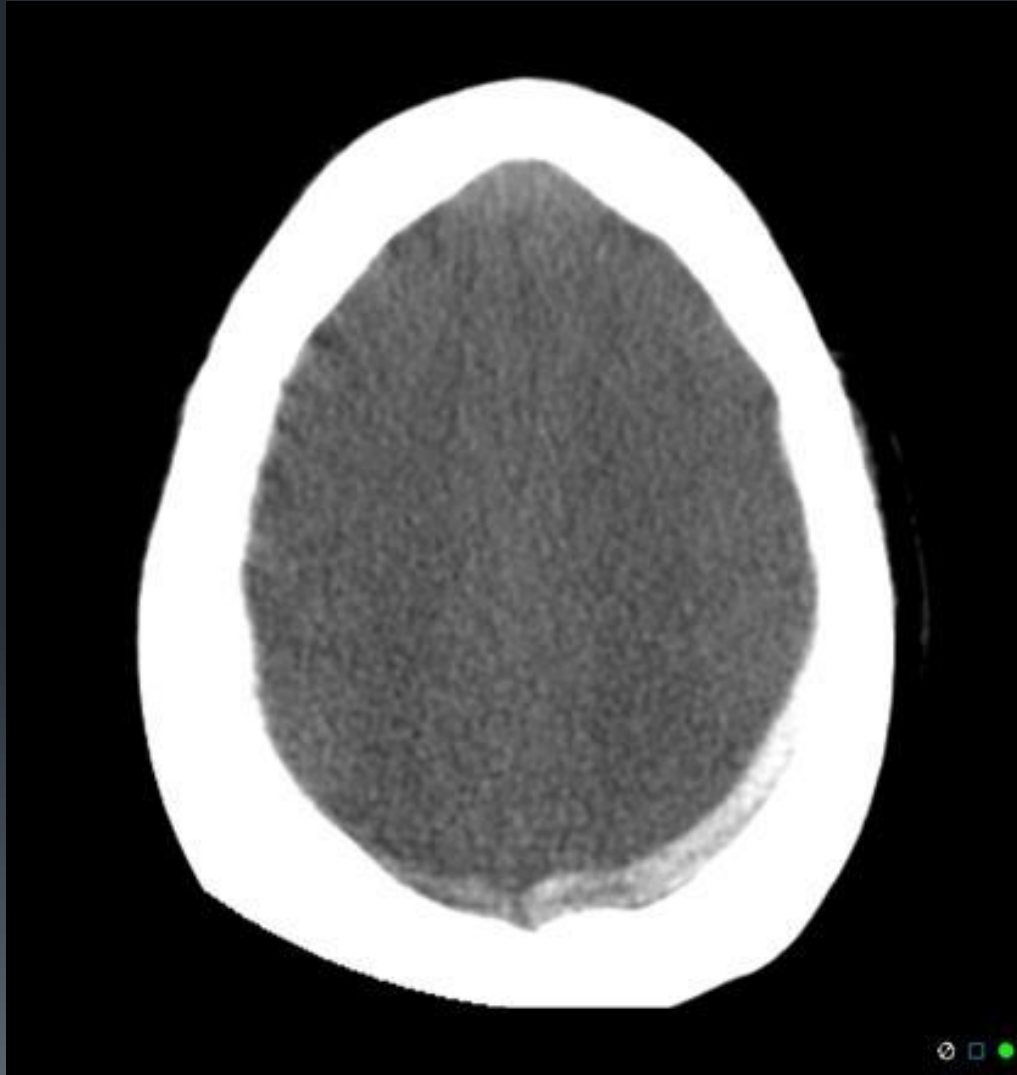
Beam Hardening Artifacts



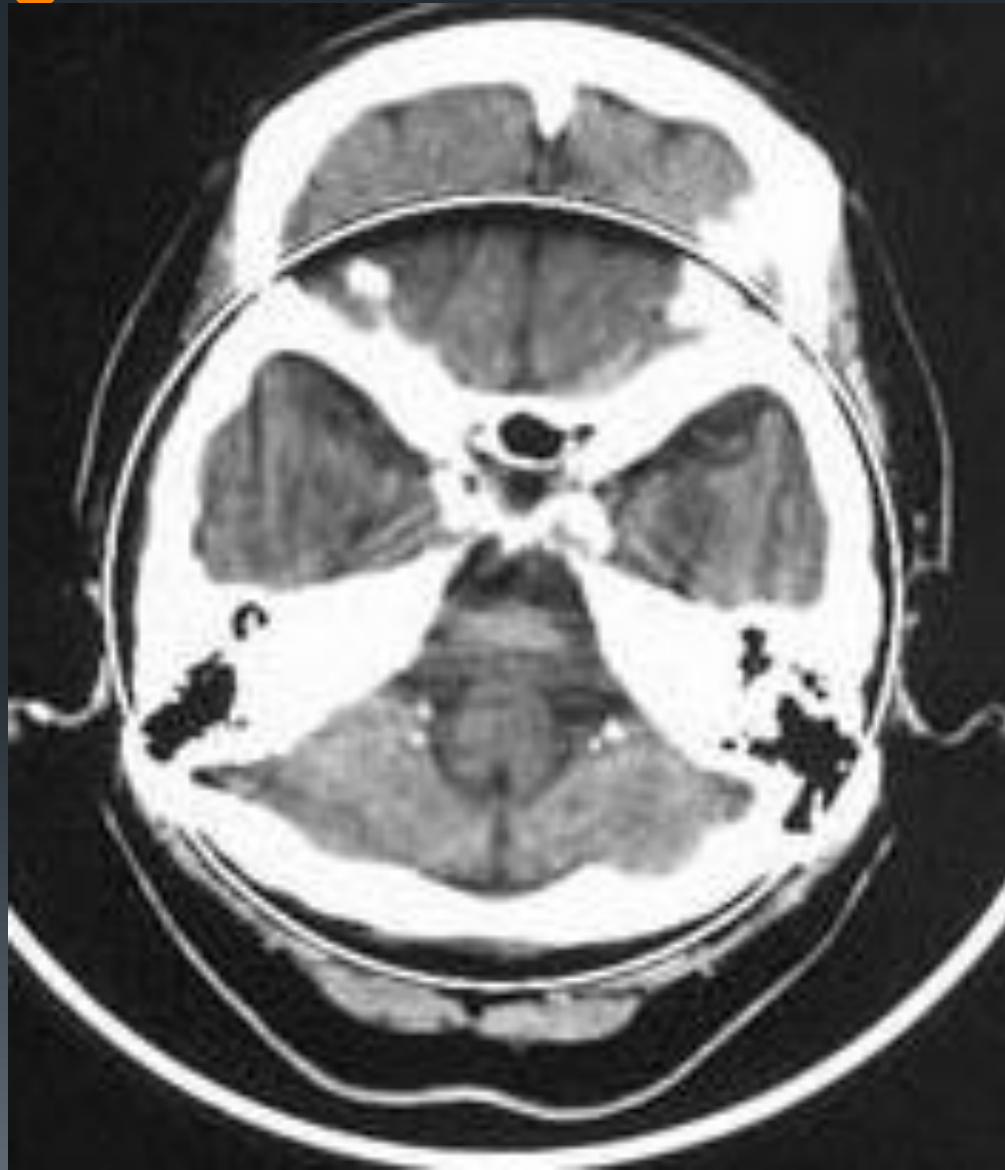
Metal Artifacts



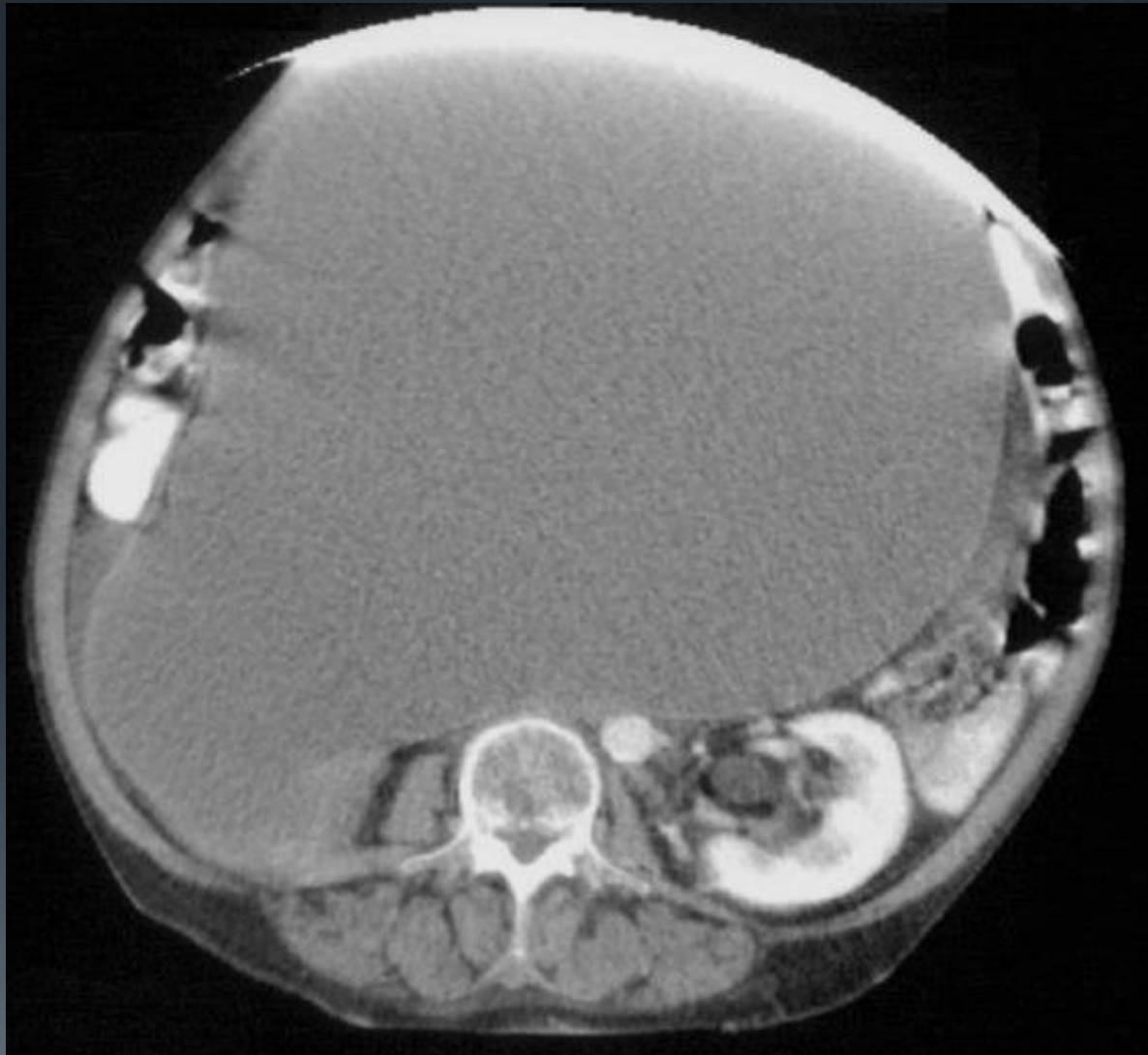Partial Volume Effect (volume Averaging) Artifacts



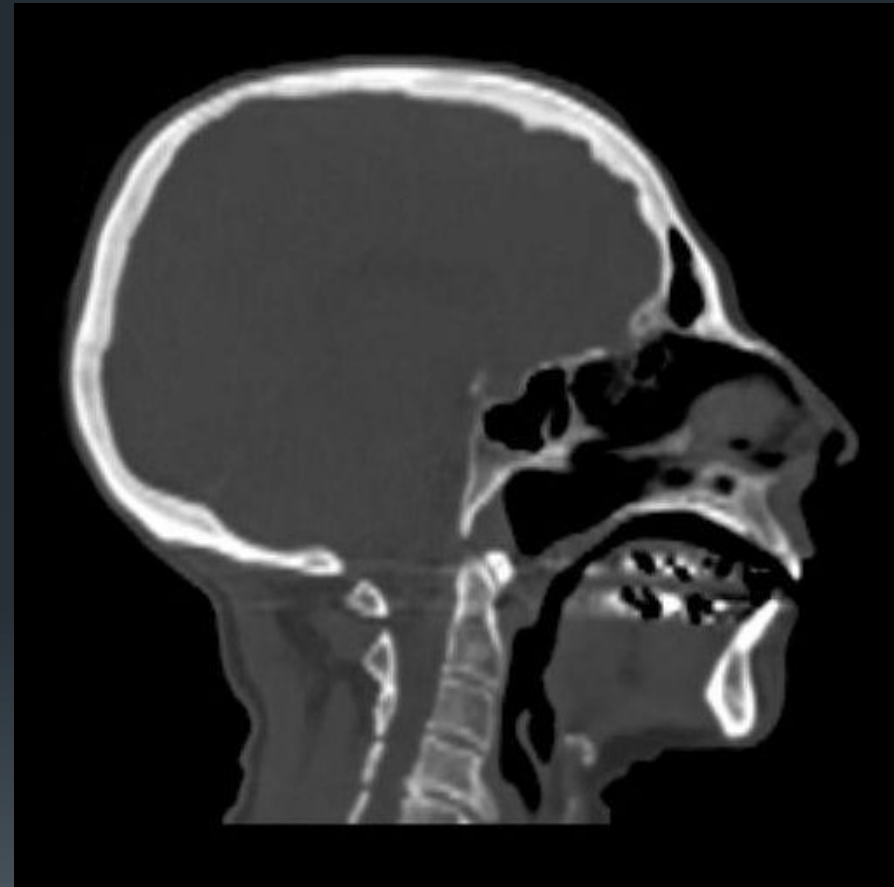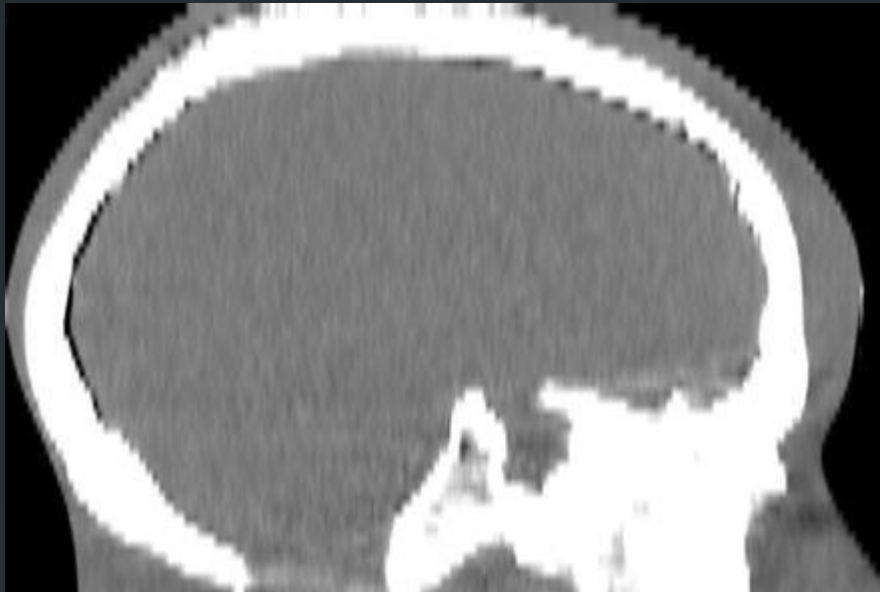
Ring Artifacts



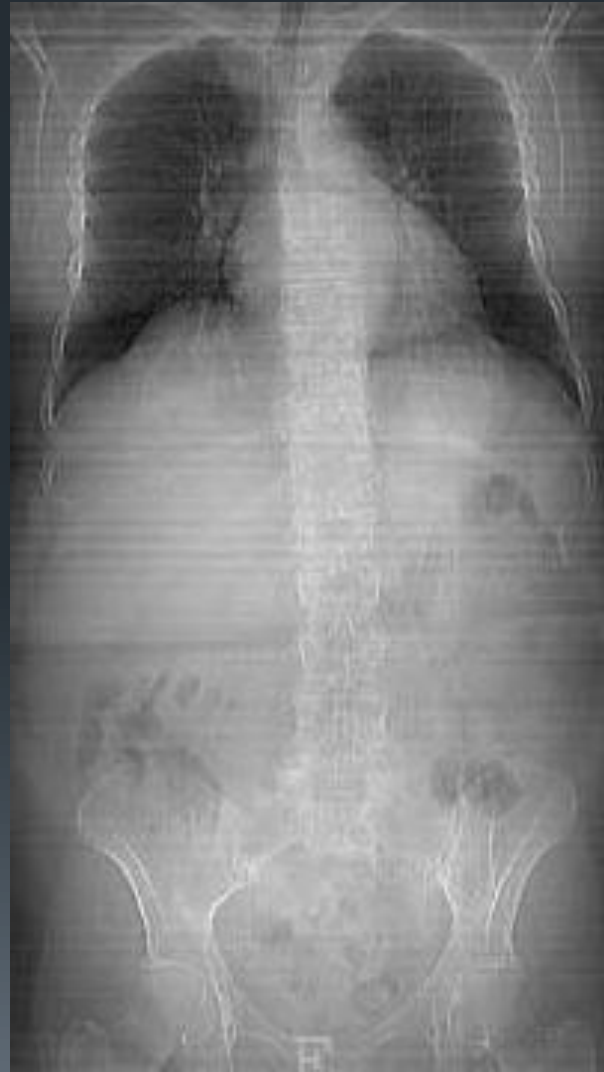Out of Field Artifacts



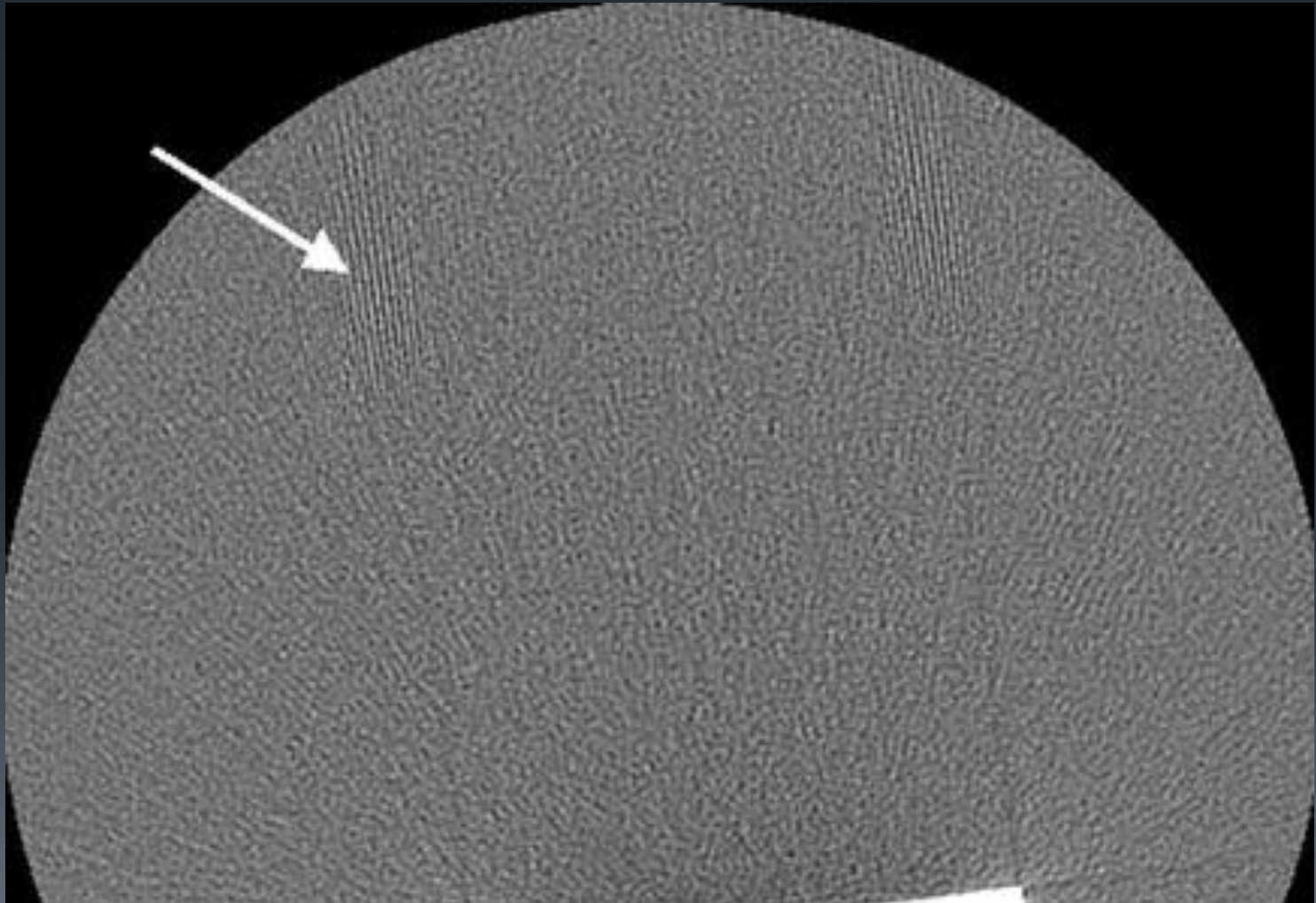
Staircase Artifacts



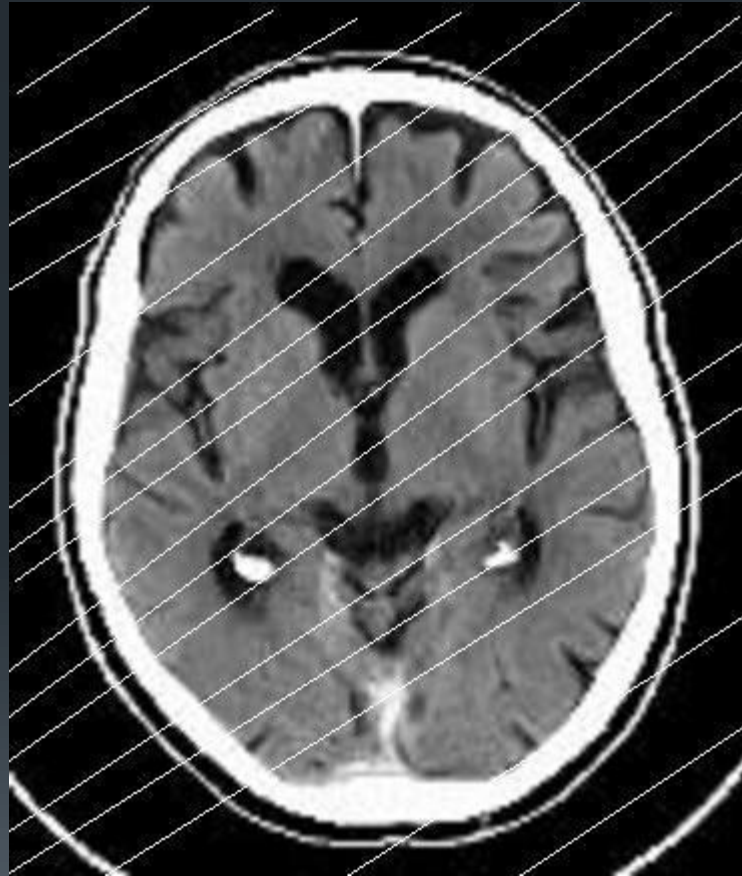
Line Artifacts



Aliasing Artifacts



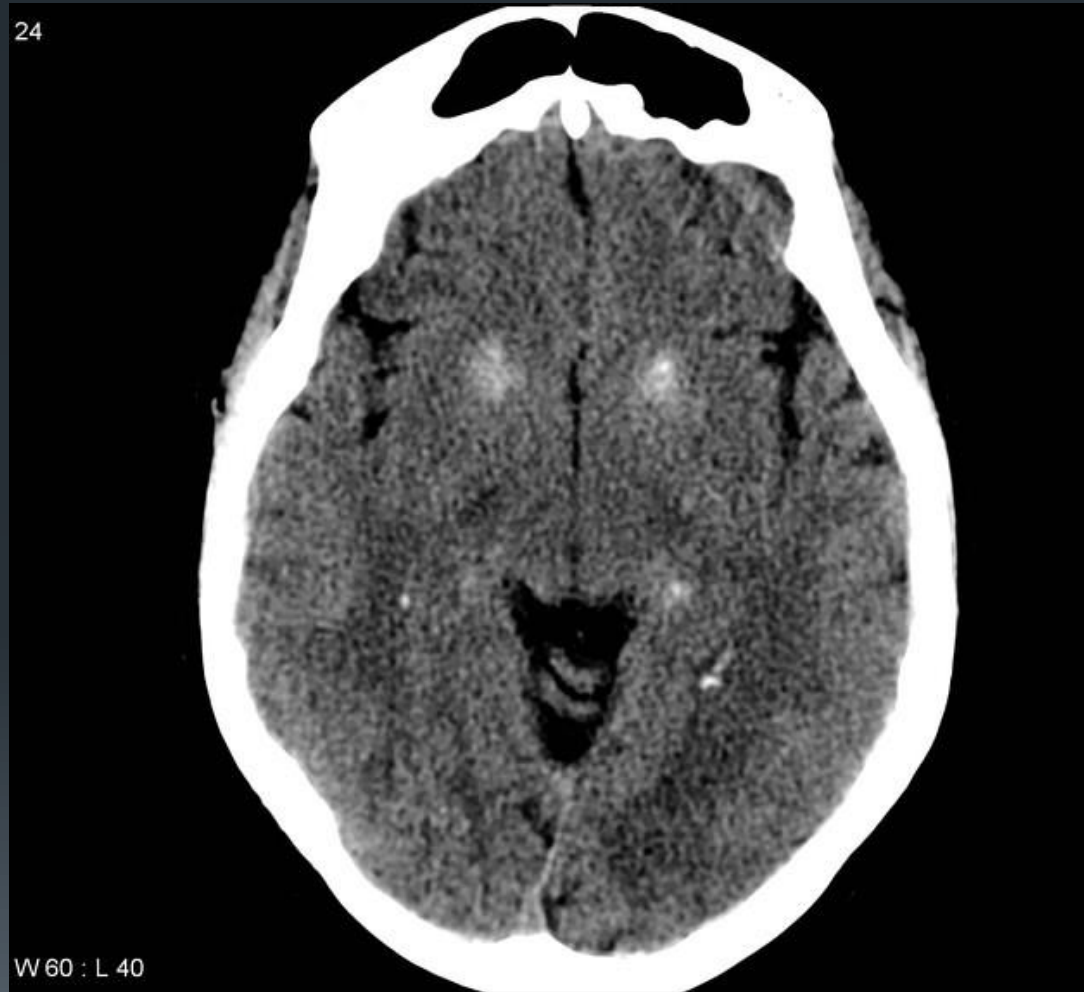Tube Arcing Artifacts



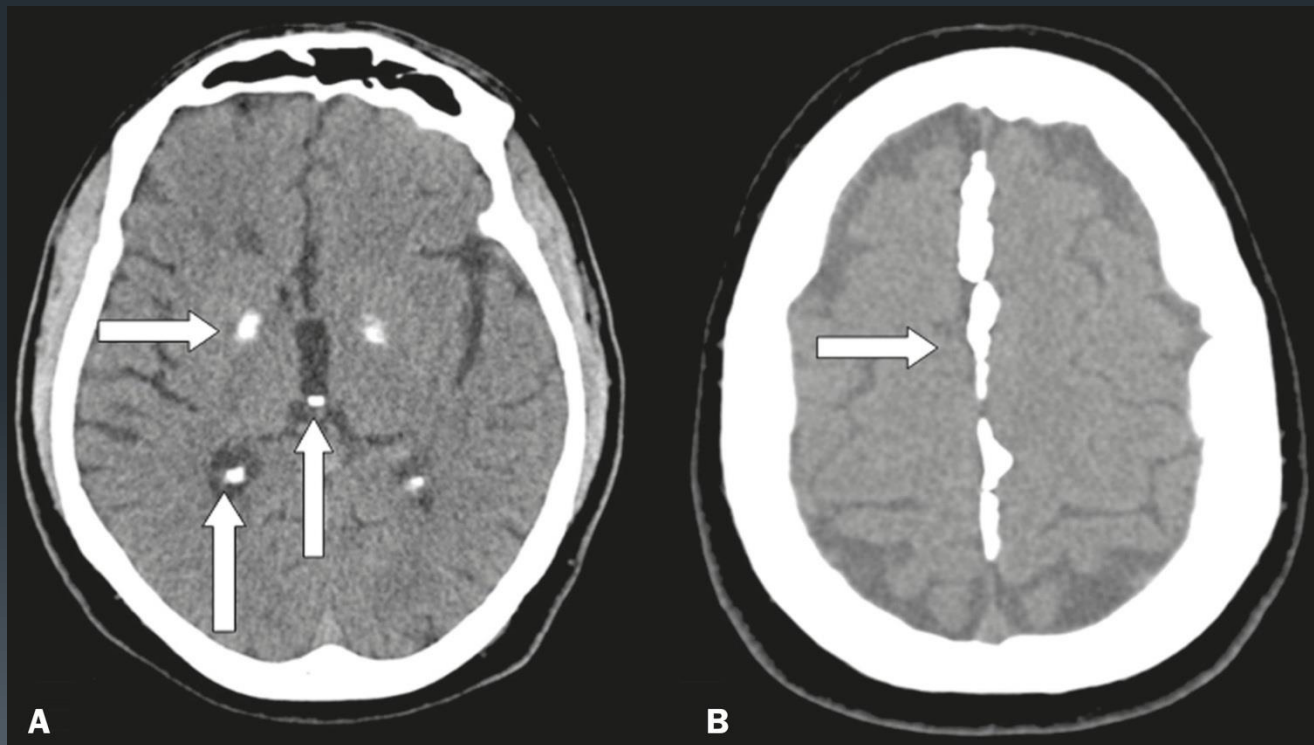
Normal Calcification



Normal Calcification

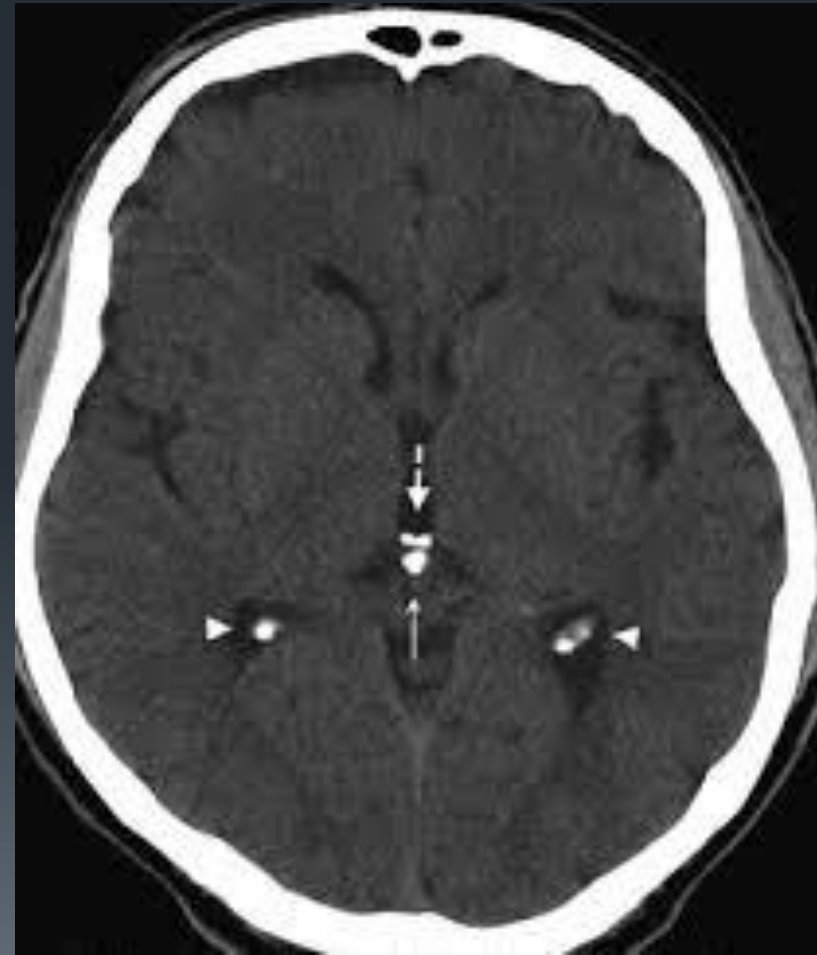

Normal Calcification

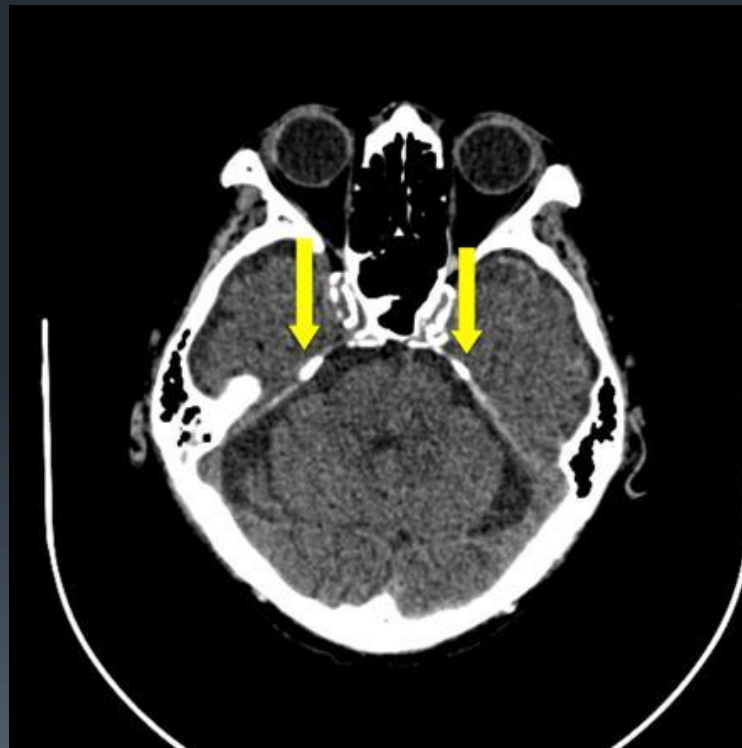

Normal Calcification

- Habenular Commissure
- Pineal Gland



Normal Calcification





Thanks for your attention